

Evaluation of CBNAAT over Smear Microscopy for Diagnosis of Tuberculosis in Pediatric Patients

Dr. R. Vanishree¹, Dr. Chandana Konda^{2*}, Dr. K. Swarnalatha³

¹Assistant Professor, Department of Microbiology, Niloufer Hospital, Hyderabad, Telangana, India

²Senior Resident, Department of Microbiology, Niloufer Hospital, Hyderabad, Telangana, India

³Professor, Department of Microbiology, Niloufer Hospital, Hyderabad, Telangana, India

Original Research Article

*Corresponding author

Dr. Chandana Konda

Article History

Received: 11.02.2018

Accepted: 23.02.2018

Published: 28.02.2018

DOI:

10.36347/sjams.2018.v06i02.061



Abstract: Globally, India is a home for more than 25% of global Tuberculosis (TB) burden. Tuberculosis (TB) in children is neglected as diagnosis is challenging due to insufficient specimen material, the scarcity of bacilli in specimens and lack of sensitive diagnostic tools. The sensitivity of smear microscopy and its inability to detect drug resistance limits its impact on TB control. Recently Cartridge-based nucleic acid amplification test (CBNAAT) has revolutionized the diagnostic field, but its usefulness in pediatric TB is still under reported from India. A Diagnostic Test Evaluation Study was conducted at a Tertiary Care Pediatric Hospital, Hyderabad, Telangana, India between September 2017 to February 2018. In this study, we compared the CBNAAT results for diagnosis of Pulmonary and Extrapulmonary tuberculosis in pediatric patients with smear microscopy. A total of 1350 samples taken from pediatric cases of pulmonary and extra pulmonary tuberculosis patients were subjected to Ziehl Neelson's staining and CBNAAT. M.tuberculosis was detected in a total of 28 cases by CBNAAT. CBNAAT in pulmonary samples was positive in 21 (1.69%) cases and in extra pulmonary samples in 7 (6.19%) cases. Smear microscopy was positive in a total of 9 cases (0.66%). In pulmonary samples it was positive in 8 (0.64%) cases and in extra pulmonary samples in 1 (0.88%) case. Confirmatory diagnosis of TB particularly in children is a medical challenge due to technical difficulties, cost and lack of adequate resources. Our study showed that CBNAAT is useful in diagnosing pediatric tuberculosis rapidly and accurately. It is significantly better than smear microscopy.

Keywords: Cartridge-based nucleic acid amplification test (CBNAAT), Pulmonary Tuberculosis, Extra pulmonary tuberculosis, Smear Microscopy, Pediatric patients.

INTRODUCTION

TB is the ninth leading cause of death worldwide and the leading cause from a single infectious agent, ranking above HIV/AIDS. Drug-resistant TB is a continuing threat [1]. India is 17th among 22 high burden countries in terms of overall TB incidence rate, but very little information is available regarding epidemiology of TB in children, its diagnosis and management [2]. While the burden of childhood TB in India is not known, regional data from the World Health Organization (WHO) indicate that sputum microscopy smear-positive TB in children (<14 years old) accounts for 0.6%–3.6% of all reported cases [3].

In most settings, diagnosis of paediatric TB is made on the basis of contact tracing, and very few attempts have been made for active case detection. This is mainly due to lack of a pathognomonic clinical presentation in pediatric TB and lack of sensitive diagnostic tools. Therefore, evaluation of medical history, tuberculin skin testing, chest x-ray and a lack of

response to antibiotics help in making the clinical diagnosis [2]. Sampling is particularly difficult in children under 10 years-old, and even if samples are obtained, the pauci bacillary nature of the lesions may produce false-negative results. Thus, gastric lavage is frequently used for the diagnosis of TB in children under 6 years-old [4, 5]. Alternate samples include gastric aspirate (GA), induced sputum (IS), nasopharyngeal aspirate, bronchio-alveolar lavage, laryngeal swab, string test and stool samples [2].

It has been reported that gastric lavage samples provide the highest (40–92 %) detection rate, depending on the sensitivity of the laboratory test adopted. The recent introduction of the Cartridge-based nucleic acid amplification test (CBNAAT) has significantly transformed the diagnostics of tuberculosis in adults, but its application for the diagnosis of pediatric TB is under evaluation. This assay is rapid and provides results within 2 h [6, 7]. In patients with low bacterial

load, the CBNAAT test exhibits high sensitivity and specificity for detecting TB [2].

In a policy statement World Health Organization (WHO) in 2011, recommended the use of CBNAAT as a preliminary diagnostic tool among children, in adults with suspected human immunodeficiency virus (HIV) associated tuberculosis and in all MDR TB suspected cases [8]. This study was done to compare efficacy of CBNAAT with smear microscopy in a pediatric population clinically suspected of tuberculosis.

MATERIALS AND METHODS

This study was conducted in the department of Microbiology, Niloufer Hospital, Hyderabad, Telangana, India from September 2017 to February 2018 on pediatric patients with clinical suspicion of pulmonary tuberculosis.

Sputum samples from cases of pulmonary tuberculosis patients and gastric aspirates, fluids and biopsy material etc from extra pulmonary sites were

subjected to Ziehl–Neelsen staining to detect acid fast bacilli and CBNAAT for detection of M.tuberculosis and rifampicin resistance.

Ziehl-Neelsen (ZN) staining

Two drops of sample pellet (approximately 200 µl) were used for smear microscopy (ZN staining), according to the WHO standard protocol. Slides showing red coloured acid fast bacilli were taken as positive and negative slides were those without any acid fast bacilli.

CBNAAT

CBNAAT is a rapid cartridge based fully automated NAAT (Nucleic acid amplification test) for TB case detection and Rifampicin resistance testing suitable for use in disease endemic countries.

It was launched in 2004 by Cepheid and was partnered with FIND (Foundation for Innovative New Diagnostics)

CBNAAT system



Components

Modules- Thermal and Optical systems

Cartridge- Self contained disposable kit

Computer system- Software, barcode scanner

Parts of the machine

Plunger motor, plunger drive shaft, mother board, I core, Cartridge insertor, valve drive motor, ultrasonic horn

Parts of the Cartridge

Processing chambers, Reaction tube, valve body

- Processing chambers – contains beads, reagents, primers and probes, buffers
- Reaction tube – performs a rapid thermal cycling and optical excitation and detection

- Valve body- by turning it directs fluids into different chambers and the PCR tube

Procedure

Collect the sample in a Falcon tube or universal container. Add sample reagent to the sample in a ratio of 2:1. Cap and shake it vigorously for 20 times. Keep the tube in a rack and let it stand still for 10 min. Reshake contents for 20 times and leave for 5 more min. Affix sample id to the side of cartridge. Pipette 2 ml of sample and carefully transfer to open port of cartridge. Close the lid till it snaps closed. Scan the cartridge bar code. Open the module door where the light is blinking. Insert the loaded cartridge into the bay and close the module door properly.

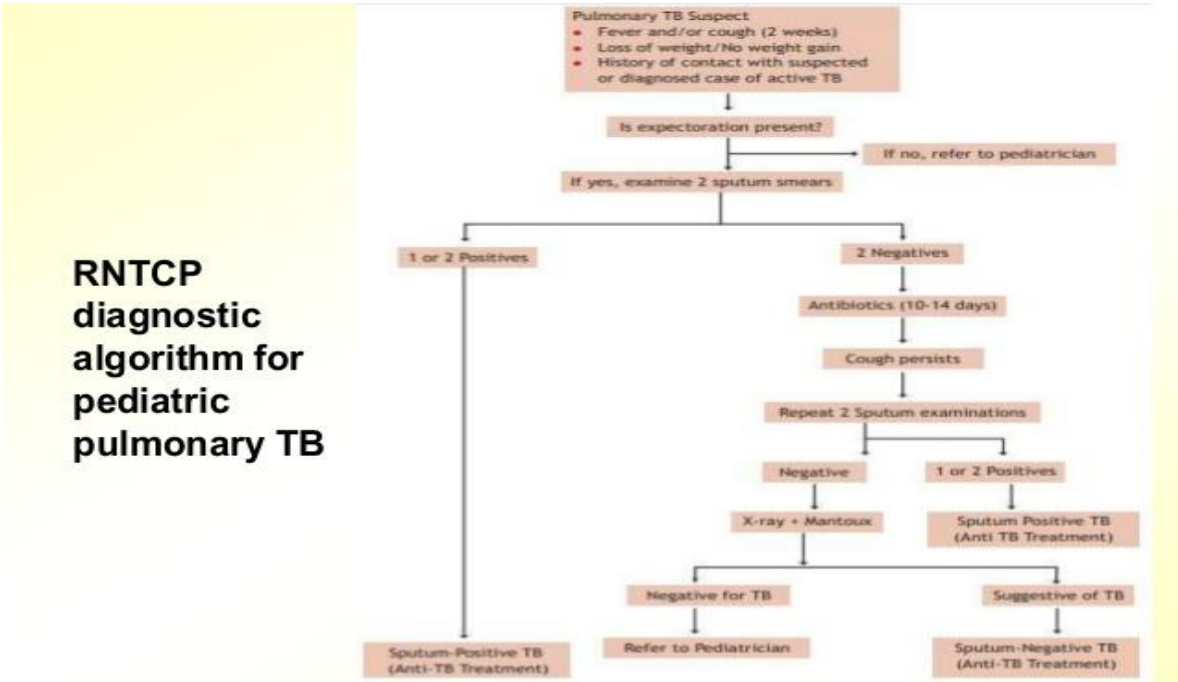
Working of the machine

Sample is automatically filtered and washed. This concentrates bacilli and removes inhibitors. Ultrasonic lysis of filter captured bacilli occurs to release DNA. DNA is mixed with dry PCR reagents. The solution is then pumped into the reaction tube. Here seminested real time amplification and detection occurs. Test results can be displayed on the monitor which can be printed.

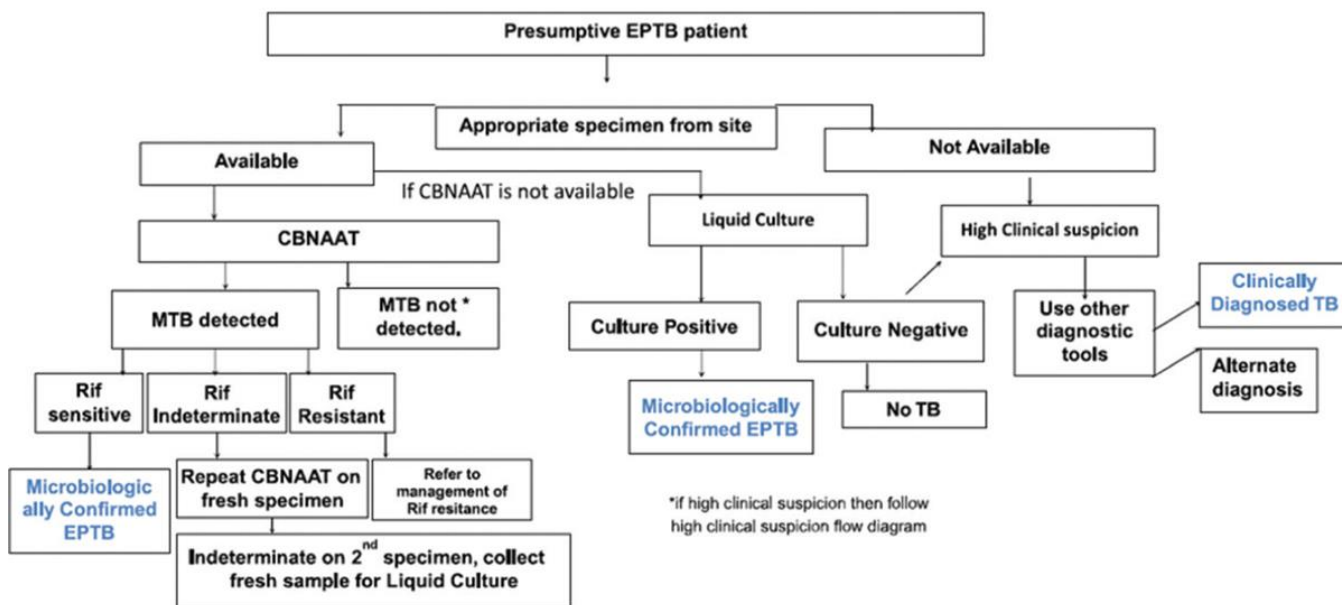
Detection of Rifampicin resistance

CBNAAT uses molecular beacon technology to detect Rif resistance. Molecular beacons are probes

that recognize and report the presence or absence of the normal Rif sensitive wild type sequence of the rpo-B gene of MTB. rpo-B gene has a 81 bp Rif resistance determining region (core region). 5 different coloured beacons are used covering a separate nucleic acid sequence (wild type) within the amplified rpo-B gene. When a beacon binds to the matching sequence it fluoresces which is characteristic of Rif sensitivity. If beacon binds fails to bind to the mutant sequence or if binding is delayed, the sample is potentially resistant to Rif.



Diagnostic Algorithm for Extra Pulmonary TB



RESULTS

A total of 1350 samples taken from pediatric cases of pulmonary and extra pulmonary tuberculosis patients were subjected to CBNAAT. M. tuberculosis

was detected in a total of 28 cases. 26 cases were rifampicin sensitive, one case was indeterminate and one case was rifampicin resistant.

Table-1: Clinical symptoms

Clinical symptoms of suspected TB	Percentage of pediatric patients affected (%)
Cough	98
Fever	87
Loss of weight	76
Loss of appetite	70
Night sweats	56
Blood in sputum	30

Table-2: Positivity in pulmonary samples

Pulmonary	Number of samples	Positive
Gastric aspirate	671	9
Sputum	560	12
Bronchoalveolar lavage	6	0
Total	1237	21

Table-3: Positivity in extrapulmonary samples

Extrapulmonary	Number of samples	Positive
Cerebrospinal fluid (CSF)	70	3
Lymph node pus	10	1
Empyema	6	0
Pleural fluid	17	0
Bone marrow	2	0
Lymph node	6	3
Splenic biopsy	1	0
Lower lobe of lung	1	0
Total	113	7

Table-4: Extrapulmonary Comparative table showing results for CBNAAT and smear examination

	Total number of samples from pediatric patients = 1350			
	Pulmonary = 1237		Extrapulmonary = 113	
CBNAAT	Negative	1216 (98.3%)	Negative	106 (93.8%)
	Positive	21 (1.69%)	Positive	7 (6.19%)
Smear microscopy	Negative	1229 (99.3%)	Negative	112 (99.1%)
	Positive	8 (0.64%)	Positive	1 (0.88%)

DISCUSSION

In the present study , total number of samples collected were 1350 out of which 1237 (91.6%) were pulmonary and 113 (8.37%) were extrapulmonary.

1237 pulmonary samples included 671 gastric aspirate samples, 560 sputum and 6 broncho alveolar lavage samples. Totally 21 samples were positive by CBNAAT out of which 12 were from sputum, 9 from gastric aspirate and none from BAL. One sputum sample was rifampicin resistant .Extrapulmonary samples included CSF, lymph node pus, empyema, pleural fluid, bone marrow, lymph node, splenic biopsy and lower lobe of lung .The major samples constituted 70 CSF, 17 pleural fluid and 10 lymph node pus

samples. The positives were 3 each from CSF and lymph node and 1 from lymph node pus.

Our study co relates with the study by Verma D *et al.*, [9], 2016, in which out of all the total 86 paediatric cases there were 63 pulmonary cases, 22 extrapulmonary cases and 1 MDR contact case. 45 gastric lavage samples and 18 smear negative sputum samples were included for pulmonary cases and MTB was detected by CBNAAT in 6 gastric lavage and 1 smear negative sputum samples. 14 CSF samples, 6 pleural fluid samples and 2 ascitic fluid samples were included for extrapulmonary cases and MTB was detected in 1 CSF sample. No MTB was detected in MDR contact sputum sample. So total 8 paediatric

cases were MTB positive and no case was reported to be MDR.

In the present study, out of the 1237 pulmonary samples 21 (1.69%) were positive by CBNAAT and out of the 113 extrapulmonary samples 7 (6.19 %) were positive by CBNAAT. Total number of samples positive by CBNAAT out of 1350 were 28 (2.07%). Out of the 1237 pulmonary samples 8 (0.64 %) were positive by smear microscopy and out of the 113 extrapulmonary samples 1 (0.88 %) were positive by smear microscopy. Total number of samples positive by smear microscopy out of 1350 were 9 (0.66 %). CBNAAT thus confirmed more cases of TB than AFB smear (28 vs 9)

Our study co-relates with the study of Nita Sutay *et al.*, [2], 2015 in which out of the 80 TB positive patients, CBNAAT was positive in 39 cases and falsely negative in 41 cases while AFB smear was positive in 13 patients and false negative in 67 patients. CBNAAT confirmed more cases of TB than AFB smear (39 vs 13).

It also correlates with the study by Kasa Tom *et al.*, [10], 2017, in which a total of 93 children ≤ 14 years with suspected pulmonary TB were enrolled. Smear microscopy showed positivity in 13 cases. CBNAAT was positive in 26/93 (28%). Three (13%) samples identified rifampicin resistance. Here also, CBNAAT confirmed more cases of TB than AFB smear (26 vs 13).

CONCLUSION

Diagnosis of TB is very challenging in young children, and current tools are inadequate. CBNAAT was found to be a better diagnostic test as compared to smear microscopy in diagnosing pediatric tuberculosis rapidly and accurately. It can significantly reduce false negatives and the delay in treatment initiation, reducing premature death and ongoing transmission. CBNAAT is one of the rapid diagnostic tests available in the country and it should be routinely used under the public and private health sector effectively to detect tuberculosis.

REFERENCES

1. Global tuberculosis report 2017. www.who.int/tb/publications/global_report/en/
2. Sutay N, Swati J, Chaudhary D. "A Comparative Study between Genexpert and Smear Microscopy for Diagnosis of Tuberculosis in Paediatric Patients", International Journal of Science and Research (IJSR), Volume 6 Issue 8, August 2017, 1616 – 1619.
3. Singh S, Singh A, Prajapati S, Kabra SK, Lodha R, Mukherjee A, Singh V, Hesseling AC, Grewal HM. Xpert MTB/RIF assay can be used on archived gastric aspirate and induced sputum samples for sensitive diagnosis of paediatric tuberculosis. BMC microbiology. 2015 Dec;15(1):191.
4. John TJ, Vashishtha VM, John SM. 50 years of tuberculosis control in India: progress, pitfalls and the way forward. Indian pediatrics. 2013 Jan 1;50(1):93-8.
5. Rigouts L. Clinical practice. European journal of pediatrics. 2009 Nov 1;168(11):1285-90.
6. Nicol MP, Zar HJ. New specimens and laboratory diagnostics for childhood pulmonary TB: progress and prospects. Paediatric respiratory reviews. 2011 Mar 1;12(1):16-21.
7. Boehme CC, Nabeta P, Hillemann D, Nicol MP, Shenai S, Krapp F, Allen J, Tahirli R, Blakemore R, Rustomjee R, Milovic A. Rapid molecular detection of tuberculosis and rifampin resistance. New England Journal of Medicine. 2010 Sep 9;363(11):1005-15.
8. World Health Organization (WHO) Automated Real-Time Nucleic Acid Amplification Technology for Rapid and Simultaneous Detection of Tuberculosis and Rifampicin Resistance: Xpert MTB/ RIF System. No. WHO/HTM/TB/2011.4. Geneva, Switzerland: World Health Organization; 2011
9. Verma D, Sharma R, Chand AE, Saxena A. The application of gene xpert for the diagnosis of mycobacterium tuberculosis and MDR TB in Kota region. Int J Med Res Rev 2016;4(10):1863-1870.
10. Kasa Tom S, Welch H, Kilalang C, Tefuarani N, Vince J, Lavu E, Johnson K, Magaye R, Duke T. Evaluation of Xpert MTB/RIF assay in children with presumed pulmonary tuberculosis in Papua New Guinea. Paediatrics and international child health. 2017 May 11:1-9.