

## Absence of Horizontal Fissure, Middle Lobe Fusion and Anomalous Appearance of Mediastinal Surface of Right Lungs: A Rare Case Report

Sanjana Devi<sup>1\*</sup>, Monika Gupta<sup>2</sup>

<sup>1</sup>Assistant Professor, Anatomy Department, Adesh Institute of Medical Sciences and Research, Bathinda, Punjab, India

<sup>2</sup>Professor and Head, Anatomy Department, Adesh Institute of Medical Sciences and Research, Bathinda, Punjab, India

DOI: [10.36347/sjmcr.2023.v11i08.015](https://doi.org/10.36347/sjmcr.2023.v11i08.015)

| Received: 30.06.2023 | Accepted: 02.08.2023 | Published: 10.08.2023

\*Corresponding author: Sanjana Devi

Assistant Professor, Anatomy Department, Adesh Institute of Medical Sciences and Research, Bathinda, Punjab, India

### Abstract

### Case Report

Anatomical variations of lungs in the form of presence of any extra lobe or absence of anatomical lobe, fissures of lungs are important to know to avoid injuries during surgeries related to lungs and associated structures. In this case report absence of middle lobe and horizontal fissure in two right lungs extracted from male cadaver during routine dissection in the Anatomy department, Adesh institute of medical sciences and research, Bathinda, Punjab, India was noted and reported. Every anatomical structure in left side lung of same cadaver was found normal. Also in one abnormal right lung, gross appearance of right lung was looked like left lung. Anatomical knowledge and statistics of every type of variations are important for anatomists for teaching purposes and for surgeons while performing lobectomies, surgical resections of segments of lungs and for radiological interpretations.

**Keywords:** anatomical lobe, horizontal fissure, lungs.

**Copyright © 2023 The Author(s):** This is an open-access article distributed under the terms of the Creative Commons Attribution 4.0 International License (CC BY-NC 4.0) which permits unrestricted use, distribution, and reproduction in any medium for non-commercial use provided the original author and source are credited.

## INTRODUCTION

Hereditary abnormalities of the lungs like agenesis, aplasia, and hypoplasia, absentism of fissures occurs due to underdevelopment of lung parenchyma. There is no accurate reason known for pathogenesis of these variations. There may be association with abnormalities of other system of body including cardiovascular system [1]. The embryonic development of lung starts at around 28<sup>th</sup> day of gestation. Right and left lung buds forms from the laryngotracheal groove. This groove develops from the ventral wall of the pharynx. Trachea and esophagus remain separated from the tracheoesophageal septum [2]. The etiology and pathogenesis is unknown; however, genetic factors, effect of teratogenic agents during pregnancy, deficiency of vitamin A reported as hypothetical factors for development of anomalies in the lungs [3]. Obstruction of middle lobar bronchus leads to collapsing of middle lobe of right lung. Obstruction is due to lodging of foreign objects, narrowing of diameter of bronchus due to extrinsic compression and endobronchial lesion. Non obstructive type of lesion are due to embryological developmental anomalies which

causes collapsing of middle lobe [4, 5]. This obstructs the middle lobe bronchus, causing collapse of the middle lobe. Right middle lobe pulmonary agenesis and presence of extra notch in the anterior border of right lung is rare and attributed to congenital malformations.

## CASE REPORT

During routine dissection for teaching purpose; abnormalities related to lobes, fissures and gross appearance of right lungs were noted in two male cadavers (10%) out of 10 cadavers (20 lungs) of year 2022, in the department of Anatomy, Adesh institute of medical sciences and research, Bathinda, Punjab. Absence of horizontal fissure and fused middle lobe with adjacent lobes were observed in two right lungs extracted from male cadavers. No abnormality was observed in left lung in each cadaver. Content of hilum and roots of both lungs with all contents was found normal whereas a shallow depression like cardiac notch was observed in one right sided lung (lung no. 2). Mediastinal surface, anterior border and posterior border of this lung was giving a resemblance like left sided lung and notes as anomaly (5%).

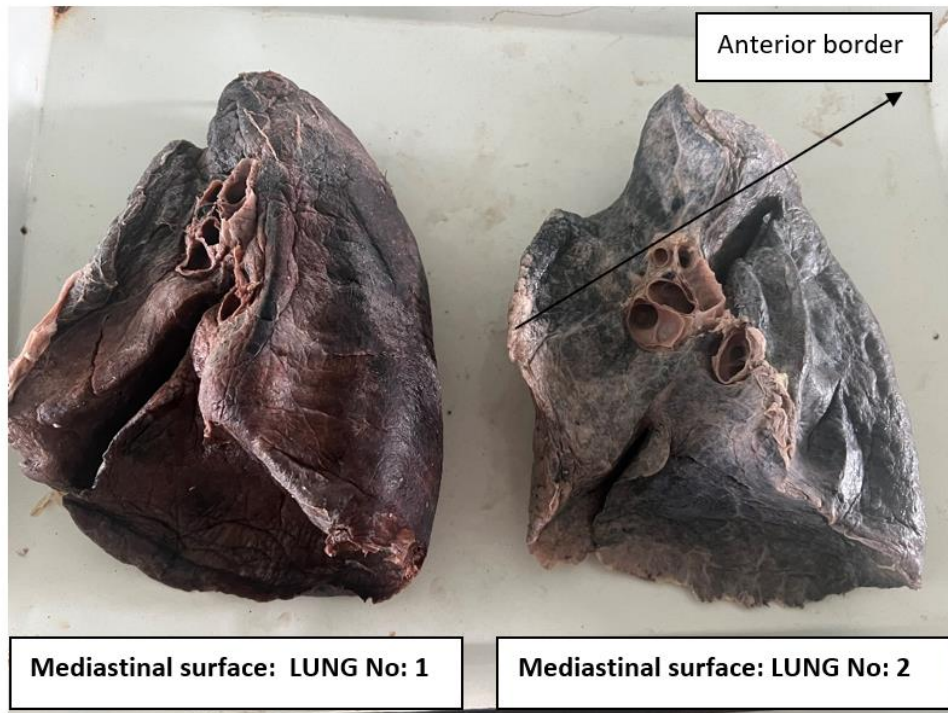


Figure 1: Mediastinal surfaces of right lungs




Figure 2: Sternocostal surfaces of right lungs

## DISCUSSION

Various abnormalities related to gross appearance of lungs including presence of extra lobe, azygous lobe or variations in the contents of root of lungs were reported in the literature but during our search we found very few articles reported complete absence of horizontal fissure of right lung or it was reported that there was incomplete absence of horizontal fissure. The percentage reported in the literature varies from 3.07 % to 25 % in right lung samples whereas the percentage was higher for incomplete presence of horizontal fissure ranges from 12.5% to 66.7% in Indian and International studies [6-8]. Most of the studies reported absence of oblique

fissure with a percentage of 2% for right and 5 % for left lung, which was normal in our cases [9]. None of the article was found related to abnormal appearance of mediastinal surface and extra notch in the anterior border of the right lung which was found in one of our case making it a rare type of abnormality. Also we noted gender variation in the present study as the anomalous lungs belonged to only male cadavers, none of the anomaly was reported in female lung.

## CONCLUSION

Variations in the pulmonary tissues, gross appearance of lungs are important for anatomists for routine teaching in the dissection hall, for surgeons

while performing lobectomies, for radiologists to make correct diagnosis of various radiological aspects. A complete absence of middle lobe and horizontal fissures may cause a problem during surgical approaches, so knowledge and percentage of variations are important for clinical as well as for learning purposes of undergraduate students.

## REFERENCES

1. Clements, B. S. (1999). Congenital malformations of the lungs and airways. In: Landau LI, Taussing LM, editors. *Pediatric Respiratory Medicine*. St. Louis, MO, USA: Mosby; pp. 1106–36.
2. Berrocal, T., Madrid, C., Novo, S., Gutiérrez, J., Arjonilla, A., & Gómez-León, N. (2004). Congenital anomalies of the tracheobronchial tree, lung, and mediastinum: Embryology, radiology, and pathology. *Radiographics*, 24, e17.
3. Gupta, K., Taneja, D., Aggarwal, M., & Gupta, R. (2017). Left upper lobar agenesis of lung: A rare case report. *Lung India: official organ of Indian Chest Society*, 34(3), 302–304.
4. Bertelsen, S. V. E. N. D., Struve-Christensen, E. I. V. I. N., Aasted, A. N. N. E. T., & Sparup, J. (1980). Isolated middle lobe atelectasis: aetiology, pathogenesis, and treatment of the so-called middle lobe syndrome. *Thorax*, 35(6), 449-452.
5. Gudbjartsson, T., & Gudmundsson, G. (2012). Middle lobe syndrome: a review of clinicopathological features, diagnosis and treatment. *Respiration*, 84(1), 80-86.
6. George, B. M., Nayak, S. B., & Marpalli, S. (2014). Morphological variations of the lungs: a study conducted on Indian cadavers. *Anat Cell Biol*, 47(4), 253-8. doi: 10.5115/acb.2014.47.4.253. Epub 2014 Dec 23.
7. West, C. T., Slim, N., Steele, D., Chowdhury, A., & Brassett, C. (2021). Are textbook lungs really normal? A cadaveric study on the anatomical and clinical importance of variations in the major lung fissures, and the incomplete right horizontal fissure. *Clinical Anatomy*, 34(3), 387-396.
8. Joshi, A., Mittal, P., Rai, A. M., Verma, R., Bhandari, B., & Razdan, S. (2022). Variations in Pulmonary Fissure: A Source of Collateral Ventilation and Its Clinical Significance. *Cureus*, 14(3), e23121.
9. Ghosh, E., Basu, R., Dhur, A., Roy, A., Roy, H., & Biswas, A. (2013). Variations of fissures and lobes in human lungs: a multicentric cadaveric study from West Bengal, India. *Int J Anat Radiol Surg*, 2, 5–8.