

## **The Acetabular Fracture-Dislocations: Management and Long-Term Prognosis; Retrospective Study of 62 Cases**

**Mounir Rhounimi\***, Amine Azirar, Ayoub Bouya, Reda Allah Bassir, Moncef Boufettal, Mohamed Kharmaz, My Omar Lamrani, Mohamed El Ouadgiri, Mustafa Mahfoud, Ahmed El Bardouni, Mohammed Saleh Berrada

Service de Traumatologie-Orthopédie. CHU Ibn Sina, Rabat, Morocco

### **Original Research Article**

#### **\*Corresponding author**

*Mounir Rhounimi*

#### **Article History**

*Received: 13.03.2018*

*Accepted: 21.03.2018*

*Published: 30.03.2018*

#### **DOI:**

10.36347/sjams.2018.v06i03.070



**Abstract:** Acetabular Dislocation fractures are most often due to high-energy trauma. They constitute a therapeutic emergency, the association of the dislocation with an acetabulum fracture makes the question of the therapeutic choice between orthopedic treatment and medical treatments appear. We report a retrospective study of 62 cases collected in the orthopedic department of the Rabat University Hospital Center. We evaluated the results of our treatment but also the prognosis in the short and long term. In our series, 44 patients received orthopedic treatment while 18 left were operated; the most used approach is the posterior approach. The functional results were evaluated after a decline of 3 to 8 years, according to the rating of Merle d'Aubigné. We got 90% of satisfactory results. The comparison of our results with those of the literature shows that the result of orthopedic and surgical treatments depends essentially on the type of fracture. The long-term prognosis remains unpredictable. The occurrence of late complications such as cephalic necrosis and osteoarthritis is always unpredictable, which requires regular and prolonged monitoring of patients. Dislocation fractures of the acetabulum are severe, occurring most often in the fasting adult due to high energy trauma. Their prognosis remains unpredictable, as well as the favorable evolution is linked to an adequate management.

**Keywords:** Acetabulum; fracture-dislocation, orthopedic treatment, treatment surgical.

### **INTRODUCTION**

Dislocation fractures of the acetabulum are the result of high energy trauma. They are often associated with other general or regional lesions and must therefore be supported by a multidisciplinary team. This is a therapeutic emergency that requires the reduction of dislocation in the shortest possible time to prevent necrosis of the femoral head. Moreover, the question of the therapeutic choice between orthopedic and surgical treatment is necessary because of the association of dislocation with a fracture of the acetabulum. The prognosis of these lesions is unpredictable, the occurrence of necrosis of the femoral head and hip osteoarthritis even if the treatment is adequate. The objective of the study that we report is to take stock of the management of these fractures as well as their long-term prognosis.

### **METHODS**

Our work is based on the retrospective study of 62 orthopedically or surgically treated fracture-dislocation cases at the orthopedic surgery department of Ibn Sina University Hospital in Rabat during a 6-year period from 2011 to 2016.

We evaluate the outcome of our treatment but also their prognosis in the short and long term. The evaluation is clinical, radiological and functional after a decline of 3 to 8 years.

### **RESULTS AND ANALYSIS**

Our patients average age is 37 years old, with extremes ranging from 17 to 80 years old. The most affected age group is between 20 and 50 years old (75%) with a clear men predominance (80.6%): 50 men and 12 women. We also note a slight predominance of right hip involvement (61.3%). In all the cases that we collected, it was a violent trauma, most often a road accident in 46 cases (74%), realizing the classic shock of the "dashboard", followed by the falls with 13 cases (21%) and work accidents at 3 cases (5%). All the patients benefited from a radiological assessment including a face pelvis incidence, a three-quarter wing incidence, and a three-quarter shutter incidence. In our series we have adopted the JUDET and LETOURNEL classification which distinguishes elementary fractures and complex fractures (Table-1).

100% of our patients benefited of a pelvis Computed Tomography (CT) with frontal, transverse and sagittal sections as well as 3D reconstruction images (Figure-1A, 1B).

We have often had polytrauma patients although 18 of these patients had associated lesions. We classify these lesions as life-threatening cases, 10 of whom had a cranial trauma (16%), 6 cases had thoracic trauma (9, 5%) and 8 cases had an urological lesions. The other lesions were not life threatening, so 2 cases of femur fracture, 6 cases with tibia fracture, 6 cases had a metacarpal fracture and 6 cases of shutter frame fracture and right sacred wing fracture.

Concerning our treatment, we noted that 34 cases were reduced within 24 hours: 18 between few minutes and 12 hours, 6 between 12 and 24 hours, 4 after 24 hours and two within an unspecified time. 10 cases were irreducible: bone incarceration prevented cephalic reintegration; 8 cases of uncontrollable

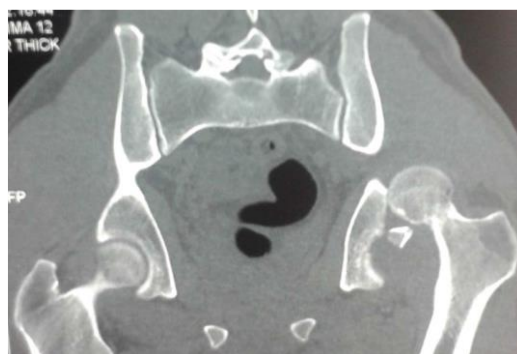
reductions: the hip joint was unstable, which justified the establishment of temporary traction waiting for the final treatment. This last was orthopedic (Figure-2A, 2B) in 50 cases consisting of a trans-tibial traction, sus-condylar traction or a simple discharge from 15 to 45 days. It was surgical (Figure-3A, 3B) in 12 cases.

Our surgical approach used is that of Kocher-Langenbeck except for one patient in whom we combined with an ilioinguinal surgical approach (Figure-4A, Figure 4B). Osteosynthesis was performed by a screwing or screwed plates. Our functional results were evaluated after a 2 to 5 years decline, according to the Merle d'Aubigné score [1]. We obtained 90% of satisfactory results: 24 cases of very good results, 26 cases of good results; 7 cases of average results, 5 cases of poor results (8%) including 1 case of relaxation, 2 cases of periarticular ossifications and 2 cases of femoral head osteonecrosis.

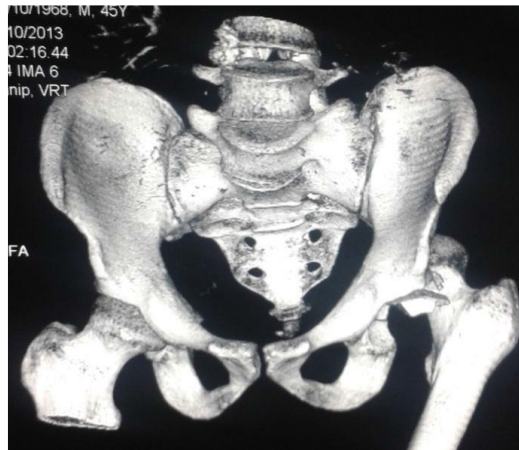
**TABLES AND FIGURES**

**Table-1: Classification of patients according to the anato-pathological lesion and frequency of these lesions**

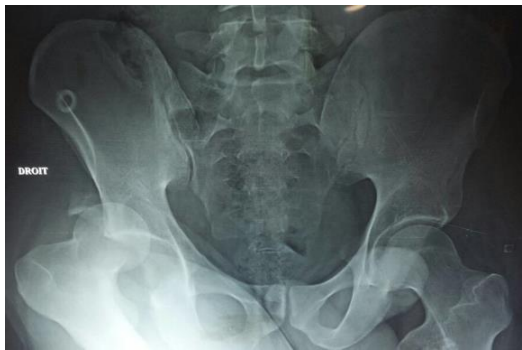Type of fracture	Number of cases	percentage
<b>ELEMENTARY FRACTURES</b>	<b>36</b>	<b>58 %</b>
POSTERIOR WALL (PP)	13	21 %
POSTERIOR COLUMN (CP)	02	03 %
ANTERIOR WALL (PA)	07	11 %
ANTERIOR COLUMN (CA)	01	02 %
CROSS FRATURE	13	21 %
<b>COMPLEX FRACTURES</b>	<b>26</b>	<b>42 %</b>
T FRACTURE	04	06 %
CP + PP	05	08 %
TRANSVERSE FRACTURE + PP	08	13 %
AC + TRANSVERS HEMI	03	05 %
2 COLUMNS	06	10 %



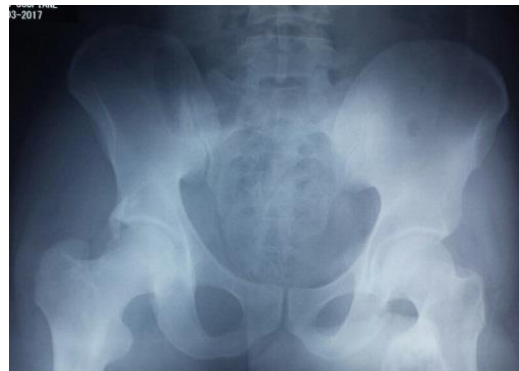**Fig-1A: CT scan images of the pelvis in frontal section showing a dislocation posterior wall dislocation**



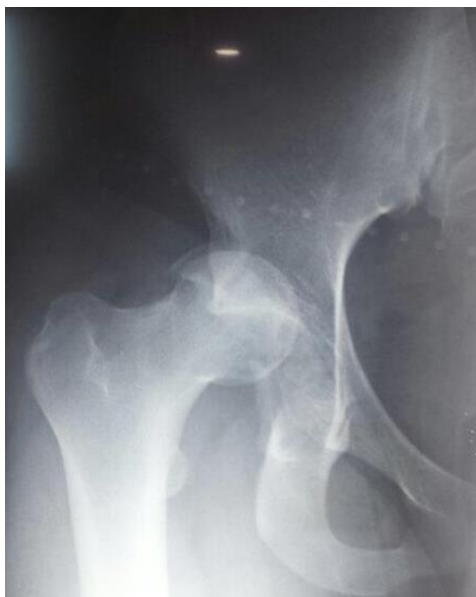**Fig-1B:** CT image in 3D reconstruction showing dislocation fracture of posterior prey



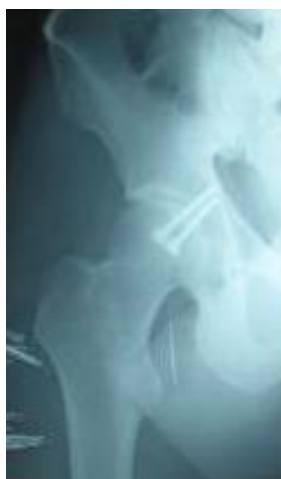**Fig-2A:** Posterior hip radiograph showing posterior wall fracture associated with dislocation of the femoral head



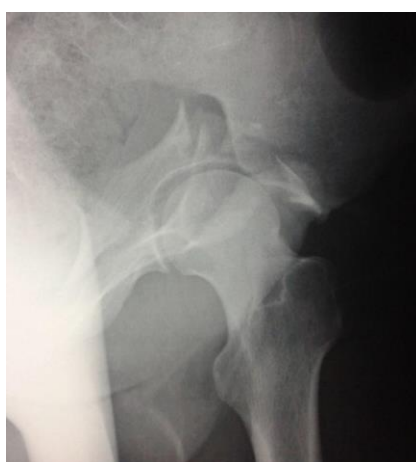**Fig-2B:** Radiography of the pelvis face after reduction of dislocation, the patient was treated orthopedically



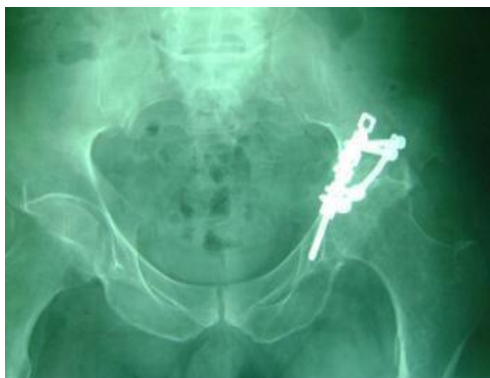**Fig-3A: pelvis radiograph showing fracture dislocation of the posterior wall**



**Fig-3B: postoperative control, screw-in treatment**



**Fig-4A: X-ray of the pelvis showing a transverse fracture of the right acetabulum**



**Fig-4B: Control X-ray after treatment with double anterior and posterior approach**

## DISCUSSION

The hip Fracture dislocations saw their frequencies increase with the multiplication of the traffic accidents; it represents 36% of all acetabulum fractures according to Duquenois [2], 38% according to Rafai [3] and 38% in our series. This lesion occurs with predilection in the young adult male [3,4], which can be explained by the frequency of the accidents in the young active adult and especially of sex male. This dislocation fracture is most often caused by road accidents [3-5].

The front X-ray with the two other incidences are possible to affirm the diagnosis, to specify the dislocation type and to highlight associated fracture. The most common lesion type is posterior dislocation with the posterior wall fracture. CT improves the analysis of joint damage and discovers many associated lesions unknown on standard radiography. Thus the CT allows to highlight intra-articular foreign bodies, to specify the bone lesions and to discover other lesions passed unnoticed, especially sacroiliac, also it allows to check joint congruence, shows impactions, incarceration and of the femoral head notches that escape to standard radiography [6]. Dislocation fractures of the acetabulum are the result of high-energy trauma, involving the hip functional prognosis and sometimes the vital prognosis. The occurrence of late complications such as cephalic necrosis and osteoarthritis is always unpredictable, which requires regular and prolonged monitoring of the patients. In our series, we reported, in addition to lesions found in standard radiology, two cases of complex posterior wall fractures with multiple bone fragments in adjacent soft tissues whose number and volume were invisible on standard radiographs, posterior wall fracture with acetabular roof fracture, posterior wall fracture with an intra-articular bone fragment, and two cases of joint effusion. These results confirm the need to ask CT for any suspicion of hip fracture dislocation.

The circumstances of hip dislocation fracture during road accident explain the frequent association with other local and general lesions. In our series, we noted in 29% of cases (18 cases) associated lesions

against 73.6% of cases (38 cases) in the Troncoso series [7]. Serious cranial and thoracic lesions are common in both series. The treatment's aim is to recover hip function through anatomical reconstruction of joint surfaces and their stable and solid retention. In our series, we justify the chosen treatment by the simple character of the fracture, it did not affect the dislocation reduction stability, and because of the complexity of cotyloid lesions in other cases that are impossible to reduce and contain surgically. During this period, the patients begin the hip passive mobilization of they resume walking with canes-crutches around 3 months after the accident.

The surgical treatment was used in 18 cases (29%), 13 times initially for failure of orthopedic reduction, and 6 times for persistence of a fracture displacement after dislocation reduction. The Kocher-Langenbeck posterior approach was almost the only one used in our series against Kumar [8] on 73 cases of acetabular fracture, a simple approach was used in 67 cases (92%), 41 cases Koer-Langenbeck posterior, 26 cases by ilioinguinal route, 5 cases required the tri-radiated route, and only one case was operated by combined anterior and posterior. The osteosynthesis was a screwing or screwed plate for all authors.

Concerning complications, we had two cases of traction pins infection. Troncoso [7], out of 38 cases, reported one case of osteitis per traction pin, a frequency of 2.6%. Otherwise, all studies [4-11] insist that femoral head necrosis is favored by delayed dislocation reduction. It seems almost impossible to prevent the femoral necrosis occurrence because it all depends on the degree of vascular involvement produced at the time of shock or at the time of reduction. In our series, we had 2 cases of femoral head necrosis. We have not observed any cases of osteoarthritis but it should be noted that the decline in our observations was insufficient to predict the actual frequency of late complications. We obtained 90% of satisfactory results which is consistent with those of the literature.

## CONCLUSION

Acetabulum dislocation fractures are the result of high-energy trauma, involving the functional prognosis of the hip and sometimes the vital prognosis. The CT scan should be requested systematically because it clearly specifies the local lesions and shows other associated lesions. The occurrence of late complications such as cephalic necrosis and osteoarthritis is always unpredictable, which requires regular and prolonged monitoring of patients.

## CONFLICTS OF INTEREST

The authors do not declare any conflict of interest.

## CONTRIBUTIONS OF THE AUTHORS

All the authors contributed to the development of this work. All authors have read and approved the final version of the manuscript.

## REFERENCES

1. Merle RD. Numerical evaluation of hip function. *Revue de Chirurgie Orthopédique et Réparatrice de l'appareil Moteur*. 1970;56(5):481-6.
2. Duquennoy A, Decoulx J, Capron JC, Torabi DJ. Traumatic dislocations of the hip with fracture of the femur head. Apropos of 28 cases. *Revue de chirurgie orthopedique et reparatrice de l'appareil moteur*. 1975;61(3):209-19.
3. Rafai M, Cohen D, Ouarab M, RAHMI M, ARSSI M, FADILI M, TRAFEH M. Les luxations-fractures de la hanche corrélation entre le type lésionnel; Le procédé thérapeutique et l'évolution anatomo-fonctionnelle. *Revue marocaine de médecine et santé*. 1995;17(1):25-32.
4. Letenneur J, Fleuriet M, Sanguy D, Rogez JM, Lignon J, Perol H, Bainvel JV. Intra-articular bony incarceration after reduction of dislocated hip. Diagnostic and therapeutic problems (author's transl). *Journal de chirurgie*. 1978 Feb;115(2):97.
5. Burdin G, Hulet C, Slimani S, Coudane H, Vielpeau C. Luxations traumatiques de hanche: luxations pures et fractures de tête fémorale. *EMC-Rhumatologie-Orthopédie*. 2004 Nov 1;1(6):508-20.
6. Tillie B, Fontaine C, Stahl P, Caillieret J, Duquennoy A. Contribution of X-ray computed tomography to the diagnosis and treatment of fractures of the acetabulum. Apropos of 88 cases. *Revue de chirurgie orthopedique et reparatrice de l'appareil moteur*. 1987;73(1):15-24.
7. Troncoso J, Rueda D, Troncoso E, Soler J. Complications of fracture-luxations of the hip. *Acta orthopaedica Belgica*. 1984;50(3):417.
8. Kumar A, Shah NA, Kershaw SA, Clayson AD. Operative management of acetabular fractures: a review of 73 fractures. *Injury*. 2005 May 1;36(5):605-12.
9. D'Aubigné RM, Mazas F. Luxations postérieures traumatiques de la hanche. *Ann Chir*. 1963;17:1063-90.
10. Marechal E, Tournal JM, Eberhard E, Maisonnier M, Fischer L, Mauras J. Luxations et fractures-luxations de hanche. Facteurs de pronostic, incidence thérapeutique: A propos de 52 cas avec un recul moyen de 7 ans. *Lyon chirurgical*. 1989;85(6):445-51.
11. McKee MD, Garay ME, Schemitsch EH, Kreder HJ, Stephen DJ. Irreducible fracture-dislocation of the hip: a severe injury with a poor prognosis. *Journal of orthopaedic trauma*. 1998 May 1;12(4):223-9.