

Uterine Rupture at 38 Weeks of Gestation Following Salpingectomy with Cornual Resection: A Case Report

Rachid Bzikha*, Najlaa Gribi, Chourouk Karkri, Anas Nah, Najia Zerai, Abelaziz Baidada, Aicha Kharbach

Department of Gynecology-Obstetrics M1-M3 Souissi Maternity Mohamed V University, Ibn Sina Teaching Hospital, Rabat-Morocco

Case Report

*Corresponding author

Rachid Bzikha

Article History

Received: 05.03.2018

Accepted: 18.03.2018

Published: 30.05.2018

DOI:

10.36347/sasjs.2018.v04i05.001



Abstract: Uterine rupture following salpingectomy with corneal resection is a rare entity especially in third trimester of pregnancy. Corneal resection weakens the uterine wall and can lead to a rupture of the uterus. We present a case of uterine rupture at 38 weeks of gestation in a 35 year old patient with history of salpingectomy and corneal resection performed by laparotomy for treatment of interstitial pregnancy. The rupture takes all fundal area and the fetus protruded in abdominal cavity, we succeeded in preserving uterus, and bilateral tubal ligation was done. This exceptional case should sensitize the clinicians for importance of follow-up in patient with previous uterine incision.

Keywords: uterine rupture, salpingectomy, corneal resection, interstitial pregnancy.

INTRODUCTION

Complete uterine rupture after salpingectomy is a rare situation, it's a serious complication in pregnancy that can lead to a catastrophic maternal and fetal outcomes. The incidence of uterine rupture in women with previous uterus scar ranging between 0.3-1.7 %, in the other hand it varies between 0.03 and 0.08 % in an unscarred uterus [1]. Corneal resection is an accepted risk factor for uterine rupture in a subsequent pregnancy [2]. Here we introduce a rare case of fundal uterine rupture at 38 weeks of gestation in a patient having a previous salpingectomy with corneal resection for interstitial ectopic pregnancy, performed by laparotomy.

CASE PRESENTATION

A 35 years old woman, gravida 4 para 2, at 38 weeks of gestation was referred to our center in emergency department for abdominal pain since 12 hours and severe vaginal bleeding.

Her first and third pregnancies were ended by vaginal delivery, but the second gestation was an ectopic pregnancy treated by laparotomic right salpingectomy. She denied any other medical or surgical illnesses and she had no clear surgical report about the management of ectopic pregnancy.

On examination, she was pale, tachycardic at 130 beats per minute with a blood pressure of 90/50 mmHg, and temperature at 37°C. Her hemoglobin was 8 g/dl with normal platelet count, and coagulation profile was normal. Fetal heart sound was inaudible by Pinard stethoscope,

On vaginal touch, no fetal presentation was found, the cervix is 1 cm dilated, 50 % effaced, and membranes were ruptured with bloody amniotic fluid. Ultrasound examination found an empty uterus, a single

dead fetus in abdominal cavity with biometry corresponding to 38 weeks, uterine rupture was diagnosed, and an emergency laparotomy was performed immediately.

Surgical findings revealed 3 liters of bloody ascites in peritoneal cavity, the fetus and the detached placenta were completely out of the uterus, a male fetus of 3600g was delivered from abdominal cavity, inspection showed a large rupture in all fundal area (figure1, 2), repair of uterine defect was performed in three layers with absorbable sutures, in addition to a bilateral tubal ligation, peritoneal lavage and an intraperitoneal drain was left.

Blood transfusion was done and the postoperative course was uneventful, the patient was discharged 5 days later with no complaint.

Iconography

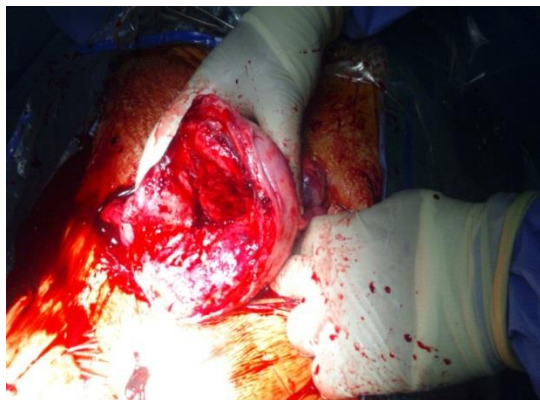

Fig-1: Large uterine rupture in fundal region

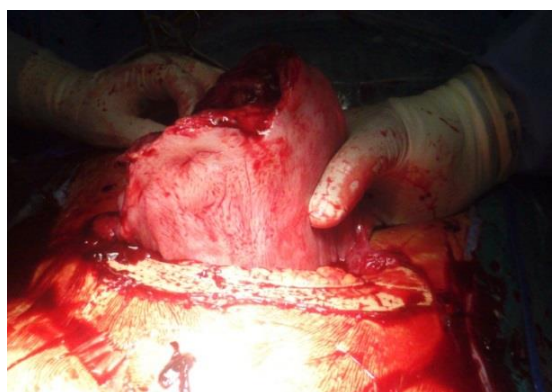


Fig-3: Front view of uterine rupture

DISCUSSION

Uterine rupture occurs frequently in previous scarred uteri, the majority of cases occur in women with cesarean section [3], it may also happen in cases of previous myomectomy, hysteroscopic resection of uterine septum, salpingectomy with cornual resection, and iatrogenic uterine perforation. In our case the patient had a previous laparotomy for interstitial pregnancy treated by right salpingectomy and cornual resection. The diagnosis of uterine rupture should be evoked in all cases of abdominal pain and vaginal bleeding, especially in patients with risk factors.

It's well-known that cornual resection increase the risk of uterine rupture in subsequent pregnancy, it causes attenuation of uterine muscle in cornual area, even though the uterine cavity was not open. Furthermore implantation of placenta around the uterine scar can weaken the uterine wall [2]. 5 cases reported by Arbab *et al* of uterine rupture in women with previous salpingectomy and corneal resection have concluded that this procedure could attenuate uterine wall [4]. Management of ectopic pregnancy by laparotomy gives better strong scar in comparison with laparoscopic surgery, in fact with manual sutures all the layers of uterine defect can be closed on the other hand, during laparoscopy the uterine wall is closed in only one or two layers [5].

Many cases in the literature reported that the majority of uterine rupture after salpingectomy and resection of interstitial portion occurs in 1st and 2nd trimester [5, 6]; in the case presented here the pregnancy was maintained till 38 weeks, but unfortunately our patient had an examination 12 hours after the first symptoms and fetal loss couldn't been avoided .

Early laparotomy is the way for successful management of uterine rupture; hysterectomy is the usual therapy, although conservative treatment with sutures is possible and can help to preserve the reproductive function [7]. In our case we opted for a conservative treatment with bilateral tubal ligation.

CONCLUSION

This case suggest that uterine rupture can occur during pregnancies following laparotomic salpingectomy with corneal resection for ectopic pregnancy, clinicians should maintain a higher index of suspicion for uterine rupture in this situations.

Close follow-up during pregnancy and labor course can reduce the high maternal and perinatal mortality and morbidity owing to uterine rupture.

REFERENCES

1. Ahmed M. Abbas, Mohamed Abdallah, Armia Michael. Recurrent rupture uterus after hysteroscopic resection of uterine septum: A case report. Middle east Fertility Society journal (2017) 22, 340-342.
2. Amir Weissman, Amiram Fishman .Uterine rupture following conservative surgery for interstitial pregnancy, European Journal of Obsfetrics & Gynecology and Reproductive Biology, 44 (1992) 237-239
3. Peng-Hui Wang, Chiou-Chung Yuan, Hsiang-Tai Chao, Ming-Jie Yang, Heung - Tat Ng Posterior uterine wall rupture during labour .Human Reproduction vol.15 n°5 pp.1198-1199, 2000
4. Arbab F, Boulieu D, Bied V, Payan F, Lornage J, Guerin JF. Uterine rupture in first or second trimester of pregnancy after in-vitro fertilization and embryo transfer. Human reproduction. 1996 May 1;11(5):1120-2.
5. Nishijima Y, Suzuki T, Kashiwagi H, Narita A, Kanno H, Hayashi M, Shinoda M, Noji C, Mitsuzuka K, Nishimura O, Ishimoto H. Uterine rupture at 26 weeks of pregnancy following laparoscopic salpingectomy with resection of the interstitial portion: a case report. Tokai J Exp Clin Med. 2014 Dec 20;39(4):169-71.
6. Al-Rejaie SS, Abuhashish HM, Ahmed MM, Arrejaie AS, Aleisa AM, AlSharari SD, Menezes RG, Hussain S, Randhawa MA, Gondal MA, Al-Zahrani AJ. Soayed, Amina A.; Refaat, Heba M. Clinical radiology. 2015;70:2.
7. Guèye M, Mbaye M, Ndiaye-Guèye MD, Kane-Guèye SM, Diouf AA, Niang MM, Diaw H, Moreau JC. Spontaneous uterine rupture of an unscarred uterus before labour. Case reports in obstetrics and gynecology. 2012;2012.