

## The Interest of Hysteroscopy in the Diagnosis and Treatment of Asherman Syndrome

Jawad Kamoune\*, Achraf Med Grohs, Kaoutar Nassim, M. Tazi, A. Filali, R. Bezad, Mh. Alami

National Centre of Reproductive Health, CHIS Mohamed V University, Rabat, Morocco

### Review Article

#### \*Corresponding author

Jawad KAMOUNE

#### Article History

Received: 03.08.2018

Accepted: 06.08.2018

Published: 30.08.2018

#### DOI:

10.36347/sasjs.2018.v04i08.004



**Abstract:** All pathologies or gestures that can cause a change or even an alteration of the uterine lining (alteration of the basal layer) can be the cause of uterine synechiae. They constitute risk factors and are incriminated to varying degrees in the genesis of intrauterine adhesions. From very variable symptomatology, Asherman syndrome can have several manifestations ranging from complete absence of clinical signs to female infertility. The diagnosis of certainty is based on hysterosalpingography and hysteroscopy, which is also a crucial therapeutic time to maintain fertility.

**Keywords:** Uterine synechiae, Asherman syndrome, Hysterosalpingography, Hysteroscopy.

### INTRODUCTION

Uterine synechiae are all adhesions developed between the inner walls of the uterus. Of variable etiologies they are providers mainly of sterility or infertility due essentially to the more or less complete obliteration of the uterine cavity. Their discovery is old, but it is only with the advent and the development of hysteroscopy that Asherman manages to make an exact description of the lesions from where their regrouping in an entity clinic apart: Asherman syndrome [1].

### RISK FACTORS AND AETIOLOGIES OF UTERINE SYNCHASIS

All the pathologies or gestures that can cause a modification or even an alteration of the uterine lining (alteration of the basal layer) can be at the origin of uterine synechiae [2].

They constitute risk factors and are incriminated to varying degrees in the genesis of intrauterine adhesions. Thus, by endometrial changes secondary to pregnancy, the gravid uterus exposes to a high risk of synechia. Post-partum or post-abortion hypostrogenesis results in poor endometrial proliferation and is predisposing to the formation of synechiae especially when endo-uterine involvement is performed [3]. Faced with the delicacy of the endometrium and the softness of the myometrium, curettage trauma can alter the uterine cavity, even if it is done gently.

The depth of curettage is difficult to evaluate. It can cause abrasion and alteration of the basal layer with involvement of regenerative tissue and myometrial tissue. Gravid uterine trauma appears to be the major predisposing factor since it is involved in more than two-thirds.

Curettage of the post-abortum accounts for 58 to 95% of the etiologies of the synechiae [4]. Based on literature data, curettage of the post-abortum is the determining factor in the genesis of synechia in 70.3%

of cases. The aggressive nature of curettage appears to be a contributing factor.

After abortion, 19% to 30% of synechiae are found [5]. It seems that this risk is less in the case of hydatiform moles. Uterine aspiration seems less traumatic than curettage.

Infection also plays a significant role in the genesis of uterine synechiae, whether due to common germs or atypical germs such as genital tuberculosis, although this role is controversial so far some findings seems to confirm this such as the existence of intratubal adhesions following post-curettage salpingitis, although the tubes are not interested in curettage, the histological exploration of synechia is frequently in favor of subacute or chronic endometritis [6].

### CLINICAL PRESENTATION

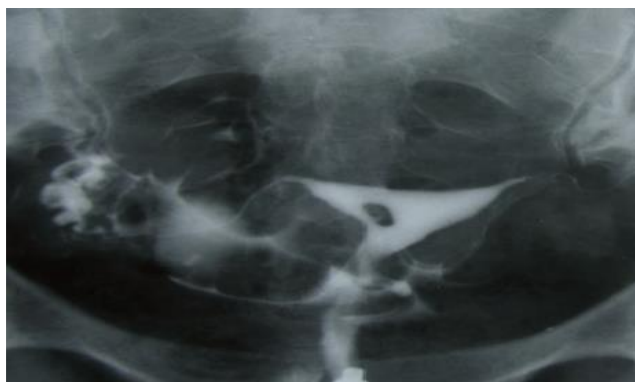
The symptomatology of synechia is very variable. It is a function of the extent, the location of the synechies and their fibrous character. They can be asymptomatic and fortuitous discovery during hysterosalpingography and / or hysteroscopy. These

asymptomatic forms most often involve light intrauterine adhesions. There are three types of symptoms that may or may not be associated in the same patient. The intensity of these symptoms is variable, we distinguish: menstrual disorders (secondary amenorrhea, hypomenorrhea, dysmenorrhea ...) fertility problems and obstetric pathologies, where the existence of synechiae would also be a risk factor for the risk of premature labor, premature rupture of membranes, dystocic presentations. Finally, synechiae can cause amniotic flanks during pregnancy and can be found in obstetrical ultrasound [17, 8].

## DIAGNOSIS

Hysterosalpingography allows positive diagnosis of synechia. It specifies the number, the seat and the exact extent. It also detects a number of

associated lesions such as cervico-isthmic open bite, tubal abnormalities and intra-cavitary lesions or uterine malformations. The radiological image asserting the existence of a synechia corresponds to a punch with sharp edges, central or marginal, secondary to the union of the uterine walls. It can be irregular, linear or angular (Figure 1). These images are constant on all shots (unlike air bubbles) and do not change according to the uterine repletion. They persist on snapshots during evacuation. They can be distinguished from other intracavitary processes by their permanent and invariable character irrespective of the filling (the images of polyp or small submucous fibroma are modified according to the uterine filling). The profile picture confirms the uterine stenosis of the synechiae, contrary to what is observed when these deficiencies are secondary to fibroids or a polyp [9].



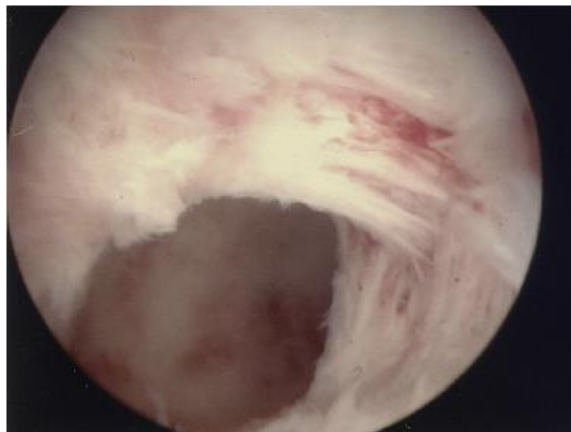
**Fig-1: Small filling defect with totally sharp contour and typical synechiae. The adhesion involves less than ¼ of uterine cavity [20].**

Hysteroscopy is the key examination in the diagnosis and assessment of synechiae. It can sometimes correct some false positives of hysterosalpingography. It is best offered as an outpatient during a consultation. It uses either a rigid hysteroscope of 3 or 5 mm, or a flexible hysteroscope of 3 mm. The distension liquid may be physiological saline or carbon dioxide. It allows the direct positive diagnosis of synechiae and also allows them to be characterized [10]. This element is essential because it provides information on the seniority and the probable surgical difficulties expected. It specifies the type of uterine union, its location, its thickness and its vascularity. The macroscopic pace of synechia: velamentous fibrinous or sclerotic is fundamental. Fibromuscular, dense, pearly synechiae produce an aspect in "elbow" or "spur" whitish, little vascularized,

covered with an atrophic epithelium (Figure 2). They provide a feeling of resistance in contact with the hysteroscope. This type of synechiae corresponds to old lesions and their separation is difficult, contrary to the velamentous or fibrous synechias which are avascular, depressible and which yield during the pressure of the rigid hysteroscope.

The aspect of the peri-lesional endometrium must also be given special attention because it reflects its functionality; it is one of the determining factors of the success or not of the treatment.

Lesions associated with type of polyps, myomas or adenomyosis should always be sought. An endometrial biopsy is most often performed at the end of the hysteroscopic procedure [11].



**Fig-2: Hysteroscopic view of a case of Asherman syndrome with adhesions bands in the anterior and left lateral side wall of the uterine cavity [21].**

### Place of Hysteroscopy in the Management of Uterine Synchiasis

Several authors have tried to prove the therapeutic value of hysteroscopy in the management of Asherman's syndrome, although their results are different. They all seem to conclude that hysteroscopy gives good results.

The first hysteroscopic cures of synechia were described by Asherman of 1948 [12, 13]. They can be made technically difficult by the extent of the synechiated area. It is sometimes difficult to find the safety markers, which may require repeating the procedure one or more times before obtaining a satisfactory anatomical result [14]. The development of operative hysteroscopy has allowed a dramatic evolution of surgical management of intracavitary uterine lesions by reducing morbidity and management costs, while reducing length of hospital stay [15].

Different techniques have been used, from the mechanical lifting of mild synechia using rigid hysteroscopy or scissors [16,17] to the use of monopolar and bipolar energy. The latter is less likely to provide post-myomectomy (7.5%) [18] than monopolar energy (10 to 30%) [19].

The study by Roy *et al.* in 2010 [16] reported a series of 89 patients: 31 mild (stage I according to ESGE), 40 moderate (stage III) and 18 mild (stage IV) synechia. The course of synechia required two operative times in 13.5% of the cases, ie for 12 patients. The overall design rate was 40% at two years.

### CONCLUSION

The management of synechia raises the question of prevention: primary and secondary. Any endocavitary surgery in a patient of childbearing age must be thorough and minimalist, avoiding any endometrial trauma outside the treated lesion.

### REFERENCES

1. Schenker JG, Margalioth EJ. Intrauterine adhesions: an updated appraisal. *Fertil Steril* 1982; 37(5):593-610.
2. Goorah B, Tulandi T. Uterine rupture resulting from the pressure of an intrauterine balloon. *J Obstet Gynaecol Can.* 2009; 31(7):649-51
3. Friedman A, DeFazio J, De Cherney A. Severe obstetric complications after aggressive treatment of Asherman syndrome. *Obstet Gynecol.* 1986; 67(6):864-7
4. Reddy S, Rock JA. Surgical management of complete obliteration of the endometrial cavity. *Fertil Steril.* 1997; 67(1):172-4.
5. Bosteels J, Weyers S, Puttemans P, Panayotidis C, Van Herendael B, Gomel V, Mol BW, Mathieu C, D'hooghe T. The effectiveness of hysteroscopy in improving pregnancy rates in subfertile women without other gynaecological symptoms: a systematic review. *Human reproduction update.* 2009 Sep 10;16(1):1-1.
6. Asherman JG. Amenorrhoea traumatica (atretica). *BJOG: An International Journal of Obstetrics & Gynaecology.* 1948 Feb 1;55(1):23-30.
7. Asherman JG. Traumatic intra-uterine adhesions. *J Obstet Gynaecol Br Emp.* 1950; 57(6): 892-6
8. Neuwirth RS, Amin HK. Excision of submucous fibroids with hysteroscopic control. *Am J Obstet Gynecol.* 1976;126(1):95-9
9. Sculpher MJ, Bryan S, Dwyer N, Hutton J, Stirrat GM. An economic evaluation of transcervical endometrial resection versus abdominal hysterectomy for the treatment of menorrhagia. *BJOG: An International Journal of Obstetrics & Gynaecology.* 1993 Mar 1;100(3):244-52.
10. Fedele L, Vercellini P, Viezzoli T, Ricciardiello O, Zamberletti D. Intrauterine adhesions: current diagnostic and therapeutic trends. *Acta europaea fertilitatis.* 1986;17(1):31-7.
11. Newton JR, Mackenzie WE, Emens MJ, Jordan JA. Division of uterine adhesions (Asherman's

- syndrome) with the Nd-YAG laser. *BJOG: An International Journal of Obstetrics & Gynaecology*. 1989 Jan 1;96(1):102-4.
12. Cravello L, Stolla V, Bretelle F, Roger V, Blanc B. Hysteroscopic resection of endometrial polyps: a study of 195 cases. *European Journal of Obstetrics & Gynecology and Reproductive Biology*. 2000 Dec 1;93(2):131-4.
  13. Roy KK. Reproductive outcome following hysteroscopic adhesiolysis in patients with infertility due to Asherman's syndrome. *Arch Gynecol Obstet*. 2010;281(2):355-61
  14. Yu D. Factors affecting reproductive outcome of hysteroscopic adhesiolysis for Asherman's syndrome. *Fertil Steril*. 2008; 89(3):715-22
  15. Chen FP, Soong YK, Hui YL. Successful treatment of severe uterine synechie with combined with laminaria tent. *Hum Reprod*. 1997;12(5) 943-7
  16. Cararach M, Penella J, Ubeda A, Labastida R. Hysteroscopic incision of the septate uterus: scissors versus resectoscope. *Human Reproduction*. 1994 Jan 1;9(1):87-9.
  17. Thomson AJ, Abbott JA, Deans R, Kingston A, Vancaillie TG. The management of intrauterine synechiae. *Current Opinion in Obstetrics and Gynecology*. 2009 Aug 1;21(4):335-41.
  18. Acunzo G, Guida M, Pellicano M, Tommaselli GA, Di Spiezo Sardo A, Bifulco G, Cirillo D, Taylor A, Nappi C. Effectiveness of auto-cross-linked hyaluronic acid gel in the prevention of intrauterine adhesions after hysteroscopic adhesiolysis: a prospective, randomized, controlled study. *Human Reproduction*. 2003 Sep 1;18(9):1918-21.
  19. Guida M. Effectiveness of auto-crosslinked hyaluronic acid gel in the prevention of intrauterine adhesions after hysteroscopic surgery: a prospective, randomized, controlled study. *Hum Reprod* 2004, 19(6):1461-4
  20. Ahmadi F, Siahbazi S, Akhbari F, Eslami B, Vosough A. Hysterosalpingography finding in intra uterine adhesion (Asherman's Syndrome): a pictorial essay. *International journal of fertility & sterility*. 2013 Oct;7(3):155.
  21. DanYu. Asherman syndrome. *Fertil Steril*. 2008.