

A Study of Measurement of Acetabular Depth Radiologically Among Haryana Population

Vikram Singh¹, Mahesh Kumar^{2*}, Amit Kumar Saxena³¹Medical Officer GH Mandikhera, Al-afia hospital, Mandikhera, Haryana 122108, India²Assistant Professor, Department of Anatomy, SHKM GMC Nalhar (Nuh) Haryana, India³Professor & Head, Department of Anatomy, SGT Medical College Hospital and Research, Village Budhera, Gurgaon, Haryana, IndiaDOI: [10.36347/sjams.2020.v08i02.038](https://doi.org/10.36347/sjams.2020.v08i02.038)

| Received: 10.02.2020 | Accepted: 17.02.2020 | Published: 20.02.2020

*Corresponding author: Dr. Mahesh Kumar

Abstract

Original Research Article

The present study was conducted on 200 persons (100 males and 100 females) of all age group of Haryana region. Antero-posterior view of radiograph of right and left hip joints were taken, after written and informed consent. The depth of acetabulum were measured. The purpose of the study was to assess the depth of acetabulum and to compare with the previous studies and also to find out the significant sex difference. The mean acetabular depth in males was 14.20 mm in Right side and 14.70 mm in left side. Similarly in female the mean acetabular depth were 13.88 mm in right side and 14.60 mm in left side. There was a significant difference in value of acetabular depth in right and left side, in both sexes. Therefore knowledge of various parameters of acetabulum would be helpful for prosthetists, orthopaedicians and forensic experts.

Keywords: Acetabulum, Depth, Measurements.

Copyright @ 2020: This is an open-access article distributed under the terms of the Creative Commons Attribution license which permits unrestricted use, distribution, and reproduction in any medium for non-commercial use (NonCommercial, or CC-BY-NC) provided the original author and source are credited.

INTRODUCTION

Acetabulum (Latin acetabulum, vinegar cup, from acetum—vinegar) is a deep cup shaped hemispherical depression on the hip bone formed medially by the pubis, above by the ilium, laterally and below by the ischium, bounded by a prominent acetabular rim [1]. Its shape and position related to the head of femur are crucial for the biomechanics of the hip joint. The acetabulum forms from the coalescence of three ossification centers (collectively called the triradiate cartilage): ilium, pubis and ischium [2]. The acetabular fossa is a central cavity containing the ligamentum teres and a fat pad called pulvinar. The ligamentum teres connect the acetabulum to the fovea of femoral head. The labrum which arise from limbus, is a ring of connective tissue surrounding the outer edge of the acetabulum [2]. The acetabular articular surface is deficient inferiorly opposite the acetabular notch and is covered by articular cartilage, which is thickest where the surface is broadest [3]. The depth of the acetabulum was defined as the distance between the deepest part of the acetabulum relative to the rim plane. This depth is of interest because of its influence on the range of movement of the femoral component and acetabular cover [4, 5]. The acetabular depth described by Murray is another method to compensate the inaccuracy of

Wiberg angle which was caused by the formations of bony spur on lateral margin of acetabulum (osteophytes) and displacement of femoral head [6, 7]. The knowledge of various acetabular dimensions is essential to diagnose various diseases of hip joint [8]. A study of anatomical dimensions of the components of the hip joint is also important for understanding of the etiopathogenesis of diseases like primary osteoarthritis of the hip joint [9]. Hip joint which was previously known as a ball and socket joint is also described as a rotational conchoids [10]. Dysplasia of the acetabulum or minor anatomical variation in the fitting of the components of the joint have been suggested as contributory factors in the causation of osteoarthritis [11].

MATERIALS AND METHODS

The present study was carried out on pelvic radiographs of 200 patient of Haryana. All age groups of the patients who had undergone for pelvic x-rays AP view routinely, with radiologically normal x-rays were included in the study. Acetabular depth were measured.

ACETABULAR DEPTH

A tangent line is drawn from the most lateral edge of the acetabulum to the upper edge of the

symphysis pubis on the same side. A perpendicular line is drawn to the deepest point of the acetabulum roof and distance is stated in millimeters [7].

EXCLUSION CRITERIA

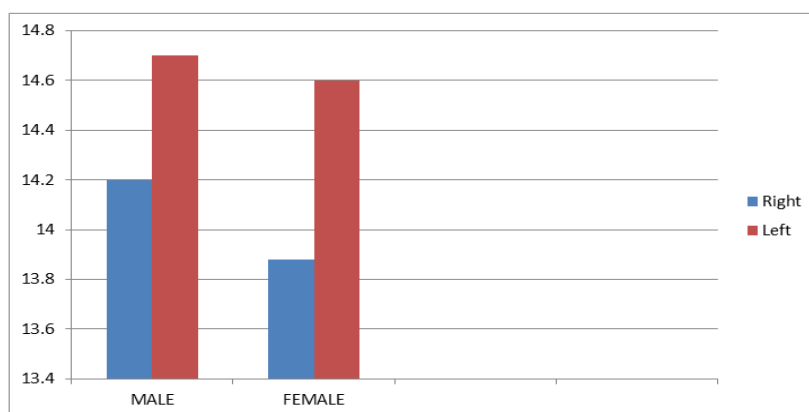
Radiographs of patients with osteoarthritis, metabolic diseases, hip fractures were excluded from study.

OBSERVATIONS & RESULTS

We included 200 radiographs of pelvis in this study. 100 males and 100 females. Following observations were made in this study.

Table-1: Descriptive statistics for acetabular depth (n=200 (100 M A& 100F))

Parameter	sex	Mean		SD		SEM		RANGE			
		Right	Left	Right	Left	Right	left	Maximum		Minimum	
								Right	Left	Right	Left
Acetabular depth	M	14.20	14.70	3.08	3.25	0.3143	0.3219	25	25	8	8
	F	13.88	14.60	3.64	3.43	0.3525	0.3459	22	22	7	8



Graph-1: Mean acetabular depth in males and female

Table-2: Showing comparison of right and left acetabular depth in males & females by paired t test

Parameter	Sex	Mean difference	t-value	p-value
Acetabular depth	Males	-0.50	-2.55	0.001
	Female	-0.72	-3.325	0.001

Table-3: Comparison of mean depth of acetabulum of present study with the previous studies

S. No	Authors	Year	Population	Mean
1	Croft <i>et al.</i> , [12]	1991	England	14.4 mm
2	Smith RW <i>et al.</i> , [13]	1995	UK	14.4 mm
3	Lau <i>et al.</i> , [14]	1995	China	11.8mm
4	Goker <i>et al.</i> , [15]	2005	Turkish	13.7mm (Right) 13.6mm (left)
5	Saika <i>et al.</i> , [16]	2008	India	25 mm
6	Park JM <i>et al.</i> , [17]	2011	Korea	11.6 mm
7	Jermic D <i>et al.</i> , [18]	2011	Serbian	11.9 mm 12.5 in males, 11.2mm in females
8	Present study	2018	Haryana(India)	14.20mm (Right) & 14.70mm (Left) in males 13.88mm (Right), 14.60mm (Left) in females

DISCUSSION

From above table, we found that the mean value of Acetabular depth in our study was greater than the study done by Lau *et al.*, [14], Goker *et al.*, [15], Jermic D *et al.*, [18] and Park JM *et al.*, [17] study and

was nearly similar to study done by Croft *et al.*, [12] and Smith RW *et al.*, [13] but less than the study done by Saika *et al.*, [16] on South Indian Populations. It is also observed that in males there is significant difference in value of acetabular depth in right and left side of hips. The t- value of right and left side

acetabular depth was -2.55 (p -value 0.01). Similarly in case of females there is significant difference in value of acetabular depth in right and left side of hips. The t -value of right and left side was -3.325 (p -value 0.01). The acetabular depth has been regarded by many authors as an important measurement to define acetabular dysplasia. An acetabular depth of less than 9 mm is considered dysplastic [19]. Hence awareness of the average values of the bones of hip joint in males and females will also help in early sex determination from skeletal remains by forensic experts [8].

CONCLUSION

It was concluded that, in Haryanvi population, the mean acetabular depth in males is 14.20 mm in right side and 14.70 mm in left side. In female the mean acetabular depth is 13.88 mm in right side and 14.60 mm in left side. Also significant difference is seen in the value of acetabular depth in right and left side of hips, both in males and females. Hence knowledge of these parameters of hip can be used for better understanding of etiopathogenesis of diseases like osteoarthritis and prevalence of acetabular dysplasia.

REFERENCES

- Arsić S, Ilić D, Mitković M, Tufegdžić M, Janković S, Trajanović M. The study of morphological parameters of human acetabulum significant for hip arthroplasty. 2019.
- Khan JM, Banday MI, Muzaffar J. A study of measurement of acetabular diameter radiologically in northern Indian population of Jammu region. *International Journal of Orthopaedics*. 2018;4(3):78-81.
- Khobragade L, Vatsalawamy P. Morphometric study of depth of acetabulum. *International Journal Research Medical Science*. 2017 Sep; 5(9):3837-42.
- Murtha PE, Hafez MA, Jaramaz B, DiGioia Iii AM. Variations in acetabular anatomy with reference to total hip replacement. *The Journal of bone and joint surgery. British volume*. 2008 Mar;90(3):308-13.
- Msamati BC, Igbigbi PS, Lavy CB. Geometric measurements of the acetabulum in adult Malawians: radiographic study. *East African medical journal*. 2003;80(10):546-9.
- Han CD, Yoo JH, Lee WS, Choe WS. Radiographic parameters of acetabulum for dysplasia in Korean adults. *Yonsei medical journal*. 1998 Oct 1;39(5):404-8.
- Murray RO. The aetiology of primary osteoarthritis of the hip. *The British journal of radiology*. 1965 Nov;38(455):810-24.
- Sachdeva K, Singla RK, Kalsey G, Sharma P. Sex Differences in Morphometry of North Indian Acetabula—Forensic and Orthopedic Consideration. *National Journal of Clinical Anatomy*. 2019 Oct;8(04):153-9.
- Jeremić D, Živanović-Mačužić I, Vulović M. Sex differences in anatomical parameters of acetabulum among asymptomatic Serbian population. *Vojnosanitetski preglod*. 2011;68(11):935-39.
- Menschik A. *Biometric*: Springer, Berlin, Heidelberg, New York. 1987.
- Mukhopadhaya B, Barooh B. Osteoarthritis of hip in Indians. An anatomical and clinical study. *Journal Bone Joint Surgery*. 1979; 61B:339-41.
- Croft P, Cooper C, Wickham C, Coggon D. Osteoarthritis of the hip and acetabular dysplasia. *Annals of the rheumatic diseases*. 1991 May 1;50(5):308-10.
- Smith RW, Egger P, Coggon D, Cawley MI, Cooper C. Osteoarthritis of the hip joint and acetabular dysplasia in women. *Annals of the rheumatic diseases*. 1995 Mar 1;54(3):179-81.
- Lau EM, Lin F, Lam D, Silman A, Croft P. Hip osteoarthritis and dysplasia in Chinese men. *Annals of the rheumatic diseases*. 1995 Dec 1;54(12):965-9.
- Goker B, Sancak A, Haznedaroglu S. Radiographic hip osteoarthritis and acetabular dysplasia in Turkish men and women. *Rheumatology international*. 2005 Sep 1;25(6):419-22.
- Saikia KC, Bhuyan SK, Rongphar R. Anthropometric study of the hip joint in Northeastern region population with computed tomography scan. *Indian journal of orthopaedics*. 2008 Jul;42(3):260-66.
- Park JM, Im GI. The correlations of the radiological parameters of hip dysplasia and proximal femoral deformity in clinically normal hips of a Korean population. *Clinics in orthopedic surgery*. 2011 Jun 1;3(2):121-7.
- Jeremić D, Živanović-Mačužić I, Vulović M. Sex differences in anatomical parameters of acetabulum among asymptomatic Serbian population. *Vojnosanitetski preglod*. 2011;68(11):935-9.
- Loder RT, Mehbod AA, Meyer C, Meisterling M. Acetabular depth and race in young adults: a potential explanation of the differences in the prevalence of slipped capital femoral epiphysis between different racial groups?. *Journal of Pediatric Orthopaedics*. 2003 Nov 1;23(6):699-702.