

## Sociodemographic and Clinical Profile of Tubercular Meningitis Patients without Pulmonary Signs and Symptoms

Dr. Sayat Quayum<sup>1\*</sup>, Prof. Dr. Md. Titu Miah<sup>2</sup>, Dr. Tanzila Ferdous<sup>3</sup>, Dr. Suriya Shahaly<sup>4</sup>, Dr. Sayeda Moni Chowdhury<sup>5</sup>, Dr. Faisal Bin Yousuf<sup>6</sup>, Dr. Shamah Marzuqah<sup>7</sup>

<sup>1</sup>Specialist, Internal Medicine Department, Evercare Hospital, Dhaka, Bangladesh

<sup>2</sup>Professor of Medicine, Acting Director General of Directorate General of Medical Education, Bangladesh

<sup>3</sup>Specialist, Internal Medicine Department, Evercare Hospital, Dhaka, Bangladesh

<sup>4</sup>Junior Consultant, Physical Medicine and Rehabilitation Department, Ahsania Mission Cancer and General Hospital, Dhaka, Bangladesh

<sup>5</sup>Assistant Professor, Department of Internal Medicine, International Medical College Hospital, Dhaka, Bangladesh

<sup>6</sup>Medical Officer, Internal Medicine Department, Dhaka Medical College & Hospital, Dhaka, Bangladesh

<sup>7</sup>Specialist, Neuro Medicine Department, Square Hospital Limited, Dhaka, Bangladesh

DOI: [10.36347/sjams.2023.v11i08.030](https://doi.org/10.36347/sjams.2023.v11i08.030)

| Received: 01.07.2023 | Accepted: 08.08.2023 | Published: 29.08.2023

\*Corresponding author: Dr. Sayat Quayum

Specialist, Internal Medicine Department, Evercare Hospital, Dhaka, Bangladesh

E-mail: [neel.nilima07@gmail.com](mailto:neel.nilima07@gmail.com)

### Abstract

### Original Research Article

**Background:** Among the different forms of CNS tuberculosis, tubercular meningitis (TBM) is the most frequent one. Early diagnosis and treatment of tubercular meningitis (TBM) can give an excellent outcome with minimal residual morbidity. Sociodemographic and clinical findings of patients with or without pulmonary signs and symptoms may be useful for the early diagnosis and treatment of suspected TBM patients. **Aim of the study:** This study aimed to make a sociodemographic and clinical profile of tubercular meningitis patients without pulmonary signs and symptoms. **Methods:** This was a cross-sectional study that was conducted in the Department of Medicine, Dhaka Medical College Hospital (DMCH), Dhaka, Bangladesh, from September 2020 to August 2021. A total of 77 diagnosed cases of tubercular meningitis without pulmonary signs and symptoms admitted to the mentioned hospital were included in this study as the study population. In sample selection, a purposive sampling technic was used. Along with the sociodemographic as well as clinical findings, all relevant information was recorded in a data collection sheet. After completion, data analysis was done by SPSS 23.0. **Results:** The mean age of our respondents was 37.93±11.8 years; 53.2% of them were male and 46.8% were female. The majority of the respondents were service holders (32.5%) and the majority (57.1%) of the patients had middle-family income. In this study, 61% of the study population had a family history of TB. As for the clinical features of TBM, we observed that all of the study subjects had a fever, 80.5% had a headache, 68.8% had altered sensation, 62.3% had anorexia and nausea, 55.8% had vomiting, 19.5% had convulsions and 15.6% had neck stiffness. The majority (46.8%) of the respondents had TBM Grade II. In total, 58.4% of the respondents had Mantoux test positive and 41.6%, whereas 36.4% showed chest X-ray positive for TB. **Conclusion:** The prevalence of tubercular meningitis without pulmonary signs and symptoms among males or service holders or middle-income family members is higher than in other groups. Family history may be a potential factor for such a disease. Fever, headache, altered sensation, anorexia/nausea and vomiting are very common clinical features in such patients. **Keywords:** Sociodemographic, Clinical profile, Tubercular meningitis, Pulmonary signs, Symptoms.

Copyright © 2023 The Author(s): This is an open-access article distributed under the terms of the Creative Commons Attribution 4.0 International License (CC BY-NC 4.0) which permits unrestricted use, distribution, and reproduction in any medium for non-commercial use provided the original author and source are credited.

## INTRODUCTION

Tubercular meningitis (TBM) is one of the most severe types of extra pulmonary tuberculosis (TB), although it is not so much frequent. Tubercular meningitis carries a high mortality rate, especially in those who were delayed diagnosed [1]. Natural history, as well as clinical manifestations of tuberculosis, are different in children and adults, with a higher incidence

rate of disseminated forms [2]. Tubercular meningitis (TBM) is characterized as an extreme manifestation of tuberculosis and usually requires emergent intervention. Both clinically as well as pathologically, tubercular meningitis (TBM) is difficult to diagnose because of its similarity with other neurological disease manifestations [3]. Because of the low response in smear isolation and culture, diagnosis of tubercular meningitis is very difficult. So, sometimes the diagnosis is performed only

**Citation:** Sayat Quayum, Md. Titu Miah, Tanzila Ferdous, Suriya Shahaly, Sayeda Moni Chowdhury, Faisal Bin Yousuf, Shamah Marzuqah. Sociodemographic and Clinical Profile of Tubercular Meningitis Patients without Pulmonary Signs and Symptoms. Sch J App Med Sci, 2023 Aug 11(8): 1560-1566.

on preliminary cerebrospinal fluid findings, clinical, neuroimaging and chest x-ray findings where definitive microbiological confirmation is unavailable. Specific clinical characteristics like longer duration of symptoms, moderate CSF pleocytosis, as well as the presence of focal deficits increase the probability of tubercular meningitis [4]. Recently, most experts have concluded that commercial nucleic acid amplification tests can confirm TBM but cannot rule it out [5]. Chest radiology finds active or previous tuberculosis infections in about 50% of those with TBM in high-prevalence of TB areas. Miliary TB strongly suggests multiorgan involvement; therefore, it is beneficial when shown by a chest radiograph [6]. A study found that 50% of patients with TBM had abnormal chest X-ray findings [1]. At the same time, chest X-ray findings favoring pulmonary TB were found in 30% of tubercular meningitis patients without respiratory signs and symptoms [7]. A study by Corral *et al.*, (2004) [8] showed in tubercular meningitis patients, approximately one-third of them had a background of miliary tuberculosis. A study performed by Aurangzeb *et al.*, (2008) [7] showed the study respondents who had positive chest X-rays; among them, 43.3% of cases were in grade III clinical grading of tubercular meningitis. So, along with clinical findings and laboratory investigation findings, the chest x-ray findings of tubercular meningitis patients have a supporting role in diagnosing the patient more priorly. The objective of this study was to make a sociodemographic and clinical profile of tubercular meningitis patients without pulmonary signs and symptoms.

## METHODOLOGY

This cross-sectional study was conducted in the Department of Medicine, Dhaka Medical College Hospital (DMCH), Dhaka, Bangladesh, from September 2020 to August 2021. A total of 77 diagnosed cases of tubercular meningitis without pulmonary signs and symptoms admitted to the mentioned hospital were included in this study as the study population. In sample selection, a purposive sampling technic was used. The study was approved by the ethical committee of the mentioned hospital. Properly written consent was taken from all the participants before data collection. The whole intervention was conducted following the principles of human research specified in the Helsinki Declaration [9] and executed in compliance with currently applicable regulations and the provisions of the General Data Protection Regulation (GDPR) [10].

### Inclusion criteria:

- Age > 18 years
- Patients fulfilling the Modified Ahuja criteria for tubercular meningitis.

### Exclusion criteria:

- Patients who complained of respiratory symptoms like productive cough, breathlessness or chest pain.

- Patients who had abnormal findings of chest examination on admission.
- Who were already on anti-TB drugs.
- Pregnant women

### Socio-demographic variables:

- Age
- Sex
- Occupation
- Economic status
- Family history of tuberculosis

### Clinical and laboratory variables:

- Clinical presentation
- Grading of TBM
- Chest radiograph findings
- CSF examination findings
- Mantoux test
- CT scan of the head or MRI findings of the brain

All data were registered, documented and analyzed in the statistical program of Statistical Package for Social Science (SPSS) version 23.0. The data were systematically described, summarized and presented through descriptive statistics. Continuous variables were expressed as means  $\pm$  standard deviations (SD), while categorical variables were described as frequency and percentage. The chi-square test was also considered to express the association between categorical variables. P-value <0.05 was considered as a level of statistical significance.

## RESULT

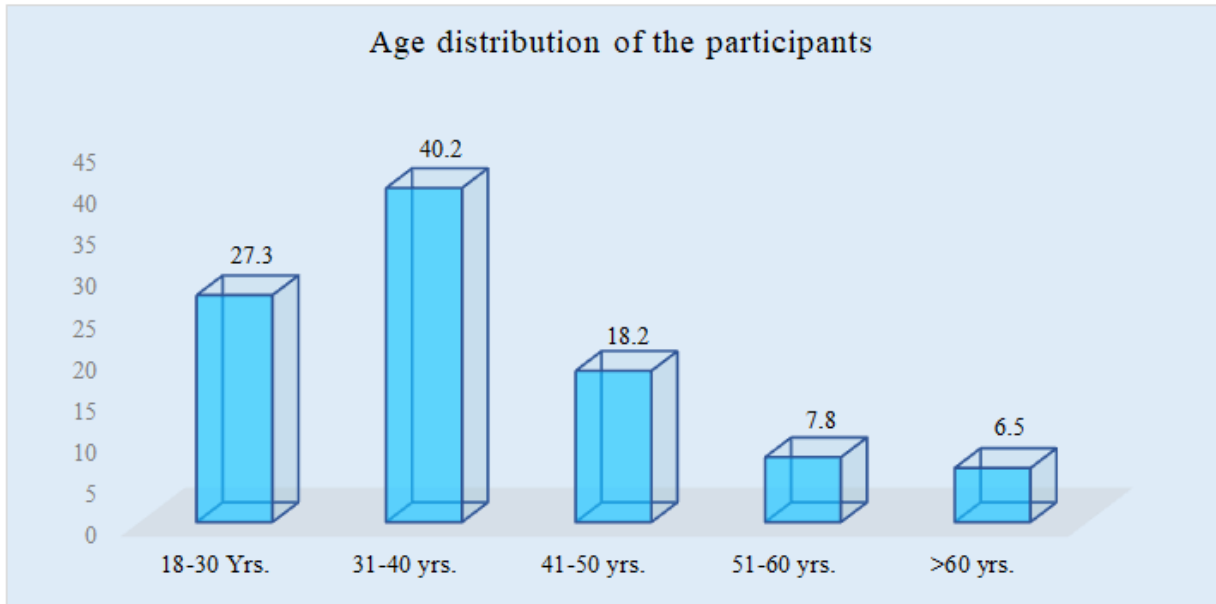
In this study, among all the respondents, 40.2% were aged between 31 and 40 years, followed by 27.3% between 18 and 30 years, 18.2% between 41 and 50 years, 7.8% between 51 to 60 years and 6.5% respondents were from >60 year's age group. The mean age of the respondents was  $37.93 \pm 11.8$  years. Among the total participants, 53.2% were male and 46.8% were female. The majority of the respondents were service holders (32.5%), followed by 28.6% were businessmen, 18.2% were housewives, 10.4% were unemployed, 6.5% were day laborers and 3.8% were cultivators. The majority (57.1%) of the patients had middle family income, 28.6% had low income and 14.3% had high family income. In this study, 61% of the study population had a family history of TB and 39% had no family history of TB. Among all the patients, all had fever, 80.5% had headache, 68.8% had altered sensation, 62.3% had anorexia and nausea, 55.8% had vomiting, 19.5% had a convulsion and 15.6% had neck stiffness. In our settings, the majority (46.8%) of the respondents had TBM Grade II. Besides, 31.1% had TBM Grade III and 22.1% had Grade I. Among our settings, the mean WBC count was  $134.80 \pm 34.59$  10<sup>6</sup>/L, Lymphocyte (%) was  $79.49 \pm 11.77$ , Glucose was  $26.49 \pm 5.43$  mg/dl, Protein was  $142.8 \pm 72.5$  and ADA level was  $12.08 \pm 1.29$  U/L. In our settings,

58.4% of the respondents had Mantoux test positive and 41.6% had a negative result. On the other hand, among

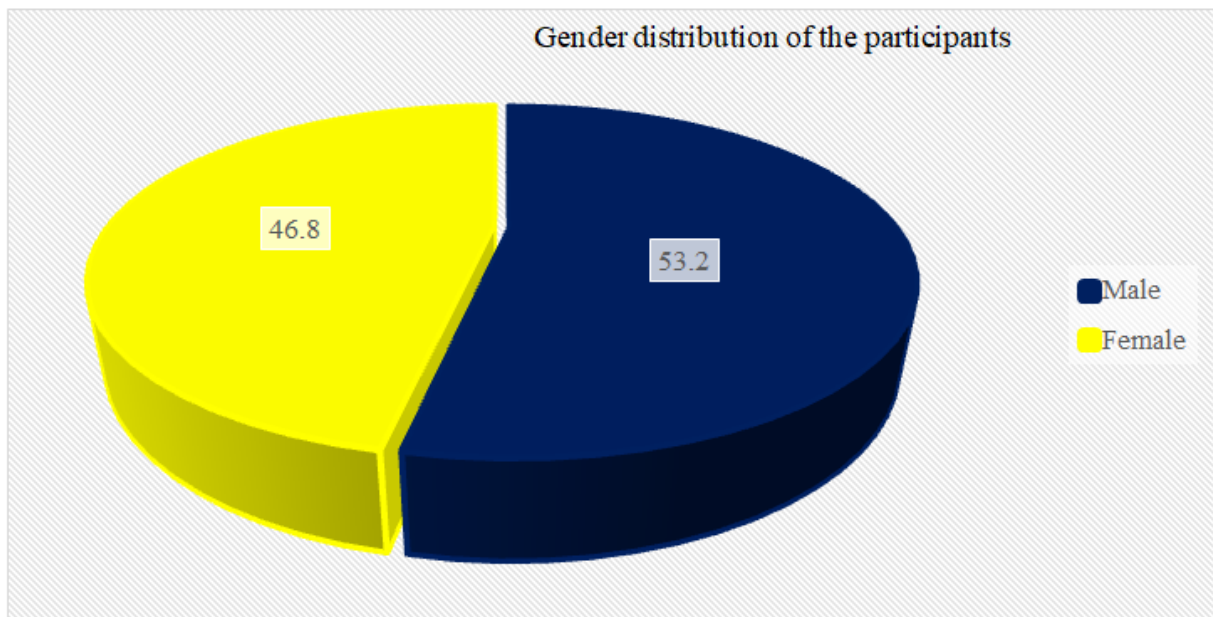
all the respondents, 36.4% showed chest X-ray positive and 63.6% showed negative chest X-ray for TB.

**Table 1: Distribution of participants as per age, (N=77)**

Age (Years)	n	%
18-30 yrs.	21	27.3
31-40 yrs.	31	40.2
41-50 yrs.	14	18.2
51-60 yrs.	6	7.8
>60 yrs.	5	6.5
Mean $\pm$ SD	37.93 $\pm$ 11.8	



**Figure I: Column chart showed age wise participants distribution, (N=77)**



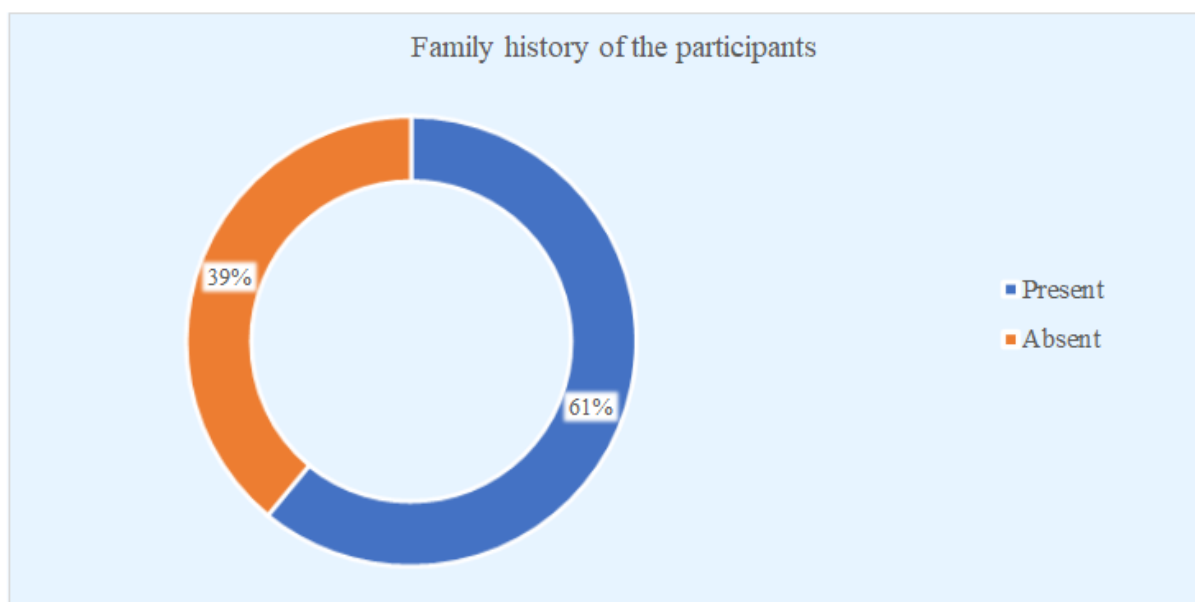
**Figure II: Pie chart showed gender wise participants distribution, (N=77)**

**Table 2: Distribution of the respondents by occupation, (N=77)**

Occupation	n	%
Service	25	32.5
Business	22	28.6
Housewife	14	18.2
Unemployed	8	10.4
Day laborer	5	6.5
Cultivator	3	3.8

**Table 3: Distribution of the respondents by family income, (N=77)**

Family income	n	%
Low income	22	28.6
Middle income	44	57.1
High income	11	14.3

**Figure III: Ring chart showed distribution of the respondents by family history of tuberculosis, (N=77)****Table 4: Distribution of the study population by clinical features of TBM, (N=77)**

Clinical features	n	%
Fever	77	100
Headache	62	80.5
Altered consciousness	53	68.8
Anorexia, Nausea	48	62.3
Vomiting	43	55.8
Convulsion	15	19.5
Neck stiffness	12	15.6

**Table 5: CSF findings of the study population, (N=77)**

CSF findings	Mean $\pm$ SD
WBC count ( $10^6/L$ )	134.80 $\pm$ 34.59
Lymphocyte (%)	79.49 $\pm$ 11.77
Glucose (mg/dl)	26.49 $\pm$ 5.43
Protein (mg/dl)	142.8 $\pm$ 72.5
ADA (U/L)	12.08 $\pm$ 1.29

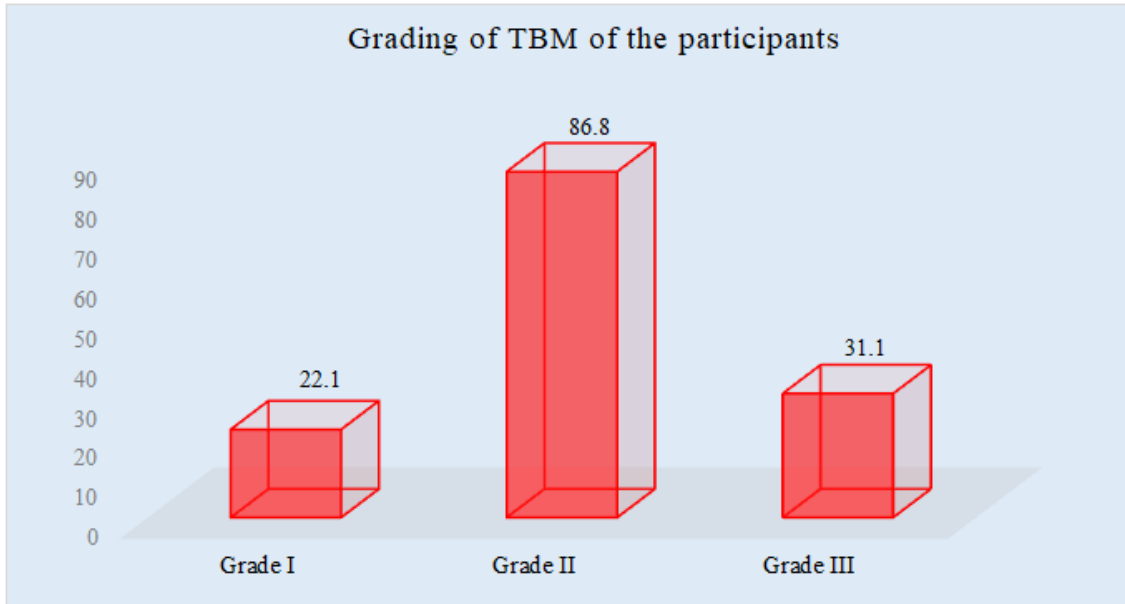


Figure IV: Column chart showed distribution of the participants by grading of TBM, (N=77)

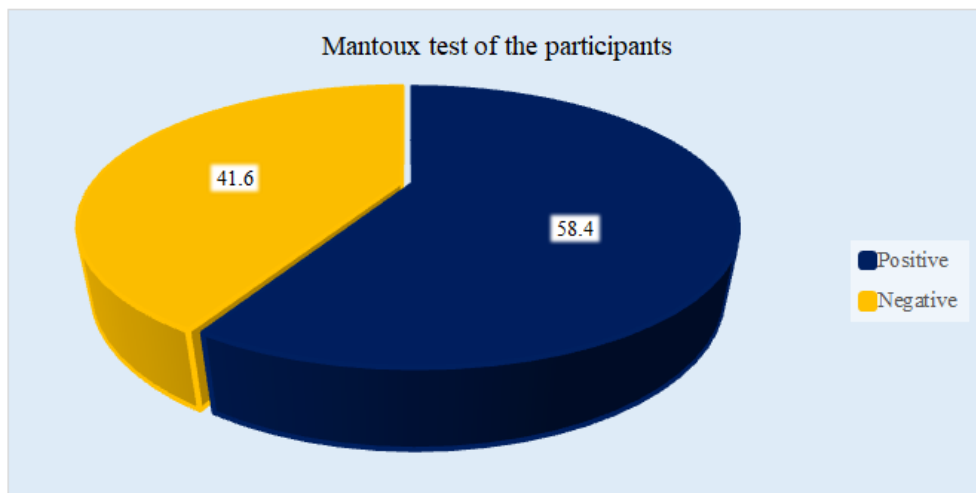


Figure V: Pie chart showed Mantoux test wise participants, (N=77)

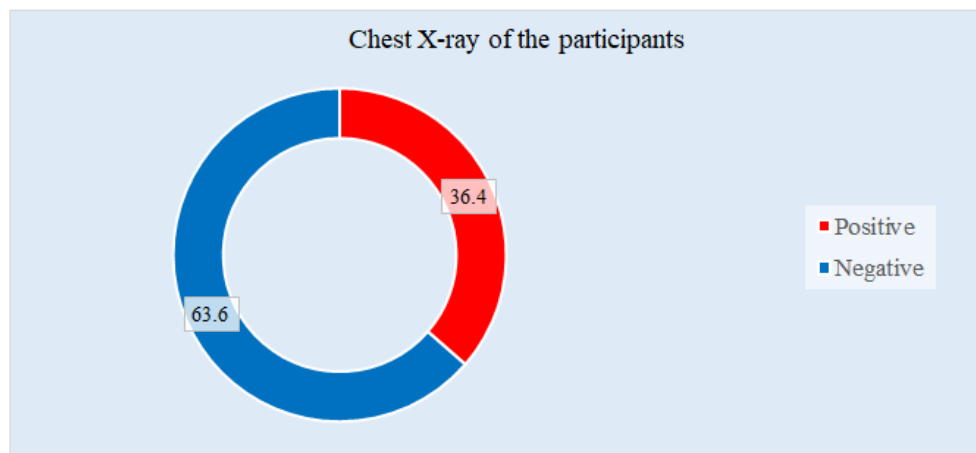


Figure VI: Ring chart showed distribution of the respondents by chest X-ray, (N=77)

## DISCUSSION

This study aimed to make a sociodemographic and clinical profile of tubercular meningitis patients without pulmonary signs and symptoms. The total sample size was 77. In this current study, the majority (40.2%) of the respondents were aged between 31 and 40 years, with a mean age of  $37.93 \pm 11.8$  years. In a previous study conducted in Bangladesh, among 30 patients mean age of the participants was  $35.17 \pm 6.14$  years [11]. In another study, young adults aged between 15 and 30 years have been reported as the group with the highest incidence rate [12]. In our study, the male was predominant, with 53.2%. Previous another study [11] also found similar findings. But another study found an equal distribution of males and females [13]. In this study, during the study period, male cases were admitted slightly higher than female that may be the reason for the higher number of male patients. In our study, the majority (46.8%) of the respondents had TBM Grade II followed by 31.1% had TBM Grade III and 22.1% had Grade I. Another study found 6.3% with grade I, 69.3% with grade II and 24.3% with grade III [14]. All of our patients had fever (100%) and other complaints included headache (80.5%), altered sensation (68.8%), anorexia and nausea (62.3%), vomiting (55.8%), convulsion (19.5%) and neck stiffness (15.6%). A study conducted in Dhaka conducted by Joy *et al.* (2020) [11] found that fever (93%) was the most common symptom noted in all TBM patients, followed by headache and loss of consciousness. Other studies also found similar symptoms as the most frequent among the patients of TBM [7, 15]. In this study, among all the respondents, 36.4% of patients had positive chest X-ray findings for TB, where 42.9% had Apical infiltration, 32.1% had Miliary mottling, 28.6% had Hilar enlargement, 21.4% had pleural effusion, 10.7% had Lower/middle zone infiltration and 7.1% had Acute on chronic TB which was consistent with a previous study [11]. It was observed in this study that 58.4% of patients had the positive Mantoux test. Although the diagnostic practice of the Mantoux test gives much value to the diagnosis of tuberculosis, current reviews suggest that skin testing is probably of limited value, except in infants [16]. All the findings of this current study may be helpful in further similar studies.

### LIMITATION OF THE STUDY

All samples were collected from a single center. The sample size was small and the required number of samples could not be collected due to COVID-19 pandemic situation. CSF culture could not be done for all patients for its higher expenses and unavailability. Moreover, the study was conducted over a very short period. So, the findings of this study may not reflect the exact scenario of the whole country.

## CONCLUSION & RECOMMENDATION

As per the findings of this current study, we can conclude that the prevalence of tubercular meningitis

without pulmonary signs and symptoms among males or service holders or middle-income family members is higher than in other groups. Family history may be a potential factor for such a disease. Fever, headache, altered sensation, anorexia/nausea and vomiting are very common clinical features in tubercular meningitis cases without pulmonary signs and symptoms. To get more specific results, we would like to recommend conducting similar studies in several places with larger-sized samples.

## REFERENCES

- Palacios, C. F., & Saleeb, P. G. (2020). Challenges in the diagnosis of tuberculous meningitis. *Journal of Clinical Tuberculosis and Other Mycobacterial Diseases*, 20, 100164.
- Fatema, K., Rahman, M. M., Akhter, S., Akter, N., Paul, B. C., Begum, S., & Begum, F. (2020). Clinicoradiologic profile and outcome of children with tubercular meningitis in a tertiary care hospital in Bangladesh. *Journal of Child Neurology*, 35(3), 195-201.
- Arshad, A., Dayal, S., Gadhe, R., Mawley, A., Shin, K., Tellez, D., ... & Venketaraman, V. (2020). Analysis of tuberculosis meningitis pathogenesis, diagnosis, and treatment. *Journal of clinical medicine*, 9(9), 2962-2964.
- Thwaites, G. E., Chau, T. T. H., Stepniewska, K., Phu, N. H., Chuong, L. V., Sinh, D. X., ... & Farrar, J. J. (2002). Diagnosis of adult tuberculous meningitis by use of clinical and laboratory features. *The Lancet*, 360(9342), 1287-1292.
- Marx, G. E., & Chan, E. D. (2011). Tuberculous meningitis: diagnosis and treatment overview. *Tuberculosis research and treatment*, 2011, 1-9.
- Thwaites, G. E., & Hien, T. T. (2005). Tuberculous meningitis: many questions, too few answers. *The Lancet Neurology*, 4(3), 160-170.
- Aurangzeb, S., Badshah, M., & Khan, R. S. (2008). Chest radiographic findings in neurotuberculosis without pulmonary signs and symptoms. *J Coll Physicians Surg Pak*, 18(1), 27-30.
- Corral, I., Quereda, C., Navas, E., Martin-Davila, P., Pérez-Elías, M. J., Casado, J. L., ... & Moreno, S. (2004). Adenosine deaminase activity in cerebrospinal fluid of HIV-infected patients: limited value for diagnosis of tuberculous meningitis. *European Journal of Clinical Microbiology and Infectious Diseases*, 23, 471-476.
- World Medical Association. (2001). World Medical Association Declaration of Helsinki. Ethical principles for medical research involving human subjects. *Bulletin of the World Health Organization*, 79(4), 373-374. World Health Organization. <https://apps.who.int/iris/handle/10665/268312>.
- Voigt, P., & von dem Bussche, A. (2017). Enforcement and fines under the GDPR. The EU

- General Data Protection Regulation (GDPR). Springer, Cham, 201-217.
11. Joy, K. N. I., Kundu, N. C., Akhter, M., Hossain, M. Z., Rahman, A. H. M. W., & Rahman, M. M. (2020). Evaluation of the Various Clinical Presentations of Adult CNS Tuberculosis. *Journal of Dhaka Medical College*, 28(1), 76-84.
  12. Hoşoğlu, S., Geyik, M. F., Balik, I., Aygen, B., Erol, S., Aygencel, S. G., Mert, A., Saltoğlu, N., Dökmetaş, I., Felek, S., Sünbül, M., Irmak, H., Aydın, K., Ayaz, C., Kökoğlu, O. F., Uçmak, H., & Satılmış, S. (2003). Tuberculous meningitis in adults in Turkey: epidemiology, diagnosis, clinic and laboratory findings. *European Journal of Epidemiology*, 18(4), 337-343.
  13. Pehlivanoglu, F., Kart Yasar, K., & Sengoz, G. (2012). Tuberculous meningitis in adults: A review of 160 cases. *The Scientific World Journal*, 201(12), 34-37.
  14. Luo, M., Wang, W., Zeng, Q., Luo, Y., Yang, H., & Yang, X. (2018). Tuberculous meningitis diagnosis and treatment in adults: A series of 189 suspected cases. *Experimental and Therapeutic Medicine*, 16(3), 2770-2776.
  15. Yaşar, K., Pehlivanoglu, F., Şengöz, A., & Şengöz, G., (2012). Evaluation of radiological findings in 160 adult patients with tuberculous meningitis. *Turkish Journal of Medical Sciences*, 42(2), 259-267.
  16. Cairns, H., Smith, H. V., & Vollum, R. L. (1950). Tuberculous meningitis. *Journal of the American Medical Association*, 144(2), 92-96.