

Systemic Thrombolysis by Tenecteplase for Severe Pulmonary Embolism

Dr. El Boussaadani Badre, MD^{*}, Benajiba Chakib, Jamila Zarzur, Mohammed Cherti

Department of Cardiology B, Ibn Sina University Hospital, Rabat, Morocco

DOI: [10.36347/sjams.2020.v08i02.047](https://doi.org/10.36347/sjams.2020.v08i02.047)

| Received: 03.02.2020 | Accepted: 10.02.2020 | Published: 22.02.2020

*Corresponding author: Dr. El Boussaadani Badre

Abstract

Original Research Article

Pulmonary embolism (PE) is a common, severe, multi-factorial disease that increases with age, and is one of the leading causes of death, largely due to delayed diagnosis and treatment. It is said to be severe or at high risk if it is associated with hemodynamic instability (arterial hypotension or cardiogenic shock). Thrombolysis is the recommended treatment for severe pulmonary embolism, the particularity of our study is the off-label use of Tenecteplase, a thrombolytic drug widely used in acute coronary syndrome, with results showing efficacy and tolerance compared to other molecules, through a retrospective study conducted in Cardiology B department, between January 2015 and January 2016, involving 3 patients admitted for management of severe pulmonary embolism.

Keywords: Severe pulmonary embolism, thrombolysis, Tenecteplase.

Copyright © 2020: This is an open-access article distributed under the terms of the Creative Commons Attribution license which permits unrestricted use, distribution, and reproduction in any medium for non-commercial use (NonCommercial, or CC-BY-NC) provided the original author and source are credited.

INTRODUCTION

Severe pulmonary embolism is defined by a state of shock or systemic hypotension, clinical criteria testifying to an acute pulmonary heart, it is associated with a mortality approaching 25%.

Thrombolysis is one of the therapeutic means to reduce the mortality of severe pulmonary embolism and remains the first-line treatment. The thrombolytic agents validated in the treatment of PE are streptokinase, urokinase and alteplase [4, 6].

Although tenecteplase does not yet have its MA, it is frequently used as a thrombolytic agent especially in SMUR, the issue that concerns us is the justification for its use.

We will discuss the indications of thrombolysis in severe pulmonary embolism, demonstrating its efficacy and its contribution to early revascularization, as well as the efficacy and safety of tenecteplase in the same way as other thrombolytics, through a series of 3 patients gathered in our formation between June 2015 and December 2015 with a review of the literature.

METHODS

This is a retrospective study conducted in Cardiology B department, between January 2015 and January 2016, involving 3 patients admitted for the management of severe pulmonary embolism. Excluded patients are those who have a contraindication to thrombolysis.

RESULTS

Case-1

56-year-old patient, his cardiovascular risk factors are diabetes under metformin, hypertension under amolodpin, obesity, menopause, admitted to the emergency room for acute chest pain associated with dyspnea stage 3 Clinical examination at admission was normal.

The chest x-ray was normal, the ECG recorded sinus tachycardia at 110 bpm with negative Antero-septal and lower T waves. Biologically, troponin returned negative with positive D-dimer at 1700 ng/ml. A thoracic CT scan (Figure-1) was performed showing proximal bilateral massive pulmonary embolism with signs of the acute pulmonary heart (dilation of the right ventricle).

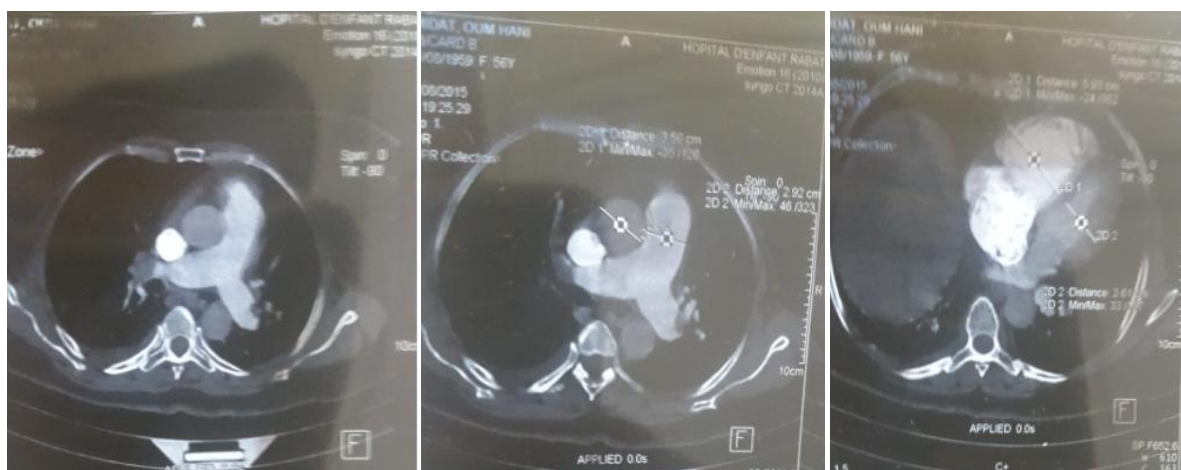


Fig-1: Proximal bilateral massive pulmonary embolism with signs of the acute pulmonary heart (dilation of the right ventricle)

Une anticoagulation curative a base d'HNF a été mise en route. une ETT été réalisé au service ayant montré un ventricule droit dilaté de fonction systolique altérée avec une HTAP à 67mmHg . L'évolution été marqué l'installation brutale d'une détresse respiratoire avec un état de choc (hypotension , sueurs ...). Devant ce tableau d'embolie pulmonaire grave, et après élimination des contre-indications, la patiente a été thrombolysée avec de la ténecteplase à la dose de 0,5 mg/kg. Après 15 min, on constatait une amélioration de l'état clinique de la patiente, avec une PA de 110/60mmHg, une FC à 101 batt /min, une FR à 23/min, SaO₂ à 95% et la disparition des signes de choc , sans complications hémorragiques. La suite de la prise en charge hospitalière s'est faite en secteur clinique avec la mise en route d'un traitement héparinique et relais précoce par anti vitamine K. Un bilan étiologique (echodoppler des MI , marqueurs tumoraux , TDM TAP) a été lancée revenant négatif . La patiente fut adressée en consultation medecine interne pour complément de PEC.

A curative anticoagulation based on UFH was started. an echocardiography was performed in the department that showed a dilated dysfunctional right ventricle with a PAH at 67mmHg. The evolution was marked by the sudden installation of a respiratory distress with a state of shock (hypotension, sweats ...). In view of this severe pulmonary embolism, and after removal of contraindications, the patient was thrombolysed with tenecteplase at a dose of 0.5 mg / kg. After 15 min, there was an improvement in the clinical condition of the patient, with a BP of 110 / 60mmHg, an FC at 101 beats / min, a FR at 23 / min, SaO₂ at 95% and the disappearance of the signs of

shock, without hemorrhagic complications. The continuation of the hospital care was done in clinical sector with the start of a heparin treatment and early relay with anti vitamin K. An etiological assessment (echo-doppler MI, tumor markers, CT TAP) was launched negative return.

Case-2

65-year-old patient, his cardiovascular risk factors: menopause, sedentary lifestyle, with history of surgery for cholecystectomy 17 years ago, having presented a dry cough under symptomatic treatment one week before admission, the evolution was marked, one week later, by the installation of sudden atypical chest pain with NYHA stage 4 dyspnea.

The clinical examination at admission found a patient with polypnoea at 28 c / min, 90% Sp O₂ in ambient air, FC at 100bpm, TA at 100/60 mmHg and on CV examination: a burst of B2 at the pulmonary focus.

After conditioning of the patient, an ECG was performed, showing sinus tachycardia, left deviated axis, aspect S1Q3, BBDt incomplete, under ST in apical-lateral and an above offset in AVR (Figure-2). A performed ETT showing average dilatation of right cavities with severe VD dysfunction, paradoxical septum and 70mmHg PAH.

Chest X-ray was normal, with CT angiography, there was a massive bilateral pulmonary embolism with right-sided cavities and evidence of right heart failure (Figure-3). Biological assessment requested at admission revealed evidence of ventricular pain (high BNP and troponin).

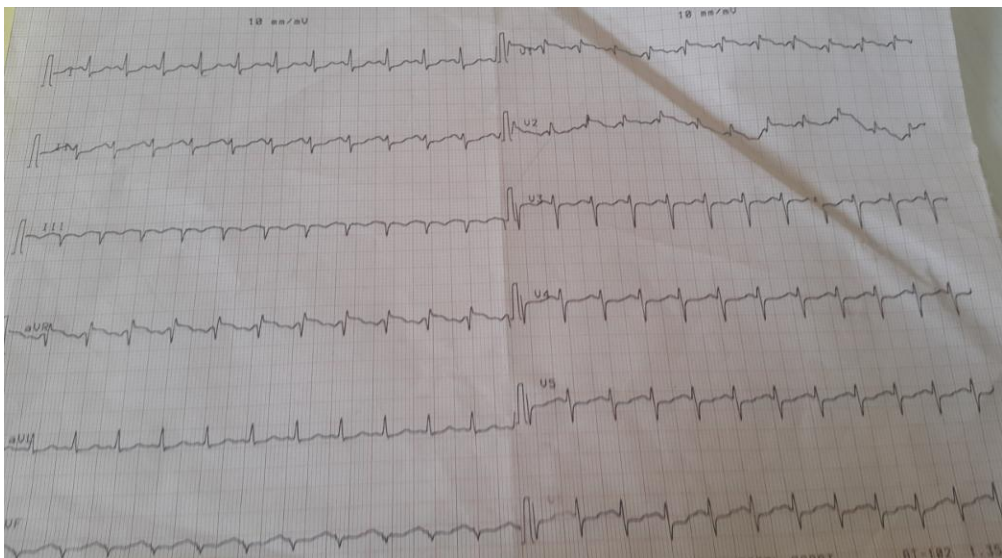


Fig-2: ECG was performed, showing sinus tachycardia, left deviated axis, aspect S1Q3, BBDt incomplete, under ST in apical-lateral and above offset in AVR

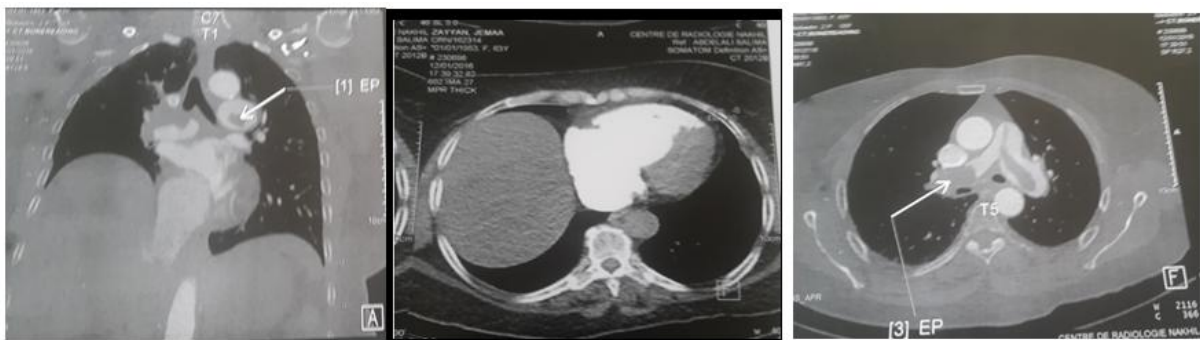

Fig-3: Massive bilateral pulmonary embolism with right-sided cavities and evidence of right heart failure

2 hours after admission to ICU, the patient had prolonged hypotension not responding to filling without signs of shock. After consultation and after removal of contraindications, it was decided to perform thrombolysis with tenekteplase. In 40 minutes the hemodynamic improvement was spectacular, TA at

12/8, SpO2 at 100% under 2l, without hemorrhagic complications. The etiological assessment revealed a deep femoro-popliteal vein thrombosis (Figure-4). The rest of the etiological record was without particularity. The patient was discharged under antivitamin-K, referred to internal medical consultation for follow-up.

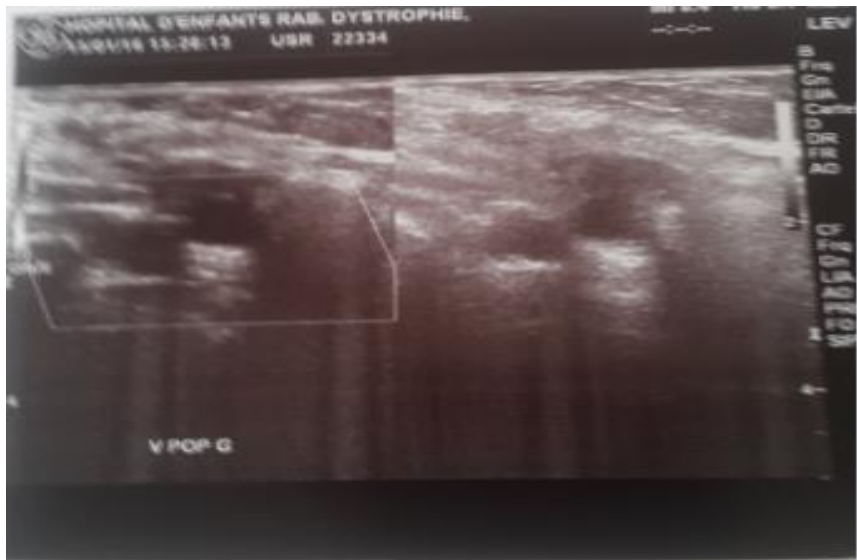

Fig-4: A deep femoro-popliteal vein thrombosis

Case-3

26-year-old female patient, his cardiovascular risk factors: obesity, ATCD: follow-up for a depressive syndrome under antidepressant, admitted in our training for exploration of 2 episodes of syncope with NYHA stage 2 dyspnea. The clinical examination was without particularity, normal biological assessment. The ECG recorded sinus tachycardia at 105 bpm.

An ETT was performed showing signs of acute pulmonary heart with PAH at 70 mmHg. A thoracic CT SCAN was performed showing a proximal bilateral massive pulmonary embolism, the patient was treated with unfractionated heparin. The evolution was marked at day 2 of his hospitalization by the sudden installation of the signs of shock (hypotension, sweats ...). The patient was thrombolized with tenecteplase at a dose of 0.5 mg/kg. with the improvement of his clinical condition one hour later.

The thrombophilia assessment (requested before starting anticoagulants) was positive. The patient was referred to the internal medicine department for additional support.

DISCUSSION

Pulmonary embolism (PE) is defined as the sudden obliteration of the trunk or branch of the pulmonary artery by an embolus. With deep vein thrombosis (DVT), it is the main clinical expression of venous thromboembolism (VTE) [1, 2]. PE is frequent and severe, even though its current mortality is much lower than that of its natural history without anticoagulant (> 25% spontaneous mortality) [3, 4].

PE, which shares the same risk factors as DVT, is a multifactorial disease [5]. Its incidence increases with age [6-8]. His clinical presentation is polymorphic, without pathognomonic sign making his diagnosis difficult. This is why several diagnostic strategies have been developed that combine the prior estimate of clinical probability with biological and radiological examinations [9].

The severity of PE was long judged on pulmonary vascular obstruction. It was considered severe, any PE with vascular obstruction greater than 50%. Old data had, however, shown that clinical tolerance had more prognostic influence than vascular obstruction [10-12].

The management of pulmonary embolism is based on the assessment of the risk of early mortality (intra-hospital or at 1 month). This risk stratification, which has important therapeutic implications, is primarily based on the presence or absence of clinical signs of shock or hemodynamic instability that defines high-risk pulmonary embolism (5% of patients) (grade IB). For hemodynamically stable patients ("non-high risk" patients), it is necessary to use the PESI score (or the simplified PESI score – Figure-5) to distinguish intermediate-risk emboli (PESI \geq III or sPESI = 1), low-risk emboli (PESI \leq II or sPESI = 0) (grade IIa B) [13]. Troponin determination or evaluation of right ventricular dilation (echocardiography or CT angiography) is only justified for intermediate-risk embolism (grade IIa B). Thus, high-risk intermediate embolisms defined by the combination of right ventricular dysfunction and elevation of troponin, low-risk intermediate embolisms defined by the presence of one or the other of these criteria are distinguished [13].

Table-1: Original and simplified Pulmonary Embolism Severity Index (1 , 16)

Parameter	Original version ²²⁶	Simplified version ²²⁹
Age	Age in years	1 point (if age >80 years)
Male sex	+10 points	–
Cancer	+30 points	1 point
Chronic heart failure	+10 points	1 point
Chronic pulmonary disease	+10 points	
Pulse rate \geq 110 b.p.m.	+20 points	1 point
Systolic BP <100 mmHg	+30 points	1 point
Respiratory rate >30 breaths per min	+20 points	–
Temperature <36°C	+20 points	–
Altered mental status	+60 points	–
Arterial oxyhaemoglobin saturation <90%	+20 points	1 point

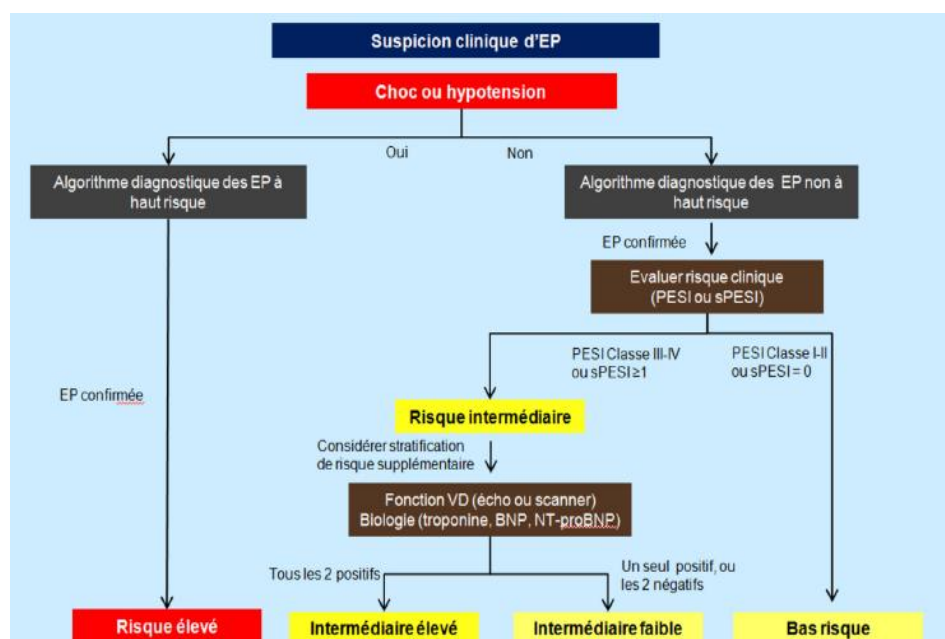


Fig-5

Pulmonary embolisms responsible for hypotension lasting more than 15 minutes or by peripheral signs of shock are considered serious and require appropriate and rapid therapeutic management with initial conditioning of the patient (hemodynamic and venous monitoring, oxygen therapy) / mechanical ventilation, volume expansion, inotropic and vasoactive drugs..).

Systemic thrombolysis remains the first-line treatment for high-risk (IB, ESC 2014) or intermediate-risk embolism with clinical signs of haemodynamic degradation (rescue thrombolysis, IIa B, ESC 2014). It allows for faster restoration of pulmonary perfusion than unfractionated heparin [13].

Early resolution of pulmonary obstruction results in a rapid decrease in pulmonary pressures and resistances that improves right ventricular overload. In fact, a decrease in pulmonary arterial resistance and an improvement of the ultrasound parameters are observed from the first hour of treatment, whatever the thrombolytic agent used, whereas it is necessary to wait at least 24 hours to observe this effect related to the physiological fibrinolysis, under UFH [14].

However, this difference disappears after 15 days of treatment. It is therefore in the initial phase of the management of severe PE, at best within 48 hours of diagnosis, that fibrinolytic therapy should be initiated.

Thrombolysis is associated with reduced mortality and recurrence in patients with hemodynamic instability [15, 16]. A recent epidemiological report reports a reduction of hospital mortality in hemodynamically unstable PE patients treated with

thrombolysis [(RR = 0.20 (0.19-0.22)]. In this context, all contraindications must be considered relative.

The different regimens of thrombolysis are reported in Table-2. Short infusions of alteplase are now preferred over prolonged infusions of first-generation thrombolytic agents. Although evaluated in pilot studies, tenecteplase (thrombolytic used in our patients) does not have the MA in acute pulmonary embolism. Tenecteplase, a mutant form of alteplase, has superior efficacy in the treatment of myocardial infarction [17, 18]. Its characteristics are a single bolus injection, a long half-life, superior fibrin specificity and rapid fibrinolytic capacity.

Several clinical cases reported in the literature have described its use in the treatment of severe pulmonary embolism; in 2002, David Caldicott *et al.* Described as the first report of the successful use of tenecteplase in the treatment of an elderly patient with severe pulmonary embolism [19].

Boursier and *al.* reported a case of severe shock related to a suspicion of pulmonary embolism with a favourable course after thrombolytic administration in the pre-hospital setting and used tenecteplase as the only thrombolytic agent present at the SMUR [20]. Clement *et al.*, when they reported the case of a woman with massive pulmonary embolism, tenecteplase was chosen because of her hemodynamic state; the other therapeutic alternatives to massive PE, namely surgical embolectomy and catheter embolectomy, were not feasible because they were not available on-site or nearby, and allowed the rapid restoration of a very precarious haemodynamic state initially at the cost of bleeding complications. Only extra-cranial supported conventionally [21].

Cecilia Becattini *et al.*, report that tenecteplase is more effective than heparin in achieving a rapid hemodynamic reduction of RVD in patients with PE and that the results are consistent with those observed with other thrombolytic agents that were more effective than heparin [22].

Andrew Connor, Parth Narendran *et al.*, they reported the case of a patient with severe pulmonary embolism, thrombolized with tenecteplase, his symptomatology improved within 4 hours after thrombolysis with a decrease in his pulse, improvement of his blood pressure, evolution at the ECG and echocardiography have also been noted [23]. Pierre-Claver Hounkpe *et al.*, reported the case of a 59-year-old obese woman with a mitral mechanical protector, admitted to intensive care at the National University Hospital of Cotonou for severe pulmonary embolism and benefited from thrombolysis with tenecteplase in whom the clinical picture has improved rapidly [24]. Another study conducted at HMIMV; 5 patients were thrombolized with tenecteplase, 4 had a good evolution [25].

The PEITHO study, published in 2014 [26], concluded the discussion on the effectiveness of thrombolysis in pulmonary embolism without hemodynamic instability with high intermediate risk, showing a decrease in mortality and mortality. Recurrence rate in thrombolized patients, but with a higher rate of bleeding complications. This study did not provide clear recommendations for the use and authorization and marketing of tenecteplase (thrombolytic used in the study) as a gold standard for severe pulmonary embolism at the same time as the alteplase.

The use of "in situ" thrombolysis with an ultrasound catheter may also be a therapeutic alternative in case of failure or contraindication to systemic thrombolysis in severe pulmonary embolism (IIa C, ESC 2014), and may even be indicated as first-line in high-risk intermediate pulmonary embolism with high bleeding risk (IIb B, ESC 2014).

Contraindications (Table-3) or failures of thrombolysis justify surgical embolectomy or percutaneous thrombectomy (I see, ESC 2015). They are conceived in an appropriate environment, must be the subject of a multidisciplinary decision and be carried out by experienced teams.

CONCLUSION

Tenecteplase was effective in our patients and without hemorrhagic complications. Pending large-scale prospective studies to evaluate the efficacy and risk of tenecteplase haemorrhage in severe pulmonary embolism, our observations and cases reported in the literature suggest that thrombolysis by tenecteplase

would have comparable efficacy and tolerance to other molecules.

Conflicts of interest: The authors do not declare any conflict of interest.

REFERENCES

- Galanauda JP, Blanchet-Deverlyb A, Pernodc G, Quéréa I. Pour le Collège des enseignants de médecinevasculaire (CEMV): Management of pulmonary embolism: A 2015 update. *Journal des Maladies Vasculaires*, 2015.
- Galanaud JP, Messas E, Blanchet-Deverly A, Quéré I, Wahl D, Pernod G. Management of venous thromboembolism: A 2015 update. *La Revue de medecine interne*. 2015 Nov;36(11):746-52.
- Oger E, EPI-GETBO study group. Incidence of venous thromboembolism: a community-based study in Western France. *Thrombosis and haemostasis*. 2000;83(05):657-60.
- Barritt DW, Jordan SC. Anticoagulant drugs in the treatment of pulmonary embolism. A controlled trial. *Lancet*, 1960;1:1309-1312.
- Mismetti P, Baud JM, Ferrari E, Galanaud JP, Girard P. Recommandations de bonne pratique: prévention et traitement de la maladie thromboembolique veineuse en médecine. *Journal des maladies vasculaires*. 2010;35(3):127-36.
- Meyer G, Sanchez O. Embolie pulmonaire; EMC-Anesthésie Réanimation 1, 2004; 54-68.
- Le Gal G, Righini M, Mottier D. La clinique de l'embolie pulmonaire: décidément difficile. *La Revue de médecine interne*. 2007 Jun 1;28(6):394-399.
- Lucena J, Rico A, Vázquez R, Marín R, Martínez C, Salguero M, Miguel L. Pulmonary embolism and sudden-unexpected death: Prospective study on 2477 forensic autopsies performed at the Institute of Legal Medicine in Seville. *Journal of forensic and legal medicine*. 2009 May 1;16(4):196-201.
- Huisman MV, Klok FA. Diagnostic management of acute deepvein thrombosis and pulmonary embolism. *Journal Thromb Haemost*, 2013;11:412-422.
- Alpert JS, Smith R, Carlson J, Ockene IS, Dexter L, Dalen JE. Mortality in patients treated for pulmonary embolism. *JAMA*, 1976;236:1477-80.
- Goldhaber SZ, Visani L, De Rosa M. Acute pulmonary embolism: clinical outcomes in the International Cooperative Pulmonary Embolism Registry (ICOPER). *Lancet*, 1999;353: 1386-9.
- Vieillard-Baron A, Page B, Augarde R, Prin S, Qanadli S, Beauchet A, Dubourg O, Jardin F. Acute cor pulmonale in massive pulmonary embolism: incidence, echocardiographic pattern, clinical implications and recovery rate. *Intensive care medicine*. 2001 Sep 1;27(9):1481-6.

13. Zamorano JL, Achenbach S, Baumgartner H, Bax JJ, Bueno H, Dean V, Çetin Erol CD, Fagard R, Ferrari R, Hasdai D. ESC Guidelines on the diagnosis and management of acute pulmonary embolism. The Task Force for the Diagnosis and Management of Acute Pulmonary Embolism of the European Society of Cardiology (ESC) Endorsed by the European Respiratory Society (ERS). *Eur Heart J*. 2014 Nov 14;35(43):3033-73.
14. Aujesky D, Perrier A, Roy PM, Stone RA, Cornuz J, Meyer G, Obrosky DS, Fine MJ. Validation of a clinical prognostic model to identify low-risk patients with pulmonary embolism. *Journal of internal medicine*. 2007 Jun;261(6):597-604.
15. Meneveau N, Coeur-Poumon P, Jean-Minjoz H. Centre hospitalier universitaire, boulevard Fleming, 25030 Besançon, France New ESC guidelines in acute pulmonary embolism: Anticoagulation and thrombolytic treatment. *Arch Mal Coeur Vaiss Prat*, 2015:8-15.
16. Planquette B, Belmont L, Meyer G, Sanchez O. Update on diagnosis and treatment of high-risk pulmonary embolism. *Revue des maladies respiratoires*. 2011 Jun;28(6):778-89.
17. Goldhaber SZ, Come PC, Lee RT, Braunwald E, Parker JA, Haire WD, Feldstein ML, Miller M, Toltzis R, Smith JL, de Silva AT. Alteplase versus heparin in acute pulmonary embolism: randomised trial assessing right-ventricular function and pulmonary perfusion. *The Lancet*. 1993 Feb 27;341(8844):507-11.
18. Wan S, Quinlan DJ, Agnelli G, Eikelboom JW. Thrombolysis compared with heparin for the initial treatment of pulmonary embolism: a meta-analysis of the randomized controlled trials. *Circulation*. 2004 Aug 10;110(6):744-9.
19. Agnelli G, Becattini C, Kirschstein T. Thrombolysis vs heparin in the treatment of pulmonary embolism: a clinical outcome-based meta-analysis. *Archives of internal medicine*. 2002 Dec 9;162(22):2537-41.
20. Mostafa A, Briasoulis A, Telila T, Belgrave K, Grines C. Treatment of massive or submassive acute pulmonary embolism with catheter-directed thrombolysis. *The American journal of cardiology*. 2016 Mar 15;117(6):1014-20.
21. Tazarourte K, Imbernon C, SAMU LG. Thrombolyse pré-hospitalière: modalités pratiques. Récupéré sur [http://www.mapar.org/article/pdf/314/Thrombolyse% 20pr% C3.2001;83:C4](http://www.mapar.org/article/pdf/314/Thrombolyse%20pr%C3.2001;83:C4).
22. Van De Werf F, Adgey J, Ardissino D, Armstrong PW, Aylward P, Barbash G, Betriu A, Binbrek AS, Califf R, Diaz R, Fanebust R. Assessment of the Safety and Efficacy of a New Thrombolytic (ASSENT-2) Investigators. Single-bolus tenecteplase compared with front-loaded alteplase in acute myocardial infarction: the ASSENT-2 double-blind randomised trial. *Lancet*. 1999;354(9180):716-22.
23. Caldicott D, Parasivam S, Harding J, Edwards N, Bochner F. Tenecteplase for massive pulmonary embolus. *Resuscitation*. 2002 Nov 1;55(2):211-3.
24. Boursier F, Maistre JP, Sadedine M, Pernot T, Adnet F. Thrombolyse préhospitalière d'une embolie pulmonaire avec état de choc sévère. In *Annales francaises d'anesthésie et de reanimation* 2004 Dec 1;23(12):1182-1184.
25. Clement D, Loyant R, Labet T. Ténecteplase et embolie pulmonaire massive. In *Annales francaises d'anesthésie et de reanimation*, 2004;4(23):440-441.
26. Becattini C, Agnelli G, Salvi A, Grifoni S, Pancaldi LG, Enea I, Balsemin F, Campanini M, Ghirarduzzi A, Casazza F, TIPES Study Group. Bolus tenecteplase for right ventricle dysfunction in hemodynamically stable patients with pulmonary embolism. *Thrombosis research*. 2010 Mar 1;125(3):e82-e86.
27. Connor A, Narendran P, Contractor H, Griffin J, Johnson A. Radiological and electrocardiographic changes following thrombolysis for acute pulmonary embolism with haemodynamic compromise. *Resuscitation*. 2006 Mar 1;68(3):315-317.
28. Pierre-Claver H, Francis MD, Moutawakilou GA, Luc Magloire O, Dominique A, Kémoko OB. Cardiorespiratory arrest due to mechanical mitral valve thrombosis: recovery and successful late thrombolysis in the Intensive Care Unit at the National Teaching Hospital of Cotonou. *Journal of Medicine and Medical Sciences*, 2012;3(4):200-204.
29. Youssouf Seid H. *La thrombolyse dans l'embolie pulmonaire grave aux urgences à propos de 05 cas* (Doctoral dissertation).
30. Meyer G, Vicaut E, Danays T, Agnelli G, Becattini C, Beyer-Westendorf J, Bluhmki E, Bouvaist H, Brenner B, Couturaud F, Dellas C. Fibrinolysis for patients with intermediate-risk pulmonary embolism. *N engl j med*. 2014 Apr 10;370:1402-1411.