

## Degeneration of Verneuil Disease into Squamous Cell Carcinoma: About 4 Cases

S. Sylla<sup>1\*</sup>, O. E. Atiqui<sup>1</sup>, C. E. Fifatin<sup>1</sup>, M. Sahir<sup>1</sup>, K. Benlaguid<sup>1</sup>, M. Marzak<sup>1</sup>, M. D. Amrani<sup>1</sup>, Y. Benchamkha<sup>1</sup>

<sup>1</sup>Department of Plastic, Reconstructive and Aesthetic Surgery

DOI: [10.36347/sasjs.2023.v09i09.002](https://doi.org/10.36347/sasjs.2023.v09i09.002)

| Received: 22.07.2023 | Accepted: 29.08.2023 | Published: 02.09.2023

\*Corresponding author: S. Sylla

Department of Plastic, Reconstructive and Aesthetic Surgery

### Abstract

### Case Series

Hidrosadenitis suppurativa, or Verneuil's disease, is quite common, especially in men in our context, but is often unrecognized. Degeneration of Verneuil's disease into squamous cell carcinoma remains the most dreaded complication. Clinical manifestations include painful and inflammatory nodular lesions evolving chronically towards suppuration and fistulization in areas bearing apocrine glands. The most frequent localization in our context was in the gluteal and/or intergluteal area, and the diagnostic method remains biopsy. Treatment is multidisciplinary, both medical and surgical: above all, wide and appropriate excisions. Depending on the extent of malignancy, oncology is often called in. Preventive surgical excision remains the best preventive treatment, with rigorous long-term monitoring to avoid any fatal evolution.

**Keywords:** Verneuil disease, Degeneration, squamous cell carcinoma.

Copyright © 2023 The Author(s): This is an open-access article distributed under the terms of the Creative Commons Attribution 4.0 International License (CC BY-NC 4.0) which permits unrestricted use, distribution, and reproduction in any medium for non-commercial use provided the original author and source are credited.

## I-INTRODUCTION

Hidradenitis suppurativa is a chronic inflammatory disease of the pilosebaceous follicles in areas with apocrine glands (armpits, peri-genital area and buttocks). It was first described by Velpeau in 1839, then by Verneuil in 1854.

The course of the disease is chronic, recurrent and extensive, with a very rare rate of comorbidity, although the long progression of the disease can lead to various complications, one of which is degeneration into squamous cell carcinoma, first reported by Anderson in 1958 [1].

It is characterized by the appearance of nodular, inflammatory, painful lesions that progress chronically towards suppuration and fistulization. These lesions are located in areas of the body where apocrine glands are present: axillary folds, perineal and inguinal regions, submammary folds [2].

The kinetics of the progression of inflammation are debated the majority of authors are either for a primary involvement of the pilosebaceous apparatus with secondary extension to the apocrine glands. The initial lesion would be a follicular hyperkeratosis leading to occlusion, inflammation and abscessation.

Histological arguments in favor of this theory: predominance of poral occlusion and folliculitis lesions, while sebaceous excretion remains normal.

Clinical arguments: the severity of lesions in areas where there are few apocrine glands, such as the perineal and peri-genital regions, and the association with follicular pathologies such as acne tetrad [2].

The infectious origin is the most debated. Germs found in half of all cases include *Staphylococcus aureus* *meti-S*, *Staphylococcus epidermis*, *Streptococcus milleri* and often *Enterobacter cloacae*.

Chronic evolution is marked by complications, mainly superinfections, the most serious of which are indurations, erysipelas or necrotizing fasciitis, abscesses and fistulizations in neighboring organs (urethra, bladder, rectum, peritoneum). Degeneration into squamous cell carcinoma, classically described, is rare [3].

We present 4 cases of degeneration into squamous cell carcinoma.

## II- CASE REPORTS

### First Case

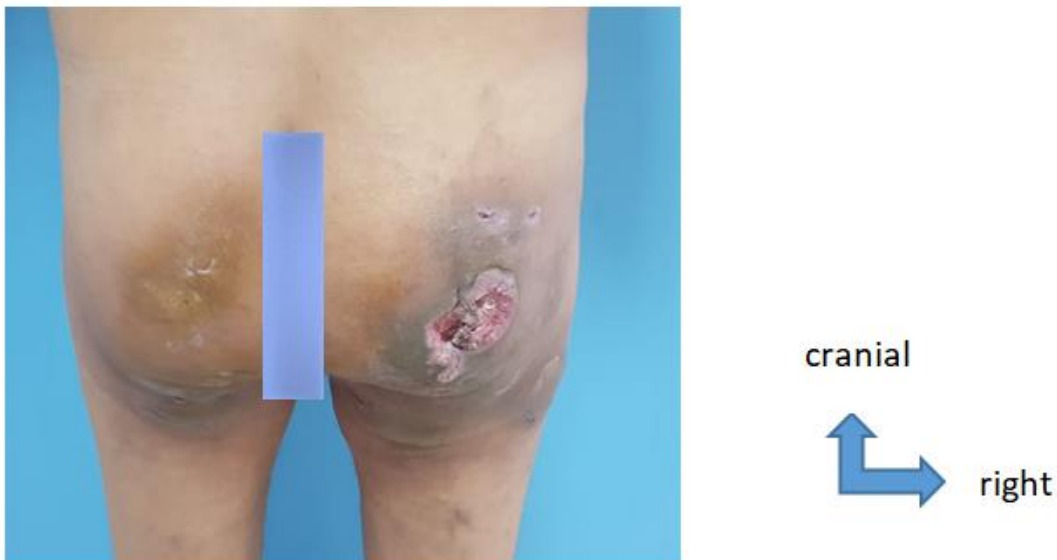Patient aged 66, chronic smoker, followed by dermatologists for 15 years for Verneuil's disease, the onset of which was marked by the appearance of a nodule on the right buttock that became complicated 2 years ago by ulceration with the appearance of other nodules progressively increasing in size, reaching the contralateral buttock and then fistulization.

Following a biopsy suggestive of moderately differentiated, infiltrative EC, the patient was referred to our department for further management. Clinical examination revealed an indurated, ulcerated lesion on the right buttock with multiple nodules on both buttocks. Bacteriological cultures revealed *Enterobacter Cloacae*, multi-sensitive to C3G, Penemes, quinolones and aminoglycosides. Mycological examination negative.

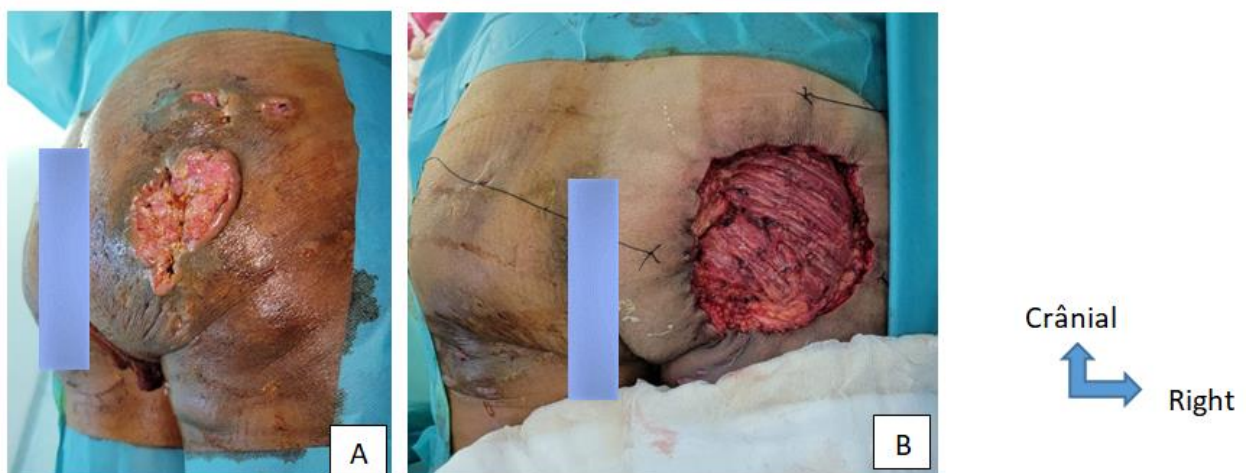
Clinical examination revealed an indurated, ulcerated lesion on the right buttock with multiple nodules on both buttocks (Figure 1).

CT scan of the hip Subcutaneous thickening over the fascia, irregular right buttock region, locally infiltrating, associated with suspicious bilateral inguinal adenopathies (Figure 4).

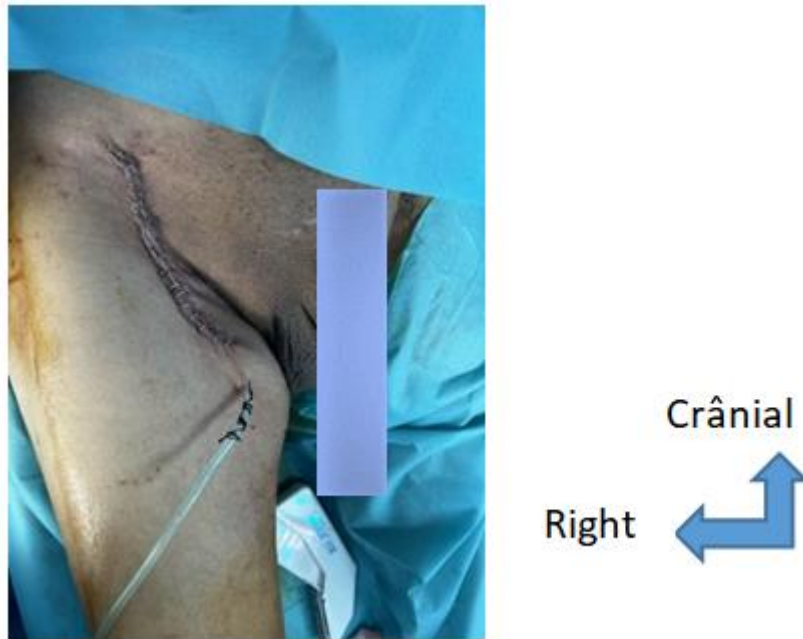
Negative extension studies, presence of bilateral sub-centimetre inguinal adenopathies. Patient underwent wide monobloc tumour resection in the gluteal region, followed by lymph node biopsy with a positive lymph node on anatomopathological study, followed by right lymph node dissection. The loss of tissue was left to heal under direction and then grafted. Follow-up was straightforward.



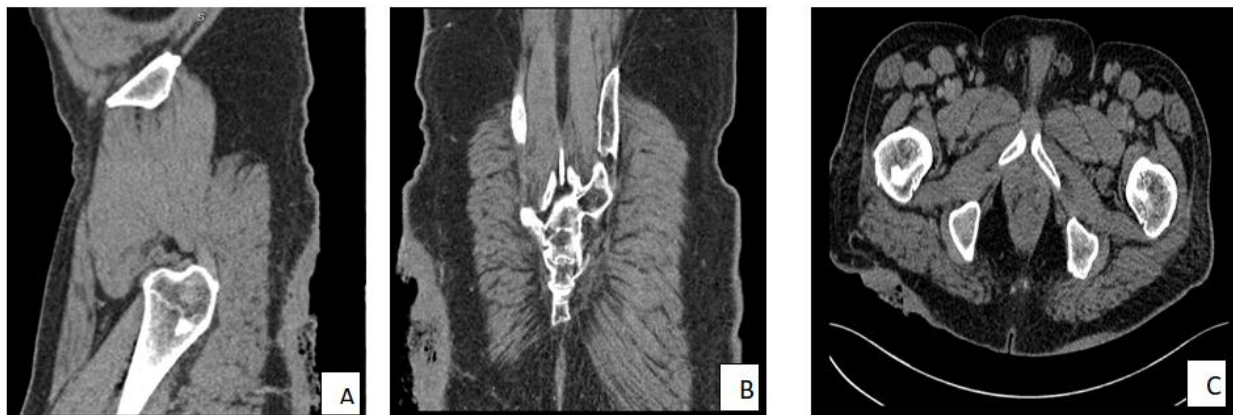**Figure 1: Preoperative appearance (patient standing) Indurated and ulcerated lesion on the right buttock**



**Figure 2: Intraoperative appearance. Patient in prone position (PP), A: Indurated, ulcerated lesion on right buttock, B: Post-exeresis loss of substance (LOS)**



**Figure 3: Intraoperative appearance. Right inguinal curage Patient supine**



**Figure 4: CT scans showing irregular, locally infiltrating subcutaneous thickening over the fascia of the right gluteal region; A: sagittal section; B: frontal section; C: axial section**

**Second Case**

66-year-old patient, chronic smoker, type 2 diabetic on ADO for 13 years, coronary artery disease followed for 07 years.

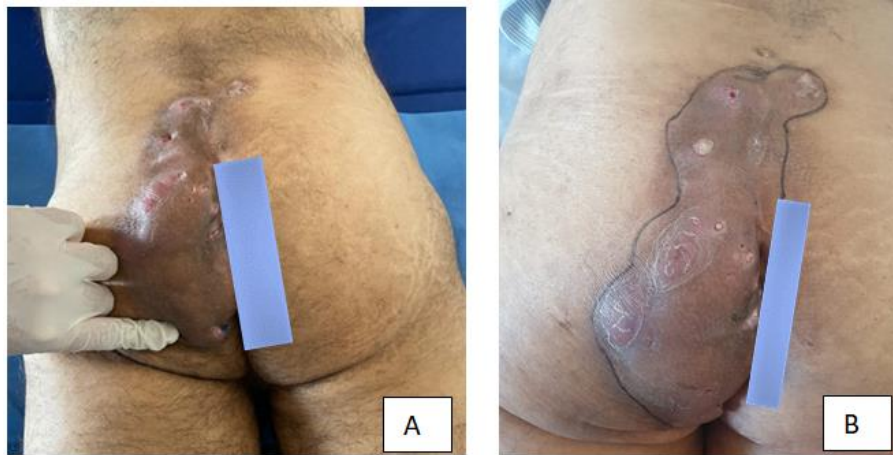
Onset 25 and a half years ago with the appearance of a painful nodule in the perineal area, hot, red and growing, the evolution was marked by extension and the appearance of a purulent collection, the patient was followed in a private structure, put on ATB without improvement.

Referred to our department for further management. Examination revealed an indurated placard in the gluteal region with fistulae on an erythematous background.

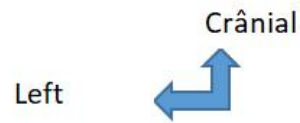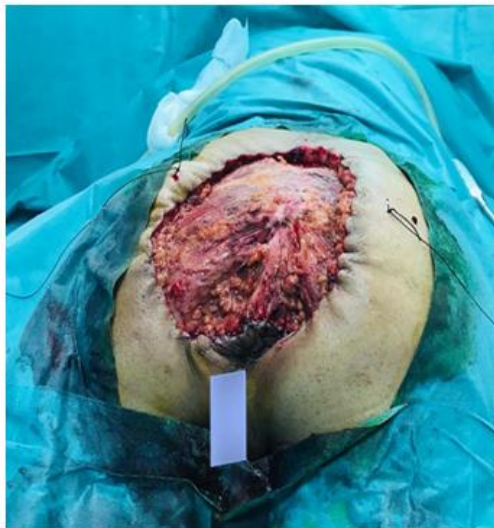Serology negative; Locoregional CT evoked cutaneous and subcutaneous infiltration extending deep into the sacro-coccygeal region, without bone lysis (Figure 5).

Anatomopathology revealed a papillomatous lesion with leukoplakia developed over a highly probable Verneuil's disease; the morphological appearance did not allow us to rule out a verrucous squamous cell carcinoma.

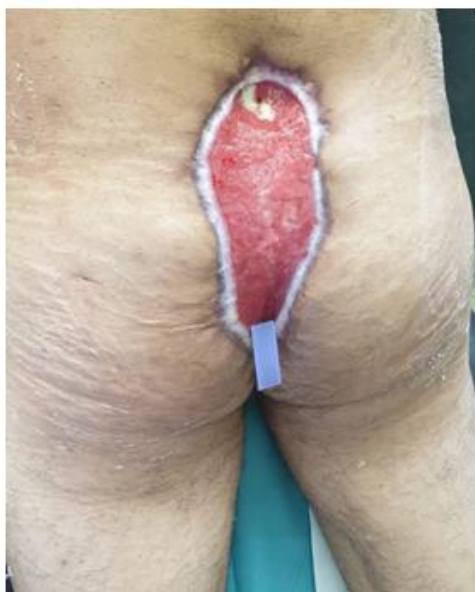Patient underwent wide monobloc tumour resection in the gluteal and sacrococcygeal region. The loss of substance was left to heal in a controlled manner and subsequently grafted. Follow-up was straightforward.



**Figure 5: Preoperative appearance, PP; A: Indurated placard, gluteal region with fistulae on erythematous background; B: Dermographic pen tracing the limits of the erythematous background**



**Figure 6: Intraoperative appearance. Patient in prone position, post-operative LOS**



**Figure 7: Postoperative appearance at d45 Patient in prone position**

**Case 3**

Patient aged 53, with a history of chronic smoking with 6 PA. Operated on for a post-traumatic fracture of the right leg 20 years ago. Initially hospitalized in the dermatology department for ulcerated and fistulized nodular lesions of the gluteal region 6 years prior to admission, diagnosed with Verneuil's disease complicated by squamous cell carcinoma, then referred to our department for further management. Skin examination revealed multiple nodular lesions covering the gluteal region bilaterally and asymmetrically, taking up the entire left buttock and the lower half of the right buttock, with a hard consistency.

Presence of multiple fistula orifices with pus discharge on pressure. Central ulceration measuring 3\*3.5 cm, covered with fibrin and hard edges. Opposite skin is purplish, with ichthyosiform scales on the inner surface of both thighs (Figure 8).

Serological tests negative, Histologically, 2 biopsies: -skin biopsy at ulceration site: undifferentiated, infiltrating squamous cell carcinoma-Skin biopsy of a nodule: dense polynucleated inflammatory infiltrate intensifying in the adnexal glands, compatible with Verneuil disease.

Bacteriological study on biopsy suggested vancomycin-sensitive Enterococcus Faecium. Testicular

ultrasound: bilateral inguinal testicular ectopia; bilateral testicular hypertrophy; significant thickening and infiltration of scrotal envelopes in the process of collection.

Thoracoabdominal CT: mediastinal lymph nodes visible in Baret's lodge, precarinal and PAF, sub- and juxtaposed in size.

Centimetric, the largest measuring 10 mm in minor axis (FAP). Lesional process in the gluteal region, extending perianally and down to the rectum, locally infiltrating and associated with bone lysis, inguinal and sacral ADPs. Anteriorly, this process infiltrates the peri-anal region, with the internal and external sphincter, and the levator ani muscles, with loss of the separating fatty border.

It is responsible for bone lysis of the ischium. Anteriorly and superiorly: it also comes into contact with the lower rectum, with regular circumferential parietal thickening, measuring 14.5 mm in maximum thickness.

Laterally: this process infiltrates the gluteal muscles, with thickening of the skin and infiltration of the subcutaneous fat opposite. Posteriorly, it comes into contact with the coccyx, with local bone lysis (Figure 9). The patient benefited from a clean colostomy. Oncology department opinion: Palliative chemotherapy.

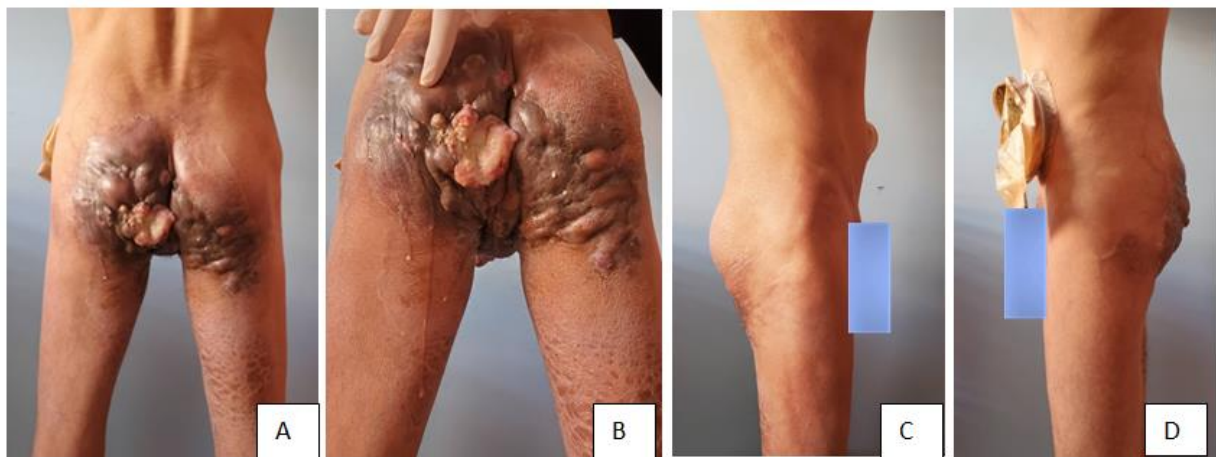
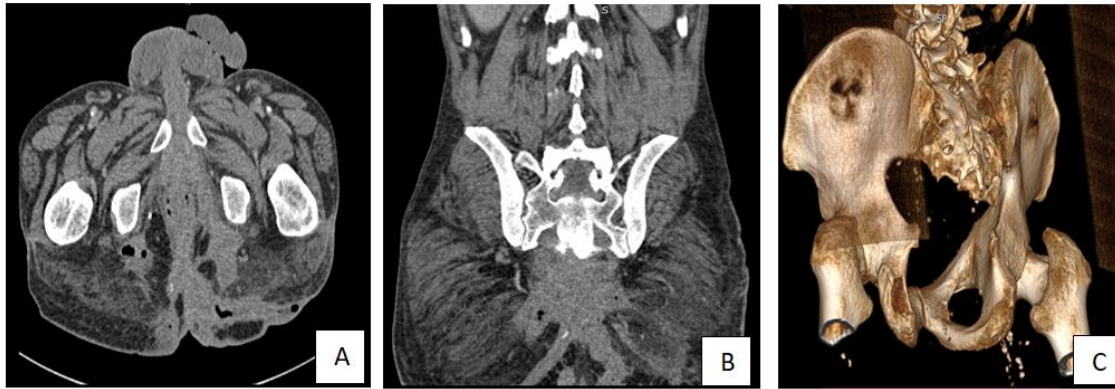
Figure 8 Chronic hidradenitis suppurativa, patient in standing position

ABD: multiple nodular lesions of the gluteal region, bilaterally ulcerated and fistulous

A, B  
C, D  
C: standing and right lateral  
D: standing and right lateral  
Crânial  
Left



**Figure 9: CT scans Lesional process in the gluteal region, extending to the peri-anal region and lower rectum with infiltration and bone lysis; A: Axial section B: Frontal section C: 3D section**

**Fourth Case**

Patient aged 26, operated on at 02 months for Spina Bifida Presented to our department with a lesion on the left buttock, painful and pruritic with pus discharge, resulting in a loss of substance in the area that had been progressively increasing in volume for 03 years. Examination in the department revealed ulcerated, nodular and vegetating lesions on the intergluteal fold and left buttock (Figure 10).

Proctological examination was suggestive of Verneuil disease. Biopsy suggested a moderately differentiated squamous cell carcinoma infiltrating the superficial dermis, serology negative and mycological study negative.

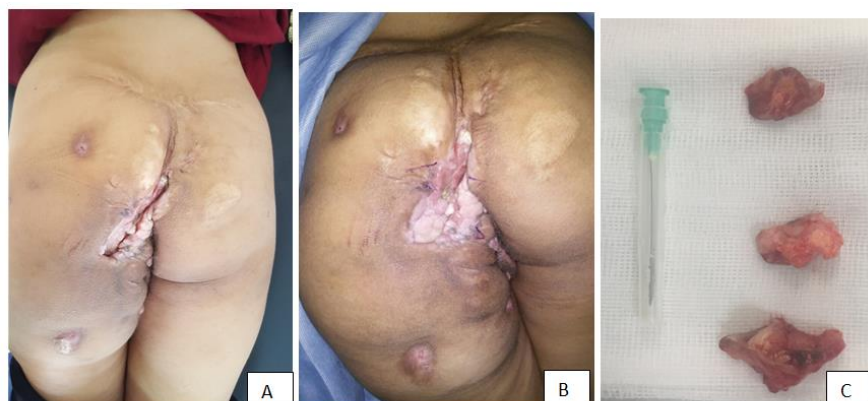
Abdominopelvic CT: Persistence of the voluminous perineal and perianal tissue lesion measuring 83x46 mm and extending over 80 mm, responsible for infiltration with filling of the anal canal. It is responsible for infiltration of the intergluteal fold, perineal fat with the presence of a fistulous path and a large loss of substance at the cutaneous margins; anteriorly, it is responsible for filtration of the vaginal

orifice with endometrial retention upstream and of the urethra, and extends to the anterior parietal cutaneous fat. Posteriorly, it extends to the gluteal regions and engages the coccyx, which appears deformed without individualized bone lysis, It is also responsible for infiltration of the ischial and rectal fossae, especially on the left, as well as the levator ani muscles.

A nodular lesion measuring 10x16 mm, oval in shape and regular in outline, is present in the left gluteal region. Presence of a lumbosacral spina bifida with myelomeningocele and inserted low cord.

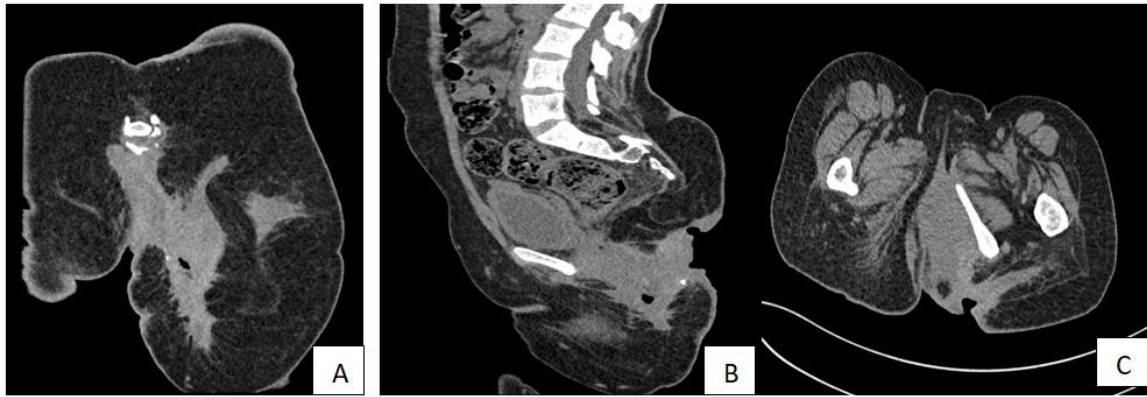
Persistent voluminous left hypogastric adenopathy with extensive necrosis, currently measuring 27 × 36 mm20mm short axis.

Multiple bilateral inguinal adenopathies, the largest measuring 20 mm in minor axis (Figure 11). The patient benefited from a clean colostomy. Oncology advice was to start the patient on palliative chemotherapy based on 5 FU CDDP/3 courses, followed by evaluation.



Crânial  
 Left

**Figure 10: PP patient; A, B: ulcerated, nodular and vegetative lesions on the gluteal fold and left buttock; C: biopsy for anatomopathological and mycological study**



**Figure 11: CT scan, large pelvic-perineal infiltrating mass with loss of skin substance; A: frontal section B: sagittal section C: axial section**

## DISCUSSION

Degeneration of Verneuil disease into squamous cell carcinoma remains the most serious complication. Since its first description by Anderson in 1958 [4], and Jackman in 1959 [4]. Several cases have been reported in the literature. Without explanation, this complication occurs only in perineal, peri-anal and gluteal localizations of Verneuil disease.

In the literature, there are debatable data on the malignant transformation of hidrosadenitis suppurativa into CSC, alongside chronic states of inflammation, which provide a favorable environment for oncogenesis through dysregulation of tumor suppressor genes and self-sustained growth, leading to genetic diseases.

There are many other factors involved, such as obesity and smoking, which contribute to the incidence and severity of the disease and are associated with malignant transformation [5]. Furthermore, Lavogiez *et al.*, [6] have reported the involvement of HPV-16 infection in degeneration. In our study, 3 of our patients were chronic smokers and HPV infection was not investigated. This Verneuil disease degeneration is characterized by its long-term evolution, in our context

the age of evolution was between 3-25 years with one case associated with a lumbosacral spina bifida with myelomeningocele and congenital inserted low cord in a 26-year-old patient. This evolutionary age is comparable to those of Talmat JC *et al.*, [3], whose average time to degeneration in Verneuil disease is 20 years, with extremes ranging from 3 to 50 years. He disease seems to spread like wildfire over a region totally remodeled by chronic fistulas, spreading very rapidly and leaving the patient little chance. Metastatic progression occurs at an early stage [7]. Squamous cell carcinomas appear to be much more aggressive than those appearing on healthy skin [7].

Computed tomography and magnetic resonance imaging can help establish the true extent of the disease, lymph node evaluation and monitoring after surgery, but the diagnosis is still made by anatomopathological study.

The treatment of hidrosadenitis suppurativa is not well established. In 1989, Hurley proposed a preliminary clinical staging approach [8]. This classification can be useful in making therapeutic choices (Table 1).

**Table 1: Hurley classification**

Grade I: Abscess formation, single or multiple, without sinus tracts and healing.
Grade II: Recurrent abscess with tract formation and healing. Single or multiple lesions, widely separated
Grade III: Diffuse or quasi-diffuse involvement, or multiple tracts and abscesses interconnected over the entire area

According to this staging, medical treatment is recommended in the early stages. However, surgical excision should be considered in stages II and III.

In the event of degeneration into squamous cell carcinoma, an aggressive approach is essential to prevent significant morbidity and mortality. In the literature, some authors [3, 5] recommend wide and deep surgical excision, with a minimum margin of 2 cm when possible, comparable in our study where 2 cases were wide excision and 2 cases of metastasis were referred to the oncology department.

For coverage, depending on the extent of the loss of substance, the choice is between directed healing, thin skin grafting and regional flaps [9].

In the literature, radiotherapy is only recommended for patients not undergoing surgery. The efficacy of chemotherapy has not been demonstrated. It is followed by high morbidity and frequent chemoresistance [10].

## CONCLUSION

The transformation of hidrosadenitis suppurativa into squamous cell carcinoma is a rare and

formidable complication. We emphasize the need for early diagnosis, and preventive surgical excision remains the best preventive treatment, with rigorous long-term monitoring to avoid any fatal evolution.

## BIBLIOGRAPHY

1. Donsky, H. J., & Mendelson, C. G. (1964). Squamous cell carcinoma as a complication of hidradenitis suppurativa. *Archives of Dermatology*, 90(5), 488-491.
2. Heid, E., & Chartier, C. H. (2001). Hidradénite suppurative (maladie de Verneuil). In *Annales de dermatologie et de vénéréologie*, 128(2):158-160.
3. Talmant, J. C., Bruant-Rodier, C., Nunziata, A. C., Rodier, J. F., & Wilk, A. (2006, February). Dégénérescence de maladie de Verneuil en carcinome épidermoïde: à propos de 2 cas et revue de la littérature. In *Annales de chirurgie plastique esthétique*, 51(1), 82-86.
4. Anderson, B. B., Cadogan, C. M., & Gangadharam, D. (1982). Hidradenitis suppurativa of the perineum, scrotum, and gluteal area: presentation, complications, and treatment. *Journal of the National Medical Association*, 74(10), 999-1003.
5. Jourabchi, N., Fischer, A. H., Cimino-Mathews, A., Waters, K. M., & Okoye, G. A. (2017). Squamous cell carcinoma complicating a chronic lesion of hidradenitis suppurativa: a case report and review of the literature. *International wound journal*, 14(2), 435-438.
6. Lavogiez, C., Delaporte, E., Darras-Vercambre, S., Martin De Lassalle, E., Castillo, C., Mirabel, X., ... & Mortier, L. (2010). Clinicopathological study of 13 cases of squamous cell carcinoma complicating hidradenitis suppurativa. *Dermatology*, 220(2), 147-153.
7. Anstey, A. V., Wilkinson, J. D., & Lord, P. (1990). Squamous cell carcinoma complicating hidradenitis suppurativa. *British Journal of Dermatology*, 123(4), 527-531.
8. Dhaou, B. B., Boussema, F., Aydi, Z., Baili, L., & Rokbani, L. (2013). Hidradenitis suppurativa (Verneuil's disease). *Journal of the Saudi Society of Dermatology & Dermatologic Surgery*, 17(1), 1-5.
9. Wiseman, M. C. (2004). Hidradenitis suppurativa: a review. *Dermatologic therapy*, 17(1), 50-54.
10. Atri, S., Mahmoud, A. B., Zehani, A., Chammakhi, A., Rebai, W., & Kacem, M. J. (2021). The management of hidradenitis suppurativa degenerating into squamous cell carcinoma: About three case reports. *Annals of Medicine and Surgery*, 64, 102239. Disponible sur: <https://journals.lww.com/10.1016/j.amsu.2021.102239>.