

Splenic Tuberculosis: A Case Report

O. Ounjif^{1*}, A. Chanfir¹, A. Mahmoud¹, Z. Naimi¹, B. Jounid¹, A. Elatraoui¹, Y. Elhadrami¹, W. Berramou¹, A. Hamri¹, Y. Narjis¹, R. Benelkhaïat¹

¹Department of Surgery, Ibn Tofail Hospital, Mohamed 6 University Hospital, Faculty of Medecine and Pharmacy, Cadi Ayad University, Marrakech 4000, Morocco

DOI: [10.36347/sasjs.2023.v09i09.007](https://doi.org/10.36347/sasjs.2023.v09i09.007)

| Received: 27.06.2023 | Accepted: 23.07.2023 | Published: 08.09.2023

*Corresponding author: O. Ounjif

Department of Surgery, Ibn Tofail Hospital, Mohamed 6 University Hospital, Faculty of Medecine and Pharmacy, Cadi Ayad University, Marrakech 4000, Morocco

Abstract

Case Report

The bacillus Koch (BK) is the root cause of the Tuberculosis infection, which is an infectious disease with human to human transmission. It is a major public health problem. Splenic tuberculosis remains very rare, and is often evocative of immunodepression. The Clinical appearance is highly variable but non-specific; splenomegaly may be present in the majority of cases. Ultrasound and abdominal CT scans play a major role. Bacteriological and sometimes histological evidence is required. The treatment is essentially medical: anti bacillary agents.

Keywords: Tuberculosis, bacillus Koch, splenomegaly, anti-bacillary agents.

Copyright © 2023 The Author(s): This is an open-access article distributed under the terms of the Creative Commons Attribution 4.0 International License (CC BY-NC 4.0) which permits unrestricted use, distribution, and reproduction in any medium for non-commercial use provided the original author and source are credited.

INTRODUCTION

Tuberculosis is an infectious disease with human-to-human transmission caused by the bacillus Koch (BK). It is a major public health problem throughout the world, despite ongoing efforts to combat it [1]. Splenic tuberculosis remains one of the rare aspects of deep-organ hematopoietic tuberculosis, often associated with other localizations (pulmonary, ileocecal, etc.).

Splenic tuberculosis occupies an important place of gastroenterologists, hematologists and surgeons concerns;

It is a less common but important manifestation of abdominal tuberculosis, its prevalence is increasing with the onset of HIV, but even in highly endemic countries it is still a rare localization.

OBSERVATION

23 years old patient treated for peritoneal tuberculosis a year ago, presenting with left hypochondrium pain and persistent fever evolving for 6 months prior to admission with signs of weight loss and altered general condition.

On examination: patient conscious, stable, arch on the left hypochondrium with abdominal sensibility

Free hernial orifices

Free lymph nodes

CT: objective multicystic spleen, and a liver with normal appearance

Chest x-ray: normal

Treatment: Patient operated by laparotomy

Surgical exploration: revealed an enlarged spleen with multiple cysts

Surgery: consisted of a splenectomy

The postoperative course was straightforward, and the patient was discharged in D4 post-op. Anathomopathological result: showed epithelial gigantocellular granuloma with caseous necrosis.

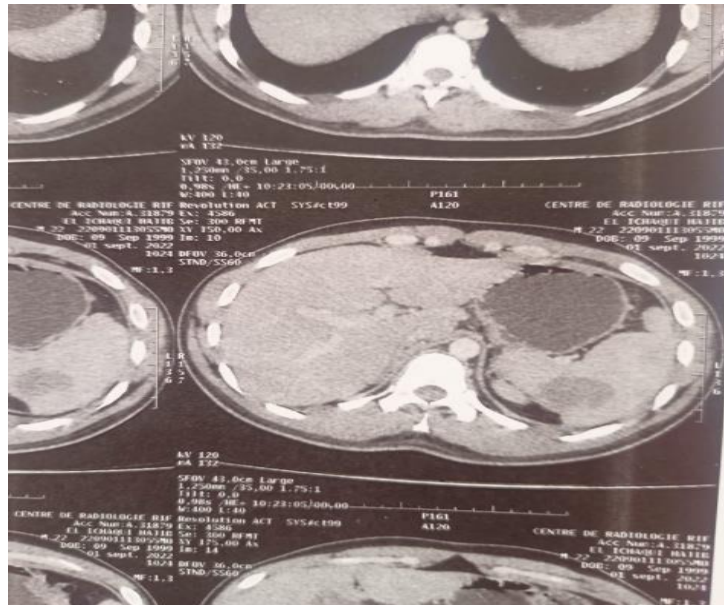


Figure 1: Transverse section of an abdominal CT scan passing through the spleen

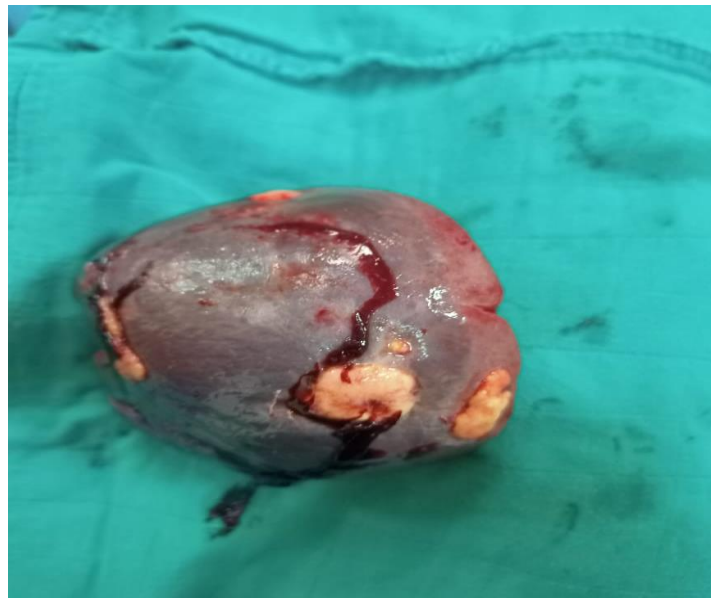

Figure 2: Operating unit (splenectomy)

DISCUSSION

According to the World Health Organization, extrapulmonary tuberculosis accounts for around 16% of all tuberculosis cases in 2019 [2]. Splenic tuberculosis can occur as part of a pattern of diffuse hepatoganglionic and medullary hematopoietic involvement, accounting for around 1% of all tuberculosis and 10% of extrapulmonary forms [3]. Musculoskeletal tuberculosis accounts for around 10% of extrapulmonary tuberculosis cases and 1 to 5% of all tuberculosis cases [4]. These extra-pulmonary localizations are very often suggestive of immunodepression.

Involvement of the spleen seems to us to be more consistent with dissemination from an initial focus of infestation, whether old or recent, symptomatic or, more often than not, unrecognized and neglected. The

mechanism of dissemination is lymphatic or hematogenous. The bacterial agent is most often the bovine or human Koch's bacillus [4].

Splenic tuberculosis can manifest itself in different but non-specific clinical features. Weight loss, fever and anemia are the most common manifestations [5, 6]. Hepatomegaly may also be present, in most cases of abdominal tuberculosis [7]. A rapid, often fatal course with cachexia, fever, haemorrhage or superinfection may be present in certain so-called malignant forms. Ultrasound and computed tomography are essential for the diagnosis of splenic tuberculosis. Heterogeneous images with hypodense focus associated with caseous necrosis make the diagnosis of tuberculosis difficult, especially as they may simulate other conditions such as a primary or secondary malignant tumour lesion [8, 9].

Bacteriological proof may be required, with the detection of Acid-Alcohol-Resistant Bacilli (AARB) after special Ziehl-Neelsen staining, and systematic culture of samples. The treatment of splenic tuberculosis is primarily medical, based on anti-bacillary agents.

CONCLUSION

Splenic tuberculosis in its pseudotumoral form is a rare condition whose diagnosis of certainty is histological and/or bacteriological. Isolated involvement of the spleen poses a diagnostic problem. In association with another focus of extrapulmonary tuberculosis, the diagnosis is easily made and antibacillary treatment is initiated, with good improvement without recourse to further histological evidence.

REFERENCES

- Jabri, H., Lakhdar, N., El Khattabi, W., & Afif, H. (2016). Les moyens diagnostiques de la tuberculose. *Revue de pneumologie clinique*, 72(5), 320-325.
- World Health Organization Global tuberculosis report. 2020.
- Adil, A., Chikhaoui, N., Ousehal, A., & Kadiri, R. (1995). La tuberculose splénique: A propos de douze cas. In *Annales de radiologie (Paris)* (Vol. 38, No. 7-8, pp. 403-407).
- Batirel, A., Sener A., & Erdem H., editors. (2019). Tuberculous spondylodiscitis. Extrapulmonary Tuberculosis Springer International Publishing. 83-99.
- Berady, S., Rabhi, M., Bahrouch, L., Sair, K., Benziane, H., Benkirane, A., ... & Toloune, F. (2005). Isolated tumoral tuberculosis of spleen.(Report of a case). *Revue De Medecine Interne*, 26(7), 588-591.
- Adil, A., Abdelouafi, A., & Kadiri, R. (1998). La tuberculose hépato-splénique pseudo-tumorale: A propos de quatre observations. *Radiologie (Berlin)*, 18(1), 17-20.
- Danon, O., Mofredj, A., Cava, E., Nguyen, V., Harry, G., & Cadranet, J. F. (2000). Infarctus splénique révélateur d'une tuberculose abdominale. *Gastroentérologie clinique et biologique*, 24(2), 240-241.
- Abitbol, V., Paupard, T., Etienney, I., Patey, O., Guez, C., & Oberlin, P. (1996). Aspects cliniques et radiologiques des abcès spléniques tuberculeux: Présentation de trois cas. *Gastroentérologie clinique et biologique*, 20(6-7), 597-600.
- Rhazal, F., Lahlou, M. K., Benamer, S., Daghri, J. M., Essadel, E., Mohammadine, E., ... & Belmahi, A. (2004, October). Splenomegaly and splenic pseudotumor due to tuberculosis: six new cases. In *Annales de chirurgie*, 129(8), 410-414.
- Mazloun, W., Marion, A., Ferron, C., Lucht, F., & Mosnier, J. F. (2002). Tuberculose splénique (à propos d'un cas et revue de la littérature), *Med et Mal Infect*, 8, 444-446.
- Pottakkat, B., Kumar, A., Rastogi, A., Krishnani, N., Kapoor, V. K., & Saxena, R. (2010). Tuberculose de la rate comme cause de fièvre d'origine inconnue et de splénomégalie. *Gut Liver*, 4(1), 94-97.
- Varatharajah, S., Charles, Y. P., Buy, X., Walter, A., & Steib, J. P. (2014). Traitement chirurgical actuel du mal de Pott. *Revue de Chirurgie Orthopédique et Traumatologique*, 100(2), 187-193.
- López-Sánchez, M. C., Calvo Arrojo, G., & Vázquez-Rodríguez, T. R. (2012). Spondylodiscite tuberculeuse avec tumeur lombaire. *Reumatol Clin*, 8(5), 292-293.
- Fedoul, B., Chakour, K., & Chaoui, M. E. F. (2011). Le mal de Pott: à propos de 82 cas. *Pan African Medical Journal*, 8(1).
- Canova, C. R., Khun, M., & Reinhart, W. H. (1995). Problemebei der diagnose und Therapie der Lymphknoten-tuberkulosebei HIV-negativenpatienten. *Schweiz MedWochenschr*, 125(51-52), 2511-2517.
- Organization WH. World Health Organization. 2010. Treatment of Tuberculosis: guidelines.
- DSSB: Le guide national de prise en charge de la tuberculose édition 2018- Ministère de la santé publique.
- Janssens, J. P., & De Haller, R. (1990). Spinal Tuberculosis in a Developed Country: A Review of 26 Cases With Special Emphasis on Abscesses and Neurologic Complications. *Clinical Orthopaedics and Related Research (1976-2007)*, 257, 67-75.
- Hima-Maiga, A., Kpelao, E., Kelani, A. B., Abdoulwahab, I., Diop, A., Sanoussi, S., & Sakho, Y. (2020). Le Mal de Pott Dorsal au Niger: aspects épidémiologiques, cliniques, thérapeutiques et évolutifs. *Health Sciences and Disease*, 21(10).
- Ajim, A., Bougteb, N., Arfaoui, H., Jabri, H., El Khattabi, W., & Afif, M. H. (2021). Mal de Pott: profil clinique, radiologique, et prise en charge thérapeutique. *Revue des Maladies Respiratoires Actualités*, 12(1), 272.