

Hemorrhoidectomy Using Ultrasonic Scalpel- A Comparative Study with Conventional Approach in a Secondary Care Hospital in Kashmir

Adnan Rashid Mattoo^{1*}, Rabia Sofi², Amat-us-samie³¹General & Minimal Access Surgeon, Department of General surgery, District Hospital Ganderbal Jammu and Kashmir India²Medical Officer, Directorate of Health services Kashmir Jammu and Kashmir, India³Senior Resident, Department of Pediatric Surgery, Govt. Medical College, Srinagar, IndiaDOI: [10.36347/sjams.2020.v08i02.060](https://doi.org/10.36347/sjams.2020.v08i02.060)

| Received: 10.02.2020 | Accepted: 18.02.2020 | Published: 28.02.2020

*Corresponding author: Dr. Adnan Rashid Mattoo

Abstract

Original Research Article

Background: Hemorrhoid disease is the symptomatic enlargement and protrusion of normal anal cushions. Haemorrhoidectomy performed with harmonic scalpel is proposed as a faster and less painful alternative to conventional techniques. The aim of this study was to compare the results of Harmonic scalpel hemorrhoidectomy with conventional open method in terms of postoperative pain, operative time and early mobilization of hemorrhoidectomy patients for the treatment of hemorrhoids. **Methods:** In this observational study, 50 Patients with grade III - IV hemorrhoids, operated between January 2018 to December 2018, using the harmonic scalpel Group A (n=25) or the conventional open technique Group B (n=25) were included. Both the groups were compared with respect to Operative time, Blood loss during surgery, early postoperative complications, postoperative pain measured on a visual analog scale (VAS), hospital stay, and return to normal work. **Results:** In the present study, average time taken was 16.42 ± 3.54 minutes in group A, while it was 20.39 ± 4.58 minutes in group B with statistical significant difference among the study groups ($p < 0.05$). The mean blood loss was 6.25 ± 2.20 ml, 30.25 ± 4.58 ml in the group A and group B respectively which was statistically significant ($p < 0.05$). Postoperative pain with VAS in group A on the first postoperative day was 4.25 ± 1.52 , while it was 7.28 ± 2.67 in the group B statically significant ($p < 0.05$). The dose of analgesia was less in group A. The postoperative wound site soakage was less in group A, early ambulation and return to normal work was faster in group A. **Conclusions:** Hemorrhoidectomy using an ultrasonic scalpel is an effective and safe procedure in terms of blood loss, postoperative pain early return to routine work.

Keywords: Harmonic scalpel, Haemorrhoids, postoperative pain, Haemorrhoidectomy, Early ambulation.

Copyright @ 2020: This is an open-access article distributed under the terms of the Creative Commons Attribution license which permits unrestricted use, distribution, and reproduction in any medium for non-commercial use (NonCommercial, or CC-BY-NC) provided the original author and source are credited.

INTRODUCTION

Haemorrhoids are cushions of specialized, highly vascular tissue found within the anal canal, in the sub mucosal space. They contain blood vessels, elastic tissue, connective tissue, and smooth muscle [1]. It is a common surgical condition occurring in 4.4% of adults with peak prevalence between 45 and 65 years of age, according to epidemiological study conducted in the USA [2].

A hemorrhoidectomy is the standard treatment for patients with grade III or IV internal hemorrhoids [3]. The most effective hemorrhoidectomy methods are the Milligan-Morgan open hemorrhoidectomy and the Ferguson closed hemorrhoidectomy. These methods are similar and are recognized as traditional methods [4, 5]. However, although they may be the most effective treatment for hemorrhoids, complications, such as

postoperative bleeding, surgical-site anal pain, anal stenosis, and incontinence, can occur after the surgery. These complications increase the patient's hospitalization period, can delay the return to ordinary life and the workplace after surgery, and can increase the rate of revisits to the hospital [6]. In particular, postoperative pain and bleeding are experienced by many patients after undergoing a hemorrhoidectomy, and many patients complain of discomfort for a long time. As a result, various surgical equipment, surgical methods, and supportive therapies have been introduced to overcome the postoperative pain and bleeding.

In recent years, several pieces of surgical equipment have been developed due to advances in technology, and now hemorrhoidectomies are being performed with new devices, such as bipolar electrothermal devices, ultrasonic scalpels, and circular staplers. The Harmonic Scalpel cuts and coagulates by

using lower temperatures than those used by electro surgery or lasers. Harmonic Scalpel technology controls bleeding by coaptive coagulation at low temperatures ranging from 50°C to 100°C: vessels are coated (tamponaded) and sealed by a protein coagulum. Coagulation occurs by means of protein denaturation when the blade, vibrating at 55,500 Hz, couples with protein, denaturing it to form a coagulum that seals small coated vessels [7].

METHODS

The present study was conducted in the department of surgery at District Hospital Ganderbal, (J&K) for 50 patients of both sexes, aged between 18 to 60 years, equally divided in to two groups, Group A (n=25) and Group B (n=25), who underwent a hemorrhoidectomy for grade III or IV hemorrhoids between Jan 2018 to December 2018. Twenty-five patients (Group A) underwent a hemorrhoidectomy performed with an ultrasonic scalpel. The other 25 patients (Group B) underwent a hemorrhoidectomy performed with monopolar electric cautery, which was defined as the conventional method. Patients with liver cirrhosis, diabetes, hemorrhagic diseases, or HIV were excluded from the present study. Written informed consent was obtained from all the patients before surgery.

The baseline investigations which include CBC, KFT, LFT, blood sugar, chest x-ray, ECG, serology, urinalysis were checked preoperatively and were admitted to the hospital the day before surgery. All patients took a proctoclysis enema the night before surgery, and prophylactic antibiotics were injected before entrance to the surgical room. All patients had spinal anesthesia and were placed in lithotomy position for surgery.

Milligan-Morgan technique, V shaped incision is made at anoderm, internal sphincter is separated off the hemorrhoid tissue till its origin above the dentate line, haemorrhoidal plexus were removed using scalpel and pedicle was ligated with 2/0 vicryl suture, and the wound was left open.

In harmonic scalpel haemorrhoidectomy, hemorrhoid tissue were removed using the harmonic scalpel up to its pedicle (Ethicon Endo-Surgery) and the wounds were left open. Anal pack was placed in both the techniques. For postoperative analgesia (Diclofenac sodium) were given. At the time of discharge, patients were prescribed oral analgesics, oral antibiotics and stool softeners.

All patients had same kind of analgesia during the postoperative course in the form of injection (Diclofenac sodium). Postoperative pain was assessed using visual analogue scale, from 0 to 10. And follow up was scheduled on first, second and third week post

operatively. The VAS score ranges from 0, indicating no pain, to 10, indicating severe pain. Major bleeding was defined as that requiring intensive treatment (including blood transfusion, reoperation) or close monitoring. Minor bleeding was defined that not needing monitoring with minimal bleeding after defecation. We also noted any occurrence of an anal abscess or gangrene, an anal stricture, and fecal incontinence.

All statistical analyses were performed using IBM SPSS ver. 18.0 (IBM Co., Armonk, NY, USA). Categorical variables were analyzed using the chi-square or Fisher exact test, and continuous variables were analyzed using the Student t-test or Mann-Whitney U rank test. We considered P-values of less than 0.05 to be statistically significant.

RESULTS

In total, 50 patients were analyzed; of these 25 patients (Group A) underwent a hemorrhoidectomy performed with an ultrasonic scalpel and 25 patients (Group B) underwent a hemorrhoidectomy performed with conventional method. There was no significant difference between patients subjected to conventional open or harmonic scalpel haemorrhoidectomy in terms of age, gender, weight, height and grade of haemorrhoid (Table 1).

Table-1: Demographic Profile:

Variables	Group A (n=25)	Group B (n=25)	P value
Age	49.58 ± 8.54	47.72 ± 7.62	>0.05
Weight	61.52 ± 4.63	62.20 ± 4.35	>0.05
Height	155.10 ± 4.59	157.38 ± 4.79	>0.05
M/F	15/10	20/05	>0.05
Grade III/IV	17/08	15/10	>0.05

Intra operative blood loss was significantly less in Harmonic scalpel Haemorrhoidectomy than in conventional method (6 ml and 30 ml respectively, p<0.01). The operative time was also less in group A as compared to group B 16min vs 20min. Early postoperative complications like bleeding and urinary retention were less in Harmonic scalpel haemorrhoidectomy 3(12%), 1(4%) compared to conventional method 7(28%), 5(20%).table.2

Table-2: Comparison of Intra operative parameters among thestudy groups:

Variables	Group A (n=25)	Group B (n=25)	P value
Operative time(min)	16± 3.25	20 ± 4.90	<0.05
Blood loss(ml)	6 ± 2.99	20 ± 4.35	<0.05

Post-operative visual analog Scale (VAS) pain score at different time intervals were statistically significantly lower at all times in Group A than Group B p-value (p<0.05).Fig.1

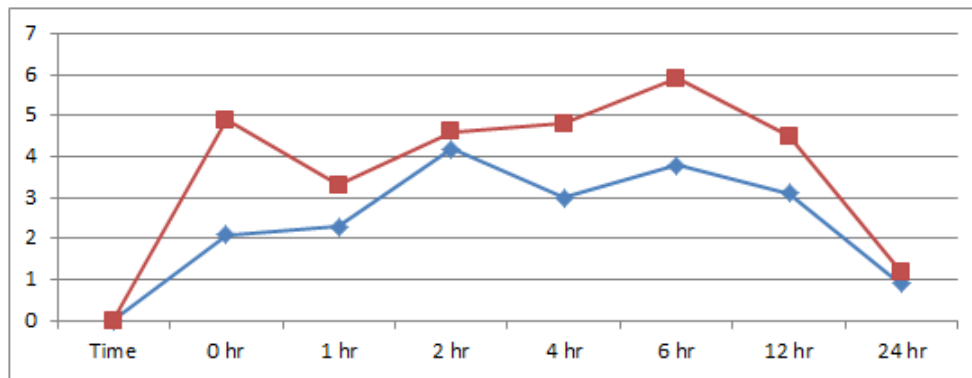


Fig-1: Post-operative visual analog Scale (VAS) pain score (mean±SD) in studied groups

Return to normal activity was early in patients operated by Harmonic scalpel method than conventional method (1 week vs 2 week Days with P-value <0.05). Hospital stay was also longer in group B as compared to group A.

DISCUSSION

Surgical haemorrhoidectomy is generally done for grade III and grade IV haemorrhoids. There are many procedures done for haemorrhoids. The new surgical techniques decrease the post-operative complication especially pain and bleeding. The Harmonic scalpel has unique advantage of causing less postoperative pain because of very little lateral thermal injury [8].

A hemorrhoidectomy with a circular stapler is performed to excise a complete ring of mucosa, including the hemorrhoidal tissue, above the dentate line [9, 10]. However, this procedure is limited to removing prolapsed hemorrhoidal tissues of the anal verge or skin tags [11]. In addition, the cost of performing a hemorrhoidectomy with a circular stapler is high, and the method often leads to complications such as postoperative bleeding, rupture of the anastomosis site, pelvic sepsis, anastomotic stricture, and rectovaginal fistulae [12].

The LigaSure and harmonic scalpels are newly developed ultrasonic scalpel instruments with automatic vessel-sealing systems. These instruments contain a bipolar, electrothermal, hemostatic device that use radio-frequencies and pressure to ensure complete cutting and coagulation of vessels up to 7 mm in diameter, with minimal surrounding thermal spread (<2 mm) and limited tissue-charring [13]. For a hemorrhoidectomy performed with an ultrasonic scalpel, intraoperative bleeding may be minimized, and the visibility of the surgical field is better. Performing resection and hemostasis at the same time reduces the operation time and complications, such as postoperative bleeding, pain, and infection, by reducing the damage to the surrounding mucosal tissue. In contrast, for a hemorrhoidectomy performed with conventional methods, the surrounding mucosal tissues and blood

vessels can be damaged during resection of the hemorrhoidal tissue, and the time to hemostasis of the blood vessels and tissues may cause increases in both the operation times and the possibility of postoperative bleeding. Furthermore, several previous studies have reported that the use of the ultrasonic scalpel results in significantly shorter operation times and less postoperative bleeding when compared with a conventional hemorrhoidectomy [14-17]. In the present study's ultrasonic scalpel group, no patient experienced major bleeding and 3 patients (12%) experienced minor bleeding; however, in the conventional method group, 7 patients (28%) experienced major bleeding and 5 (20%) experienced minor bleeding. Most patients with complications were successfully treated with conservative management. Also, the operation times were shorter in the ultrasonic scalpel group than they were in the conventional method group (16 ± 2.99 minutes vs. 20 ± 4.33 minutes, respectively; $P < 0.05$).

The study done by Armstrong DN *et al.* reported the VAS of 8.2, 8.1 and 6.4 on the first, second and seventh postoperative days respectively [18]. When we compared visual analogue score of our case study with control one the pain was much less in our case study ($p < 0.001$) same as given by other studies like Waleed Omar *et al.* ($p < 0.001$), Armstrong DN, *et al.* (< 0.001) and Mustafa T *et al.* ($p < 0.001$) [19]. In our Harmonic study group analgesic was given on demand in the form of diclofenac sodium. On the first postoperative day the mean analgesic given was 148.50 ± 11.13 mg followed by 118.30 ± 9.99 mg, 71.10 ± 12.52 mg on the second and seventh postoperative days. The study conducted by Waleed Omar *et al.* also reported less usage of analgesic as 120-160 mg, 100-150 mg and 50-100 mg on the first, second and seventh postoperative days, while Mustafa T *et al.* in their study reported 170-380 mg on the first postoperative day followed by 170-350 mg on the second postoperative day with no use of analgesics on the seventh postoperative day [15,19].

The VAS pain scores at day 1, week 1 and week 2 were lesser in harmonic scalpel compared to Milligan-Morgan method. Post-operative complications such as hemorrhage and urinary retention were more in

Group B. Harmonic scalpel haemorrhoidectomy has been found advantageous method when assessing the amount of blood loss during surgery, post-operative pain, early postoperative complications, and early return to normal work compared to conventional method. Hence, Harmonic scalpel haemorrhoidectomy can be considered as safe and effective alternate method in treating symptomatic haemorrhoids.

REFERENCES

1. Thomson WH. The nature of haemorrhoids. *Br J Surg.* 1975;62(7):542-52.
2. Johanson JF, Sonnenberg A. The prevalence of hemorrhoids and chronic constipation. An epidemiological study. *Gastroenterol.* 1990;98(2):380-6.
3. MacRae HM, McLeod RS. Comparison of hemorrhoidal treatment modalities. A meta-analysis. *Dis Colon Rectum.* 1995;38: 687-94.
4. Milligan ET, Morgan CN, Jones LE, Office R. Surgical anatomy of the anal canal, and the operative treatment of haemorrhoids. *Lancet.* 1937;230:1119-24.
5. Ferguson JA, Heaton JR. Closed hemorrhoidectomy. *Dis Colon Rectum.* 1959;2:176-9.
6. Goligher JC, Graham NG, Clark CG, De Dombal FT, Giles G. The value of stretching the anal sphincters in the relief of post-haemorrhoidectomy pain. *Br J Surg.* 1969;56:859-61.
7. Feil W. Principles of ultrasonic energy for cutting and coagulation. In: Deguelde M, Löhlein D, Dallemagne B, Kauko M, Walther B, editors. *Ultrasonic energy for cutting, coagulating and dissecting.* New York, NY: Thieme. 2005:14-25.
8. Waleed O, Sabry M, Mohamed F. Harmonic scalpel versus conventional diathermy haemorrhoidectomy; Gain or Pain. *EJS.* 2011;30(3):111.
9. Hetzer FH, Demartines N, Handschin AE, Clavien PA. Stapled vs excision hemorrhoidectomy: long-term results of a prospective randomized trial. *Arch Surg.* 2002; 137:337-40.
10. Longo A. Treatment of haemorrhoid disease by reduction of mucosa and haemorrhoidal prolapse with a circular-suturing device: a new procedure. In: *Proceedings of the Sixth World Congress of Endoscopic Surgery;* 1998 Jun 3-6; Rome, Italy. Bologna: Monduzzi Editore, International Proceedings Division; 1998: 777-84.
11. Engel AF, Eijbouts QA. Haemorrhoidectomy: painful choice. *Lancet.* 2000;355:2253-4.
12. Ravo B, Amato A, Bianco V, Boccasanta P, Bottini C, Carriero A, Milito G, Dodi G, Mascagni D, Orsini S, Pietroletti R. Complications after stapled hemorrhoidectomy: can they be prevented?. *Techniques in coloproctology.* 2002 Sep 1;6(2):83-8.
13. Sayfan J, Becker A, Koltun L. Sutureless closed hemorrhoidectomy: a new technique. *Ann Surg.* 2001; 234:21-4.
14. Jayne DG, Botterill I, Ambrose NS, Brennan TG, Guillou PJ, O'Riordain DS. Randomized clinical trial of Ligasure versus conventional diathermy for day-case haemorrhoidectomy. *Br J Surg.* 2002; 89:428-32.
15. Bulus H, Tas A, Coskun A, Kucukazman M. Evaluation of two hemorrhoidectomy techniques: harmonic scalpel and Ferguson's with electrocautery. *Asian J Surg.* 2014;37:20-3.
16. Gentile M, De Rosa M, Carbone G, Pilone V, Mosella F, Forestieri P. LigaSure haemorrhoidectomy versus conventional diathermy for IV-degree haemorrhoids: is it the treatment of choice? A randomized, clinical trial. *ISRN Gastroenterol.* 2011; 2011:467258.
17. Milito G, Cadeddu F, Muzi MG, Nigro C, Farinon AM. Haemorrhoidectomy with Ligasure vs conventional excisional techniques: meta-analysis of randomized controlled trials. *Colorectal Dis.* 2010;12:85-93.
18. Armstrong DN, Frankum C, Schertzer ME. Harmonic scalpel Hemorrhoidectomy, Five Hundred Consecutive Cases. *Dis Colon Rectum.* 2002;45:354-9.
19. Ozer MT, Yigit T, Uzar AI, Menten O, Harlak A, Kilic S, Cosar A, Arslan I, Tufan T. A comparison of different hemorrhoidectomy procedures. *Saudi Med J.* 2008 Sep 1;29(9):1264-9.