

Characterization of Bone Metastasis in Breast Cancer for Sundaes Female Patients by Using Bone Scintigraphy

Musab Mergani Abd Alla Abdelmagid^{1*}, Ala M. A. Elgyoum¹, Asma Alamin^{1,2}, Waleed H. Mhammed¹

National Ribat University, Faculty of Radiological and Nuclear Medicine Science, Nile Street Burri, Postal Code 11111, Khartoum – Sudan

Colleges of Medical Radiologic Science, Sudan University of Science and Technology P.O. Box 1908, Khartoum – Sudan

Original Research Article

*Corresponding author

Musab Mergani Abd Alla
Abdelmagid

Article History

Received: 04.04.2018

Accepted: 16.04.2018

Published: 30.04.2018

DOI:

10.36347/sjams.2018.v06i04.047



Abstract: The general aim of this study was to characterize bone metastasis from female breast cancer patients by using bone scan, data was collected retrospectively from bone scan images for known case of breast cancers females and were received different types of treatment with age ranged between 25-90 years and the sample size had been about 150 patients whom coming to the nuclear medicine departments in Khartoum state during a period from January 2017 to May 2017, bone scan was carried out using gamma camera dual heads and the data was interpreted by nuclear medicine specialists and collected from reports and its analyzed by Microsoft office (EXCELL). The breast cancer is commonly affecting the female with age group greater than 40 and less than 60 years old and the age between 55-70 years old is considered as the second age group, ca breast able to attack the left breast more than the right one in the percentage of 50.7% to 49.3% respectively. The carcinoma of the left breast is commonly gives some considerable metastasis to the Lumber vertebrae, dorsal vertebrae, pelvic bone, ribs, cervical vertebrae and the femur bone respectively; the carcinoma of the right breast is commonly gives some considerable metastasis to the Lumber vertebrae, dorsal vertebrae, pelvic bone, cervical vertebrae, the skull and femur bone respectively, the metastasis in the left and right ca breast following the same behavior in popular anatomical region in spiriting but a different percentage of anatomical region invading and the bilateral breast cancer has zero percentage from the total sample size. The researcher recommended to encouraging the annual screening for women breast with low cost or free of charge and should be done for women whom are accused of breast cancer as well as pre and post radiation therapy cycles, also recommended to use another radiological modality to grading and staging of the tumor (CT scan) to represent other organs involvement.

Keywords: bone metastasis, breast cancer, carcinoma.

INTRODUCTION

Breast cancer (Ca breast) affects 34.5% of women and 0.1% of men in Sudan [1], for the remaining approximately two-third of women, the probability of being a Ca breast patient increases with some factors. Amid these are; history of breast cancer in family, previously diagnosed breast cancer or any benign tumour, unusual onset of puberty or menopause, infertility, chest-wall irradiation, obesity, and high estrogen and alcohol intakes [2, 3]. Moreover, several studies showed that the incidence of unilateral breast cancer is much higher than bilateral cases, with the left Ca breast figures greater than the right.

Metastatic cells spread over the lymphatic systems, which justifies the common axillary and neck lymphadenopathy associated with breast carcinoma. The cancer may also infiltrate the bones, results in;

pain, vulnerability to pathological fractures, and neurological disorders from spinal nerves compression [4]. The most common sites for Ca breast bone metastasis are flat bones, such as the pelvis and the skull as well as long and irregular bones, the legs and the spine in particular [5].

All medical imaging modalities; starting from plain x-ray, computed tomography, magnetic resonance imaging, and nuclear medicine scanning, except for ultrasound, are being utilized in detection bone diseases. However, when comparing the efficiency of these various techniques for early highlighting of bone metastasis, bone scintigraphy, which is also known as skeletal scintigraphy, is superior [6]. The bone scan involves administration of radiopharmaceutical into the blood stream. The radiopharmaceutical traces and combines bones

tissues, and thereafter emit gamma rays which are then registered by the gamma detectors.

In this study we aim to characterise breast cancer and associated bone metastasis in Sudanese female breast cancer patients.

MATERIALS AND METHODS

Retrospectively 150 women aged from 25-90 diagnosed with breast cancer were studied at three different nuclear medicine departments in Khartoum.

Bone scans procedure

All patients were injected with technetium-methylenediphosphate (^{99m}Tc -MDP). And were positioned supine on SPECT table. Images were acquired within 2-4 hours post-injection. All images were interpreted by nuclear medicine physician.

Position circuitry

The position logic circuits immediately follow the photomultiplier tube array and they receive the electrical impulses from the tubes in the summing matrix circuit (SMC). This allowed the position circuits to determine where each scintillation event occurred in the detector crystal.

Study methods

Preparation of ^{99m}Tc -MDP injection

The MDP kits contains sterile component in lyophilized form which after reconstitution with pertechnetate solution a complex of methylenediphosphate ((MDP) with technetium ^{99m}Tc formed, which show an affinity to hydroxyapatite of the bone tissue. Under sterile condition 5ml of sodium pertechnetate solution with maximum activity of 100-500mCi was added to the MDP vial content through the stopper. The vial Content was mixed for a period of 20 minute. The pH value of the prepared Radiopharmaceutical has 5-7. The ^{99m}Tc -MDP preparation was administered within 6 hours from the preparation time.

Patient preparations

Patient was instructed to be well hydrated by drinking water. Prior to the imaging, the patient has to drink at least one liter of fluid between injection and imaging. The patient was encouraged to avoid immediately prior to imaging, breast feeding patient should stopped breast feeding 24 hours after injection of radiopharmaceuticals. Patient was laid in supine position, a pillow was placed under the patients knees for comfort if necessary. Metal objects were removed (e.g. coin and keys) prior imaging.

Mode of administration of ^{99m}Tc -MDP

From the reception hall of patient, the patient was called to hot lab for recording the name, age, weight and height upon which the dose was determined and injected intravenously (^{99m}Tc -MDP) using syringe shield and butter fly for protection purposes. Then the patient was left to stay for 2 hrs at specially waiting room. After the intravenous administration the TC^{99m} -MDP complex was taken up by soft tissues and accumulated in the kidneys then redistribution starts and accumulation in the skeleton increases. The maximum accumulation in the bones is reached 1 hour after administration.

Imaging Procedure

Image was obtained after 2 to 4 hours following administration. A longer delay image was helpful in elderly patients with slower bone uptake. SPECT image technique includes anterior and posterior views of axial skeleton. If anterior and posterior were equivocal spot views were helpful (e.g. pelvic, lateral skull views) where bladder activity obscures pelvic structures lateral or squat views were obtained or a further post void image undertaken. If the patient was unable to empty the bladder masking the retained urinary activity with lead shielding will allow improved detail in the rest of the pelvis.

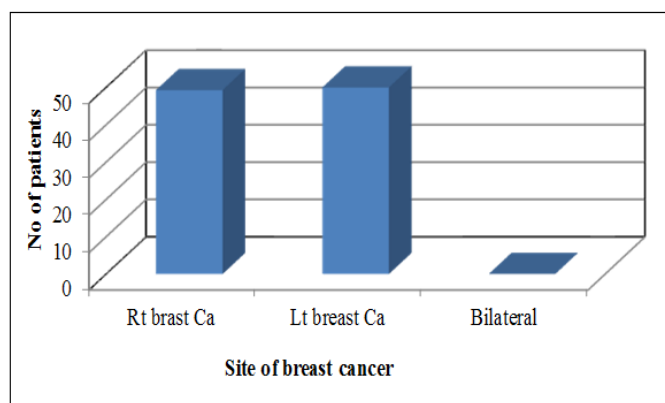


Fig-1: The percentage distribution of cancer involvement for women breast

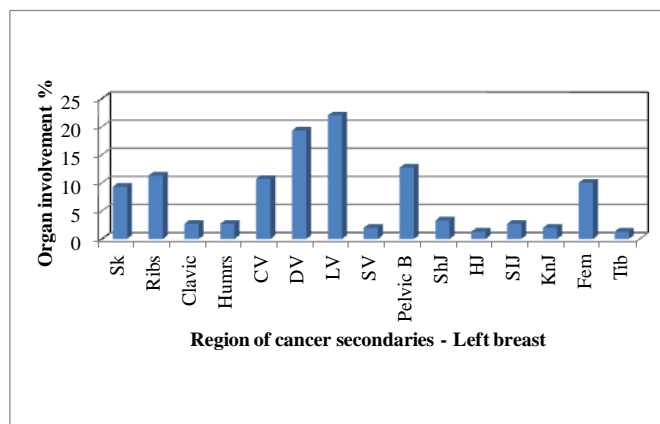


Fig-2: The percentage of common regions of cancer secondaries among women for left breast

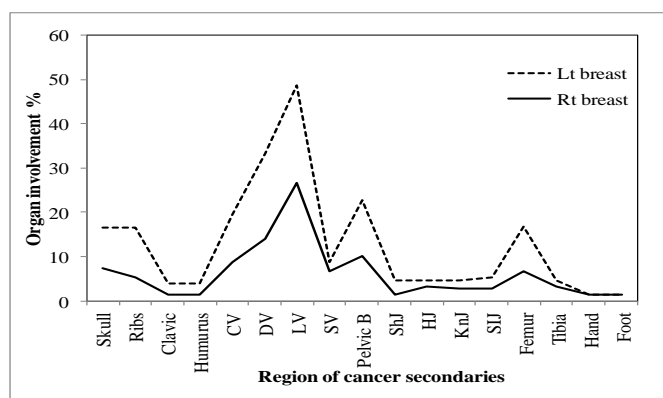


Fig-3: The metastasis percent on organs from right and left breast cancer

Table-1: The distribution of cancer involvement based on women age

Age	No.	Frequency %
25 – 40	36	24
40 – 55	50	33.3
55 – 70	39	26
70 – 85	20	13.3
85 – 100	5	3.3
Total	150	99.9

Table-2: The common regions of cancer secondaries among women for right breast

Region of cancer secondaries	Frequency %
Skull (Sk)	7.3
Ribs (Rib)	5.3
Clavicle (clavic)	1.3
Humorous(Humrs)	1.3
Hand	1.3
Cervical vertebrae (CV)	8.7
Dorsal vertebrae (DV)	14
Lumbar vertebrae (LV)	26.7
Sacral vertebrae (SV)	6.7
Pelvic bone(Pelvic B)	10
Shoulder joint(ShJ)	1.3
Sacroiliac joint (SIJ)	2.7
Hip joint (HJ)	3.3
Knee joint (KnJ)	2.7
Femur	6.7
Tibia	3.3
Foot	1.3

Table-3: The involvement percentage of the lung by breast cancer metastasis

Lung involvement %	Organ of origin
2	Right breast
1.3	Left breast

RESULTS AND DISCUSSION

Regarding distribution of cancer for women breast site, the results indicated that the left breast is more susceptible to breast cancer than the right one, such evidence clearly shown in Fig 1 with a percentage of 50.7% greater than the right one which is 49.6% and bilateral breast cancer has zero percentage, and the result is in agreement with the document of Suliman and Ahmed [7] which indicated that the carcinoma of the breast affects the left breast with percentage of 66% greater than the right breast which has 31% and bilateral breast cancer 3%, this result indicate that bilateral breast cancer incidence represent very small proportion of all breast carcinoma cases.

Also this result have a great agreement with the study of Roida Bushra [8] which reveal that indicated that the left breast is percentage 51.4% so more susceptible to breast cancer than the right one greater than the right one which is 48.6% and bilateral breast cancer has zero percentage from 150 patients. The distribution of breast cancer among the women based on their ages is shown in Table 1, it is apparent that 33.3% of the sample was found to be in women with age group 40-55 years and 24% in women with age 25-40 years old. However, in developed country it was found that the breast cancer is predominant among the age group of 20-43 years old i.e. 12 % [9].

The prevalence of breast Ca. among age group of 40-55 years old is clearly demonstrated with a percentage of 33.3% from the general sample. This finding is in agreement with Anderson *et al.*, [10]; they found that the breast cancer is so predominant among black women and commonly above the age of 40 years old.

In Table-3 the data shows the common regions of skeletal system where the cancer cells could be seeded to establish secondary tumors from the right breast cancer. The carcinoma of the right breast is commonly gives some considerable metastasis to the Lumber vertebrae with a percentage of 26.7%, the dorsal vertebrae with a percentage of 14%, the pelvic bone with a percentage of 10%, the cervical vertebrae with a percentage of 8.7%, the skull with a percentage of 7.3% and femur bone with percentage of 6.7%. The common metastatic properties from breast cancer is due to estrogen receptor positive subtypes [14], this finding is an agreement with the literature review which stated that the breast cancer commonly gives metastasis to bone [7], however there are some organs more susceptible to metastasis than other parts as our study shows that within the skeletal system there is most common region for secondaries such as LV, DV

and Pelvic bone. Bacac and Ivan stated that growth of secondaries is mortgaged to factors of cell growth. The routes of skeletal metastasis are direct extension or invasion, lymphatic spread, hematogenous dissemination and intraspinal spread. Skeletal metastases of breast cancer will mainly occur from lymphatic spread and hematogenous dissemination.

Figure-2 presents the common regions of cancer secondaries among women for the left breast. The carcinoma of the left breast is commonly gives some considerable metastasis to the lumbar vertebrae with a percentage of 22%, the dorsal vertebrae with a percentage of 19.3%, the pelvic bone with a percentage of 12.7%, the ribs with percentage of 11.3%, the cervical vertebrae with a percentage of 10.7% and the femur bone with a percentage of 10%, similar results obtained by Koizumi *et al.*, [11] which concluded that bone is the most common sites of breast cancer secondaries. Within the skeletal system the most common region for secondaries are pelvic, upper leg bone (femur) and ribs but the spine is the most common site of bone metastasis (LV and DV). This finding is in agreement with the Gray *et al.*, [112] which found that the breast cancer is the most common site of origin of metastatic deposits in the skeleton and most commonly affects the spine, ribs, pelvis, and proximal long bones. Figure 3 shows the metastasis percentage in organs from right and left breast cancer, In general, the metastasis from both breasts to human system have shown same preferences; as to metastasize to certain organs higher than others i.e. the left and right breast cancer give metastasis to LV, DV and the pelvic bone as most higher than other parts of skeletal system. They also show the same phase of metastasis to other skeletal system segments, this could be due to symmetrical net of lymphatic drainage as well as the blood supply arteries and the drainage veins. The identity of both breasts cancer metastasis to general skeletal system has been shown in Fig-3.

The lung involvement from the right breast 2% whereas from the left breast is percentage 1.3 % which is clearly demonstrated in Table-3, this finding is an agreement with Stefan *et al.*, [13] who concluded that the spread of metastases may occur via the blood or the lymphatic system or through both routes, hence the most common places for the metastases to occur are the lungs.

CONCLUSIONS

The breast cancer is commonly affecting the female with age group greater than 40 and less than 60 years old and the age between 55-70 years old is considered as the second age group, Ca breast able to

attack the left breast more than the right one in the percentage of 50.7% to 49.3% respectively. The carcinoma of the left breast is commonly gives some considerable metastasis to the Lumber vertebrae, dorsal vertebrae, pelvic bone, ribs, cervical vertebrae and the femur bone respectively. The carcinoma of the right breast is commonly gives some considerable metastasis to the Lumber vertebrae, dorsal vertebrae, pelvic bone, cervical vertebrae, the skull and femur bone, the metastasis in the left and right ca breast following the same behavior in popular anatomical region in spiriting but a different percentage of anatomical region invading and the bilateral breast cancer has zero percentage from 150 patients.

RECOMMENDATIONS

Encouraging the annual screening for women breast with low cost or free of charge, bone scintigraphy should be done for women who are accused of breast cancer as well as pre/after radiation therapy course.

REFERENCES

1. Abdelrahman S, Yousif M. Self-Examination of the breast for early detection of breast cancer the role of medical students in the Faculty of Medicine-University of Gezira–Sudan. *J Public Health*. 2006;1:36-42.
2. Lehman CD, Gatsonis C, Kuhl CK, Hendrick RE, Pisano ED, Hanna L, Peacock S, Smazal SF, Maki DD, Julian TB, DePeri ER. MRI evaluation of the contralateral breast in women with recently diagnosed breast cancer. *New England Journal of Medicine*. 2007 Mar 29;356(13):1295-303.
3. Saslow D, Boetes C, Burke W, Harms S, Leach MO, Lehman CD, Morris E, Pisano E, Schnall M, Sener S, Smith RA. American Cancer Society guidelines for breast screening with MRI as an adjunct to mammography. *CA: a cancer journal for clinicians*. 2007 Mar 1;57(2):75-89.
4. Mundy GR, Ibbotson KJ, D'Souza SM, Simpson EL, Jacobs JW, Martin TJ. The hypercalcemia of cancer: clinical implications and pathogenic mechanisms. *New England Journal of Medicine*. 1984 Jun 28;310(26):1718-27.
5. Clines GA, Guise TA. Molecular mechanisms and treatment of bone metastasis. *Expert reviews in molecular medicine*. 2008 Mar;10.
6. Galasko CS, Doyle FH. The detection of skeletal metastases from mammary cancer. A regional comparison between radiology and scintigraphy. *Clinical radiology*. 1972 Jan 1;23(3):295-7.
7. Salim S, Elhaj A. Prevalence of bone metastasis from female breast cancer in central Sudan, *Institute of nuclear medicine, volume 7; 2008*.
8. Roidda B. Evaluation of bone metastasis in Ca breast in Sudanese female using bone scan; 2010.
9. Hickey M, Peate M, Saunders CM, Friedlander M. Breast cancer in young women and its impact on reproductive function. *Human reproduction update*. 2009 May 1;15(3):323-39.
10. Anderson WF, Rosenberg PS, Menashe I, Mitani A, Pfeiffer RM. Age-related crossover in breast cancer incidence rates between black and white ethnic groups. *JNCI: Journal of the National Cancer Institute*. 2008 Dec 17;100(24):1804-14.
11. Koizumi M, Yoshimoto M, Kasumi F, Ogata E. Comparison between solitary and multiple skeletal metastatic lesions of breast cancer patients. *Annals of oncology*. 2003 Aug 1;14(8):1234-40.
12. Cook GJ, Fogelman I. Skeletal metastases from breast cancer: imaging with nuclear medicine. In *Seminars in nuclear medicine 1999 Jan 1 (Vol. 29, No. 1, pp. 69-79)*. WB Saunders.
13. Welter S, Jacobs J, Krbek T, Tötsch M, Stamatis G. Pulmonary metastases of breast cancer. When is resection indicated?. *European Journal of Cardio-Thoracic Surgery*. 2008 Dec 1;34(6):1228-34.
14. El Ayass W, Sereika S, Van Londen G, Brufsky A. Predictors of progression of bone metastases in breast cancer patients. *Journal of Clinical Oncology*. 2009 May 20;27(15_suppl):e12011.