

A Rare Case of Vallecular Cyst

Dr. M. Jayanth^{1*}, Dr. I. Venkatraman², Dr. M.Prabakaran³

¹Resident, Sree Balaji Medical College, 7, Work's Road, Chrompet, Chennai, Tamilnadu, India

²Professor, Sree Balaji Medical College, 7, Work's Road, Chrompet, Chennai, Tamilnadu, India

³Professor & HOD, Sree Balaji Medical College, 7, Work's Road, Chrompet, Chennai, Tamilnadu, India

Case Report

*Corresponding author

Dr. M.Jayanth

Article History

Received: 04.04.2018

Accepted: 13.04.2018

Published: 30.04.2018

DOI:

10.36347/sjams.2018.v06i04.048



Abstract: A vallecular cyst is rare and benign lesion, it is more frequent in supraglottic locations, such as epiglottis and vallecula. The symptoms of a vallecular cyst include voice changes, dysphagia, stridor and shortness of breath. Vallecular cysts can be diagnosed by using plain radiography, computed tomography (CT), ultrasonography or magnetic resonance imaging (MRI) scan, MRI scan proves superior and is highly recommended to diagnose and to obtain thorough information regarding the relationship of the cyst to the surrounding anatomical structures and it helps to determine the further course of treatment. We discuss here the clinical presentation, radiographic findings and various treatment options for vallecular cyst.

Keywords: Vallecular cyst, epiglottis, dysphagia, CT, MRI.

INTRODUCTION

It is a benign cyst and its aetiology is unknown. In adults, its incidence is very rare. They arise due to obstruction of the mucous gland duct. Ductal cysts are usually small, approximately 1 – 5 mm in diameter [1].

Adult vallecular cysts are frequently asymptomatic and symptoms may include globus, voice changes, dysphagia, hoarseness and airway obstruction.

Vallecular cysts are common in infants and these infants are considered to be at risk of airway obstruction and death. The vallecular cysts on laryngoscopy has incidence of 1 in 1,250 to 1 in 4,200 [2].

CASE PRESENTATION

A 42 year male was referred to our department with complaint of voice change and snoring since 2 yrs. Patient also complained of regurgitation and breathing difficulty. There was no history of fever, odynophagia or dysphagia. Clinically there was no palpable lymphnode or mass in the neck.

Indirect laryngoscopy was done which revealed smooth bulge seen in hypopharynx. On video

laryngoscopy a smooth mass was seen in oro-pharynx. Epiglottis and vocal cords were not visualized. And the patient was advised plain radiograph neck.

Plain radiograph of neck was obtained in antero-posterior and lateral views. X ray antero-posterior and lateral view showed a well-defined soft tissue opacity in the left supraglottic region just above the level of hyoid bone and extending posteriorly upto the posterior wall of hypopharynx and closely abutting it (Fig-1).

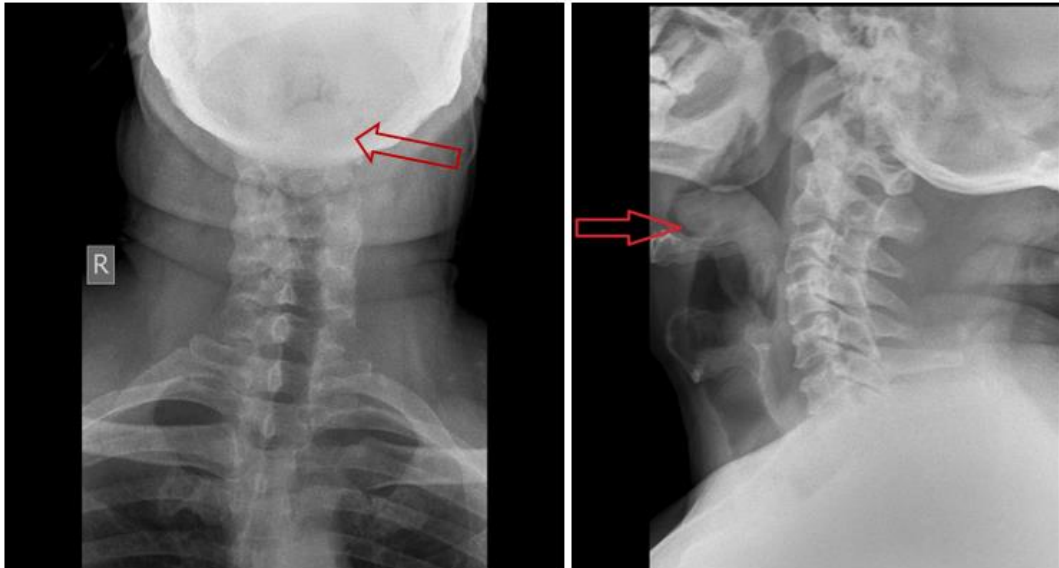


Fig-1: Plain radiograph neck AP & lateral views showing a well-defined soft tissue opacity in the left supraglottic region just above the level of hyoid bone and extending posteriorly upto the posterior wall of hypopharynx and closely abutting it

For further evaluation contrast enhanced CT neck. CT revealed a well- defined ovoid non-enhancing soft tissue density (40-45 HU) lesion was noted occupying the lower oropharynx and superior aspect of laryngopharynx causing near complete

occlusion of the airway at that level. Anteriorly the lesion was seen occupying the left vallecula and extending across the midline towards the right. Epiglottis could not be seen separately from the lesion (Fig-2).

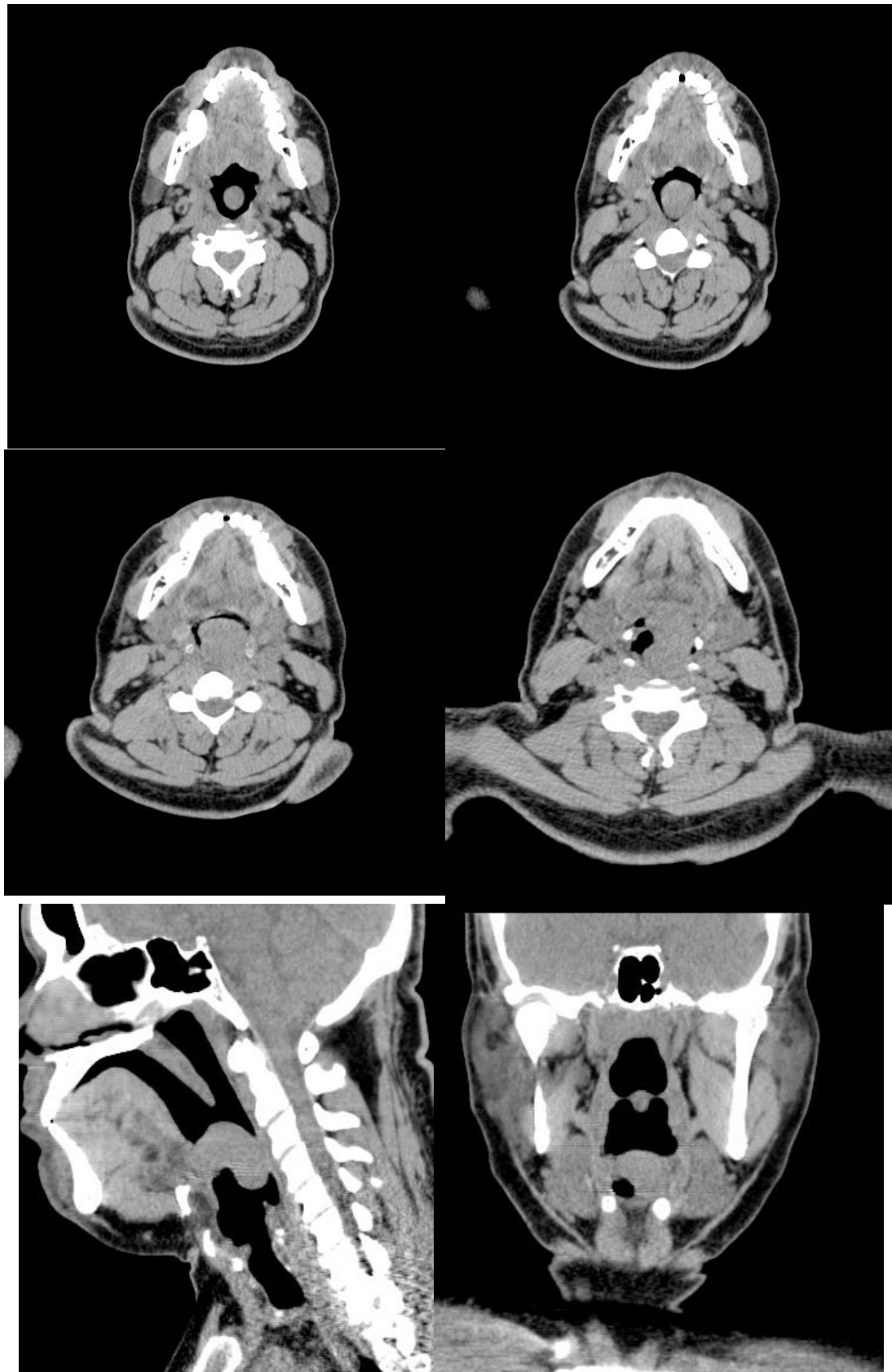


Fig-2: NCCT (Non contrast computed tomography) NECK showing a well- defined ovoid soft tissue density lesion occupying the lower oropharynx and superior aspect of laryngopharynx causing near complete occlusion of the airway. Anteriorly the lesion was seen occupying the left vallecula and extending across the midline towards the right.

MRI neck was done following CT which showed a well- defined ovoid lesion occupying the lower oropharynx and superior aspect of

laryngopharynx. Lesion was hypointense on T2 and heterogeneously hyperintense on T1.

USG neck showed multiple floating internal echoes within the lesion.

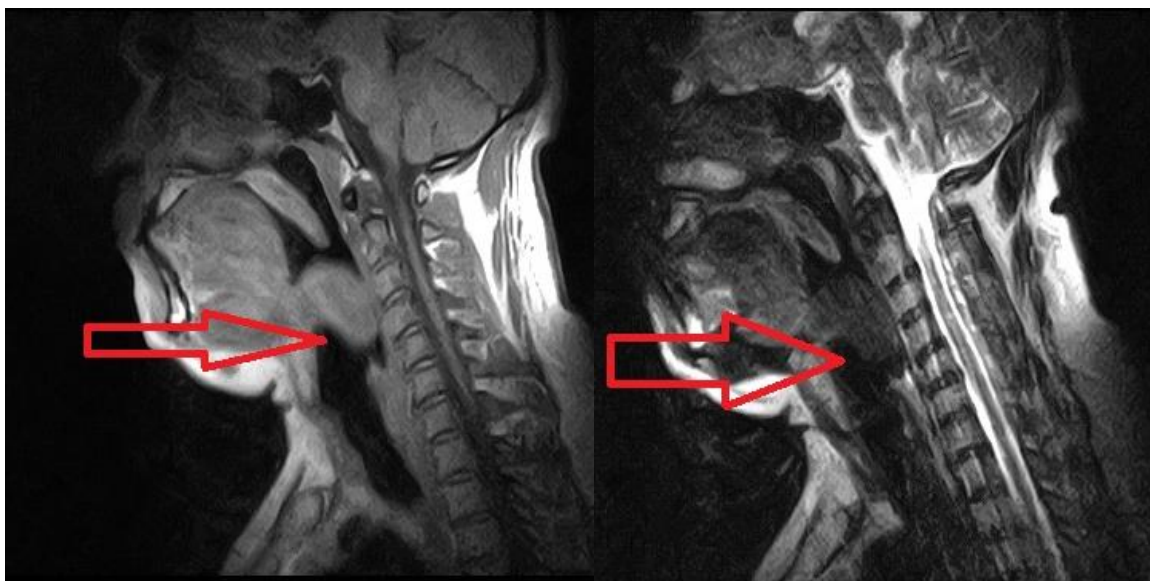


Fig-3: MRI neck sagittal section shows a T1 hypointense and T2 hyperintense ovoid lesion occupying the lower oropharynx and superior aspect of laryngopharynx.

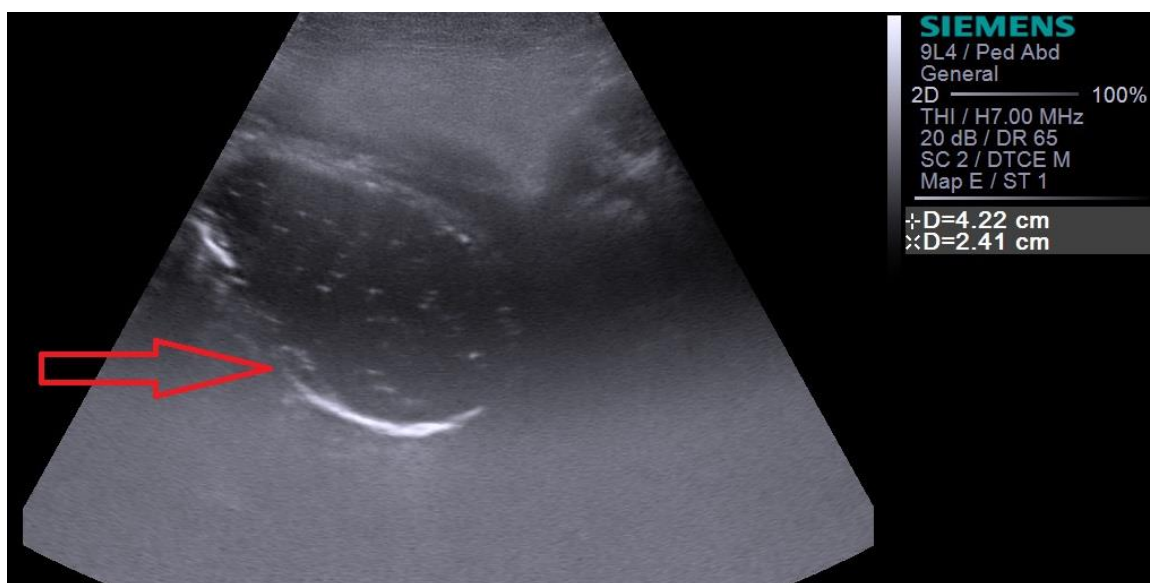


Fig-4: USG neck showing hypoechoic ovoid lesion with internal echoes in lower oropharynx.

DISCUSSION

Laryngeal cysts are rare laryngeal lesions. It is estimated that 10.5% of laryngeal cysts occur in the vallecular space [1]. Vallecular cysts (VC) have been reported in literature under other names, such as mucus retention cyst, pre-epiglottic cyst, epiglottic cyst, base of the tongue cyst, and ductal cyst. This is probably due to the confusion surrounding the pathogenesis and aetiology of this lesion. Adult patients with this condition have a benign course and present with symptoms of hoarseness of voice, foreign body sensation and dysphagia. Vallecular cysts are

common in infants and these infants are considered to be at risk of airway obstruction and death.

The incidence of vallecular cysts on laryngoscopy has been reported as 1 in 1,250 to 1 in 4,200, but the true estimate is difficult to estimate [3]. It is a benign cyst and its aetiology is unknown. VC is rarely seen in adults. Above were the imaging findings of the case in a middle aged male depicting the classical features of a vallecular cyst. They arise due to obstruction of the mucous gland duct. Ductal cysts are usually small, approximately 1 – 5 mm in diameter.

Adult vallecular cysts are frequently asymptomatic and symptoms may include globus, voice changes, dysphagia, hoarseness and airway obstruction [4].

Various treatment options are available. Vallecular cysts should be decompressed surgically and endoscopically. The cyst is either widely opened or removed using microlaryngeal instruments or a laser. Surgical excision of the cyst is the treatment of choice and, when performed in a timely manner, gives a good prognosis [5].

CONCLUSION

Vallecular cyst is a rare and benign condition and is associated with high morbidity and mortality. Diagnosis of vallecular cyst needs a multi-disciplinary approach as it is based on the clinical history, radiological investigations and pathological findings.

REFERENCES

1. Walshe CM, Jonas N, Rohan D. Vallecular cyst causing a difficult intubation. *British journal of anaesthesia*. 2009 Apr 1;102(4):565.
2. Berger G, Averbuch E, Zilka K, Berger R, Ophir D, Saba K. Adult vallecular cyst: thirteen-year experience. *Otolaryngology—Head and Neck Surgery*. 2008 Mar;138(3):321-7.
3. Rivo J, Matot I. Asymptomatic vallecular cyst: airway management considerations. *Journal of clinical anesthesia*. 2001 Aug 1;13(5):383-6.
4. Jahagirdar SM, Karthikeyan P, Ravishankar M. Acute airway obstruction, an unusual presentation of vallecular cyst. *Indian journal of anaesthesia*. 2011 Sep;55(5):524.
5. Sathish B. Case report: Innovative Surgical Technique in the Management of Vallecular cyst *JHAS Mangalore, South India*; 2003:2:2.