

A Rare Case of laryngeal nerve palsy and imaging findings

Dr. M. Jayanth<sup>1\*</sup>, Dr. M. S. Hehmnath<sup>2</sup>, Dr. M. Prabakaran<sup>3</sup>

<sup>1</sup>Resident, Sree Balaji Medical college, 7, Work’ S Road, Chrompet, Chennai, Tamilnadu, India

<sup>2</sup>Assistant Professor, Sree Balaji Medical college, 7, Work’ S Road, Chrompet, Chennai, Tamilnadu, India

<sup>3</sup>Professor & HOD, Sree Balaji Medical college, 7, Work’ S Road, Chrompet, Chennai, Tamilnadu, India

Case Report

\*Corresponding author

Dr. M. Jayanth

Article History

Received: 10.04.2018

Accepted: 20.04.2018

Published: 30.04.2018

DOI:

10.36347/sjams.2018.v06i04.053



**Abstract:** To evaluate the role of computed tomography imaging in laryngeal nerve palsy and in identifying the cause of it. The symptoms may vary from slight hoarseness to life-threatening airway obstruction. We discuss here the clinical presentation, radiographic findings and various treatment options for laryngeal nerve palsy.

**Keywords:** Laryngeal Nerve Palsy, hoarseness of voice, CT, airway obstruction

INTRODUCTION

The recurrent laryngeal nerve (RLN), also known as the inferior laryngeal nerve, is a branch of the vagus nerve (cranial nerve X) which has a characteristic loop around the right subclavian artery on the right and the aortic arch on the left before returning up to achieve the tracheo esophageal groove and then the larynx. It is located in superior mediastinum and the lower neck regions.

Laryngeal nerve palsy often occurs as a complication of thyroid surgery. Vocal cord paralysis may occur due to recurrent laryngeal nerve palsy, it can indicate the presence of mediastinal disease, including inflammatory, neoplastic and vascular conditions [1]. Upto 40 percent of patients with vocal cord palsy may be asymptomatic. The radiologist can suggest the presence of vocal cord paralysis with routine computed tomography of the neck, inspite of absence of history of hoarseness.

CASE PRESENTATION

74 year old male patient came with the complaints of hoarseness of voice since 6 months. On laryngoscopy examination, dilated lateral ventricle was seen. There was no evidence of mass lesion in the

larynx. Patient referred to CT for evaluation of laryngeal palsy.

CT Findings of Laryngeal Nerve Palsy:

CT Neck Plain at the level of larynx showing : dilated left lateral ventricle

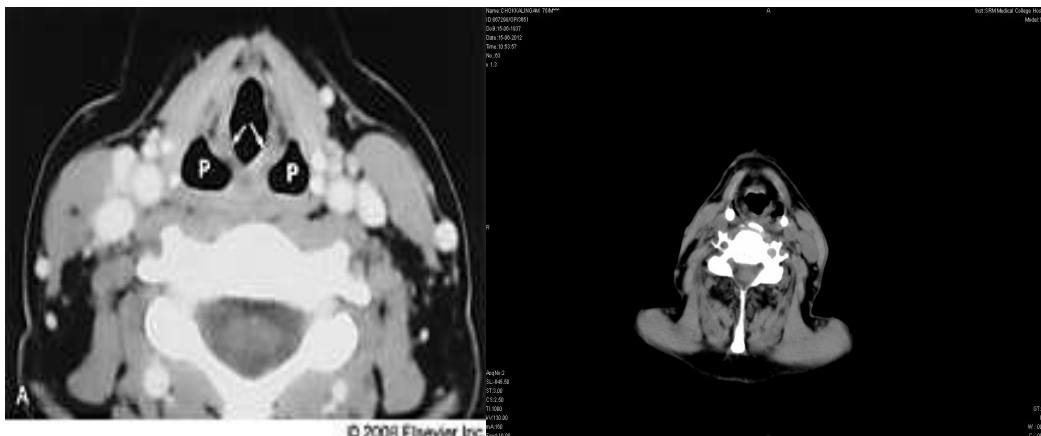
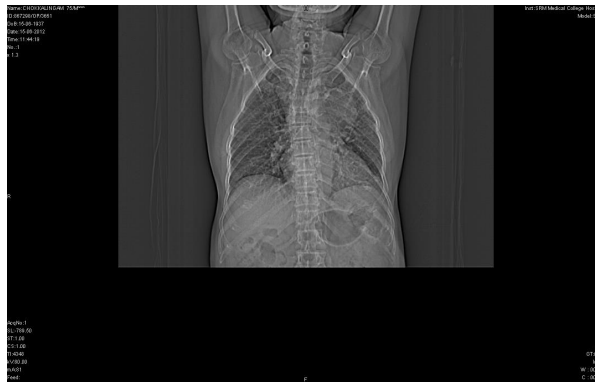
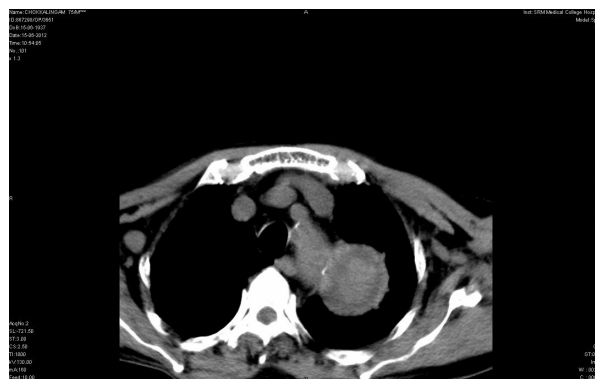

Fig-1: CT Scanogram showing: Heterogenous opacity in the left hilar region



**Fig-2: CT Chest Plain at the level of Aortic Arch showing: Aneurysm arising from the arch of aorta**



**Fig-3: Final Diagnosis: Dilated left lateral ventricle due to Left recurrent laryngeal nerve palsy caused by aortic aneurysm.**

## DISCUSSION

Paralysis of the larynx (voice box) caused by damage to the recurrent laryngeal nerve or its parent nerve, the vagus nerve, which originates in the brainstem and runs down to the colon. The right and left recurrent laryngeal nerves take different paths within the thorax because of developmental elongation of the brachial arch arteries with relative descent of the heart. The left recurrent laryngeal nerve has a longer course to the neck than the right side, because it hooks under the left sixth arch artery which persists in extra-uterine life as the ductus arteriosus, a fibrous remnant. Neither the sixth nor fifth arch arteries persist nor so are the recurrent laryngeal nerve restrained by the next most superior structure which is fourth branchial arch artery on the right. In rare cases, the right fourth branchial arch artery does not develop in the adult and instead, the right dorsal aorta of the fetus persists to supply the same territories [5]. Hence, the right recurrent laryngeal nerve is no longer restrained by a subclavian artery and so it divides from the vagus more superiorly to run inferiorly on the larynx, which may be transected during thyroid surgery. The recurrent laryngeal nerve supplies the larynx (voice box). The larynx will be paralyzed on the side where this nerve has been damaged, unless the problem originated with damage to the vagus nerve itself. Diseases inside the chest, such as a tumor, an aneurysm of the arch of the aorta, or an aneurysm of the left atrium of the heart can lead to damage of the recurrent laryngeal nerve. The

recurrent laryngeal nerve innervates the posterior cricoarytenoid muscle (one of the intrinsic muscles of the larynx) which is the sole abductor of the vocal folds. An indicator of RLN is atrophy of posterior cricoarytenoid muscle [3].

## CAUSES FOR RECURRENT LARYNGEAL NERVE PALSY

- Surgical iatrogenic injuries result in vocal fold paralysis such as thyroid surgery, anterior cervical disc surgery, carotid surgery or chest surgery.
- Skull base tumors, thyroid ca, lung ca, esophageal ca, and metastases to the mediastinum (often observed with lung cancer primaries), can occur with malignant invasion of the vagus or recurrent laryngeal nerve.<sup>[1]</sup>
- Trauma due to blunt injury in the neck or chest.
- Aortic Aneurysm
- Higher level causes include Bulbar palsy, Pseudo bulbar palsy, Jugular horn syndrome, Deep lobe parotid tumour and Vagal neurolemma [2]. When a clear-cut etiology for the unilateral vocal fold paralysis (UVFP) is not found, it is classified as idiopathic. It can also be due to a viral or inflammatory process, but this is usually a presumptive diagnosis [2].

## CONCLUSION

Laryngeal nerve palsy often occurs as a complication of thyroid surgery. Diagnosis of laryngeal

nerve palsy is based on clinical history and radiological investigation. Radiologists can avoid missing causative lesions, many of which are of greater significance to the patient than is the vocal cord palsy itself, by understanding and assessing the entire course of the vagus nerves and recurrent laryngeal nerves, including their mediastinal segments [4]. Early diagnosis and treatment is required.

#### **REFERENCES**

1. Yumoto E, Minoda R, Hyodo M, Yamagata T. Causes of recurrent laryngeal nerve paralysis. *Auris Nasus Larynx* 2002;29(1):41–45.
2. Ramadan HH, Wax MK, Avery S. Outcome and changing cause of unilateral vocal cord paralysis. *Otolaryngol Head Neck Surg* 1998;118(2):199–202.
3. Romo LV, Curtin HD. Atrophy of the posterior cricoarytenoid muscle as an indicator of recurrent laryngeal nerve palsy. *AJNR Am J Neuroradiol* 1999;20(3):467–471.
4. Frija J, Bellin MF, Laval-Jeantet M. CT mediastinum examination in recurrent nerve paralysis. *J Comput Assist Tomogr* 1984;8(5):901–905.
5. Myssiorek D. Recurrent laryngeal nerve paralysis: anatomy and etiology. *Otolaryngol Clin North Am* 2004;37(1):25–44.