

A Comparative Evaluation of the Addition of Clonidine or Dexmedetomidine to Levobupivacaine at Tertiary Care Centre of Central India

Dr. Ravi Barde¹, Dr. Jitendra Zilve^{2*}

¹Senior Resident, Dept. of Anaesthesiology, Employees State Insurance Corporation, Model Hospital Nanda Nagar, Indore, Madhya Pradesh, India

²Senior Resident, Department of Anaesthesiology M.G.M Medical College and M. Y. Hospital, Indore, Madhya Pradesh, India

Original Research Article

*Corresponding author

Dr. Jitendra Zilve

Article History

Received: 11.04.2018

Accepted: 20.04.2018

Published: 30.04.2018

DOI:

10.36347/sjams.2018.v06i04.075



Abstract: Adjuncts to local anaesthetics for brachial plexus block may enhance the quality and duration of analgesia. Clonidine, an Alpha-2 adrenergic agonist, is known to produce ant nociception and enhance the effect of local anaesthetics when given epidurals, intrathecal or in various peripheral nerve blocks. Levobupivacaine is a local anaesthetic drug belonging to amino amide group. It is the s. enantiomer of bupivacaine. Levobupivacaine has a greater margin of clinical safety with respect to both CVS AND CNS effects as compared to racemic bupivacaine. Dexmedetomidine, a selective α 2-adrenoceptor agonist, has been used as an adjuvant during regional and local anaesthesia. The primary end points are the onset and duration of sensory and motor block and duration of analgesia. The purpose of this study was to assess the effect of Clonidine or dexmedetomidine, added to Levobupivacaine in brachial plexus block by supraclavicular approach. Dexmedetomidine (1 μ g/kg) in combination with 29mL of levobupivacaine (0.5%) hastened onset of sensory and motor block, and improved postoperative analgesia when used in brachial plexus block, without producing any adverse events.

Keywords: Dexmedetomidine; Clonidine & Levobupivacaine.

INTRODUCTION

Acute postoperative pain is the result of a complex physiological reaction to tissue injury. The dorsal horn of the spinal cord is the site of termination of primary afferents and there is complex interaction between such afferent fibers, intrinsic spinal neurons, descending pain modulating fibers, and various associated neurotransmitters such as serotonin, norepinephrine, acetylcholine, adenosine, and glutamate in the dorsal horn [1].

Levobupivacaine is a local anesthetic drug belonging to the amino amide group. It is the s. enantiomer of bupivacaine. Previous studies have shown levobupivacaine to have a greater margin of clinical safety with respect to both CVS AND CNS effects when compared with racemic bupivacaine [3, 4].

Our study of dexmedetomidine is comparable with Saria S Swami *et al.* [8] whose study shows Dexmedetomidine when added to local anesthetic in supraclavicular brachial plexus block enhanced the duration of sensory and motor block and also the duration of analgesia. The time for rescue analgesia was prolonged in patients receiving dexmedetomidine. It also enhanced the quality of block as compared with clonidine [2].

AIM AND OBJECTIVES

A Comparative Evaluation of the Addition of Clonidine or Dexmedetomidine to Levobupivacaine at Tertiary Care Centre of Central India

MATERIALS AND METHODS

This study was conducted on 60 patients undergoing upper limb surgeries aged between 20 to 50 years under supraclavicular block in Tertiary Care Centre of Central Part of India. Informed written consent was obtained. Result values were recorded using a preset proforma.

Inclusion criteria

- ASA Class I & II
- Age between 20 to 50 years.
- SBP: 100- 139mm of Hg.
- DBP: 60-89mm of Hg.

- Both male and female patients.

Exclusion criteria

- Patients refusing to give consent.
- Patients with history of bleeding disorders.
- Patients with local infection at the site of block.
- Patients with documented neuromuscular disorders.
- Patients with respiratory compromise.
- Patients with known allergy to local anaesthetic drugs.
- ASA grade III and IV patients.
- Patients with heart block.

Investigations Required

- Hb%, TLC, DLC, BT, CT.

- Urine routine microscopy.
- RBS, Blood urea and serum creatinine.
- Chest x-ray, ECG.
- HIV, HBsAg.

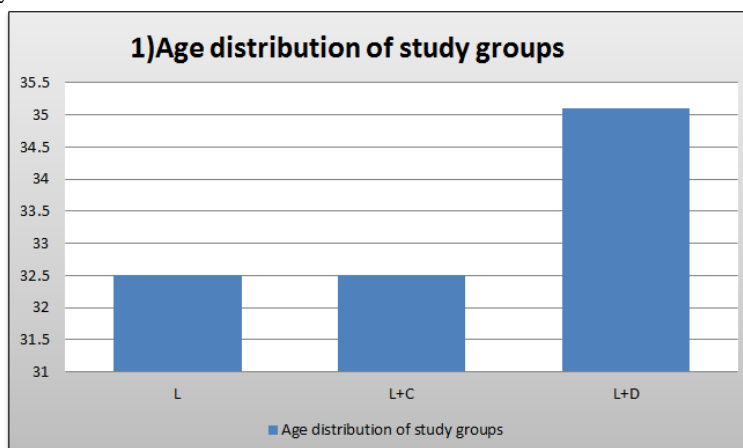
OBSERVATIONS & RESULTS

Sixty patients ASA I and II of either sex aged between 20-50 years, posted for upper limb surgeries under supraclavicular brachial plexus block were selected for the study. The study was undertaken to evaluate the efficacy of Clonidine (1µg/kg) and dexmedetomidine (1µg/kg) as adjuvant to levobupivacaine (0.5%) in comparison with plain levobupivacaine (0.5%) for brachial plexus block by supraclavicular approach.

Table-1: Age distribution of study groups

GROUPS	mean± SD(standard deviation)	P value
L	32.5±10.440	0.572
L+C	32.5±7.214	
L+D	35.1±8.854	

- On applying one way ANOVA test



The minimum age of the patient was 20 years and the maximum age was 50 years. The mean age of the patients in group L was 32.50 ± 10.440, in group L+C was 32.50 ± 7.214 years and in group L+D was

35.10 ± 8.854. Age incidences between three groups were comparable.

DESCRIPTIVE TABLE

Table-2: Showing the onset of sensory block in different groups (n=20)

GROUPS	Mean	Std. Deviation	Std. Error	ANOVA	
				F value	P value *
L	13.50	.607	.136	250.631	<0.001
L+C	10.55	1.317	.294		
L+D	6.85	.745	.167		
Total	10.30	2.895	.374		

DISCUSSION

Brachial plexus block provides postoperative analgesia of short duration, even when a long-acting local anesthetic like levobupivacaine is used alone. Various drugs like opioids, midazolam, neostigmine

and hyaluronidase have been evaluated in conjunction with local anesthetics to prolong the period of analgesia, but they were found to be either ineffective or to produce an unacceptably high incidence of adverse effects. Clonidine is known to produce ant

nociception and to enhance the effect of local anesthetic when administered intrathecal and epidurals. Clonidine produces this effect by its action on Alpha 2 adrenergic receptors found in peripheral nerves. Dexmedetomidine, a selective α_2 -adrenoceptor agonist, has been used as an adjuvant during regional and local anesthesia. The primary endpoints are the onset and duration of sensory and motor block and duration of analgesia [7]. Hence an attempt has been made to assess the efficacy of dexmedetomidine as an adjuvant to levobupivacaine (0.5%) in brachial plexus block (supraclavicular approach) in terms onset time, duration of analgesia and sedation. Hemodynamic variables and rescue analgesic requirements in first 24 hours was also studied.^{5&6}

A total of 60 patients within the age group of 20-50yrs. were included in the study, 20 in each group. Out of which the mean age of group L (receiving only Levobupivacaine) was 32.50 \pm 10.440 years and the mean age of group L+C (receiving Clonidine with Levobupivacaine) was 32.50 \pm 7.215 years and the mean age of group L+D. was 35.10 \pm 8.855. Hence all three groups were comparable with regard to age. Male to female ratio was almost same [7].

In our study we found that the onset of sensory and motor blocks was significantly faster in patients who received a combination of Dexmedetomidine and Levobupivacaine. Onset of sensory block (group L, 13.50 \pm 0.607 min; group L+C, 10.55 \pm 1.317 min, group L+D 6.85 \pm 0.745min). Onset of motor block (group L, 16.55 \pm 0.605 min; group L+C, 15 \pm 0.973 min, group L+D 13.25 \pm 0.550min).

This could be due to a local direct action of dexmedetomidine and its synergistic action with that of local anesthetics.

CONCLUSION

Dexmedetomidine(1 μ g/kg) in combination with 29mL of levobupivacaine (0.5%) hastened onset of sensory and motor block, and improved postoperative analgesia when used in brachial plexus block, without producing any adverse events.

REFERENCES

1. Atkinson RS, Rushwan GB, Lee AJ. Regional technique. 10th ed. Chapter 31. Synopsis of Anaesthesia; 1987. pp. 593-4.
2. Raj PP. Historical aspects of regional anaesthesia. 1st ed. Chapter 1. In: Text Book of Regional Anaesthesia; 2002 May. p. 3
3. Burlacu CL, Buggy DJ. Update on local anesthetics: focus on levobupivacaine. Therapeutics and Clinical Risk Management 2008; 4: 381-92.

4. Bhatt SH. Levobupivacaine. A stereoselective amide local anaesthetic Journal of the Pharmacy Society of Winconsin 2001; 34:28- 34.
5. Cline E, Franz D, Polley DR. Analgesia and effectiveness of levobupivacaine compared with ropivacaine in patients undergoing an axillary brachial plexus block. AANA Journal 2004; 72:5.
6. Piangatelli C, De CA, Pecora L, Recanatini F, Cerchiara P, Testasecca D. Levobupivacaine and ropivacaine in the infraclavicular brachial plexus block. Minerva anesthesiologica. 2006 Apr;72(4):217-21.
7. Aliye E, Fusun Y, Aynur A, Cemil Y. Dexmedetomidine Added to Levobupivacaine Prolongs Axillary Brachial Plexus Block. Anesth Analg-2010, Dec; 111(6):1548-51.
8. Swami SS, Keniya VM, Ladi SD, Rao R. Comparison of dexmedetomidine and clonidine (α_2 agonist drugs) as an adjuvant to local anaesthesia in supraclavicular brachial plexus block: A randomised double-blind prospective study. Indian journal of anaesthesia. 2012 May;56(3):243.