

Sigmoid Perforation Following A Fracture of the Acetabulum: About A Case and Review of the Literature

A Krite*, H Abid, M ElIdrissi, A Ellbrahimi, A ElMrini

Surgery Traumatology-Orthopedic B4 University Hospital Hassan II of Fez Morocco

DOI: [10.36347/sjams.2020.v08i03.033](https://doi.org/10.36347/sjams.2020.v08i03.033)

| Received: 25.02.2020 | Accepted: 06.03.2020 | Published: 21.03.2020

*Corresponding author: Dr. Ali Krite

Abstract

Case Report

Injuries sigmoid colon or pelvic associated with acetabular fractures colon have a prevalence of less than 3%. Even more exceptional appear directly colonic perforation by bone trauma since a case was found in the literature. This is the mechanism that has been retained in the comments submitted. This case told us evoke a digestive lesion in a pelvic trauma (usually a severe polytrauma) with unexplained infectious syndrome. The use of imaging (CT abdominopelvic) avoids diagnostic delay may jeopardize the vital prognosis of the patient.

Keywords: Acetabular fracture, perforation, sigmoid, multiple trauma, life-threatening.

Copyright @ 2020: This is an open-access article distributed under the terms of the Creative Commons Attribution license which permits unrestricted use, distribution, and reproduction in any medium for non-commercial use (NonCommercial, or CC-BY-NC) provided the original author and source are credited.

INTRODUCTION

Direct sigmoid perforation by a bony shell during acetabular fractures was published only once in the literature and this by Prof. J. Proust *et al.* At the Digestive Surgery Department, University Hospital Dupuytren.

The literature reported cases of sigmoid lesions associated with rupture of the pelvic ring, more rarely isolated acetabular fractures, bone without any perforation Flake is cited Dalal *et al.* [1]. This however was affirmed as suggested by our observation below.

OBSERVATION

A patient, aged 43, suffered a fall of 5 meters with lateral direct blow to the left iliac region. The initial examination on admission to hospital shocking room was a stable patient hemodynamically stable, with a GCS score 15 hemodynamically respiratory and conjunctive slightly discolored, clinical examination is an intense pain in left hip and a sensitivity of the left iliac fossa. With a total functional disability of the lower left limb. There is no note of paralysis of the sciatic nerve or vascular and nerve damage.

Radiographs of the pelvis (front, 3/4 and 3/4 Alaire shutter) objectified a fracture of the posterior column carrying the posterior wall and the anterior left column is a bicolonnale a complex fracture without

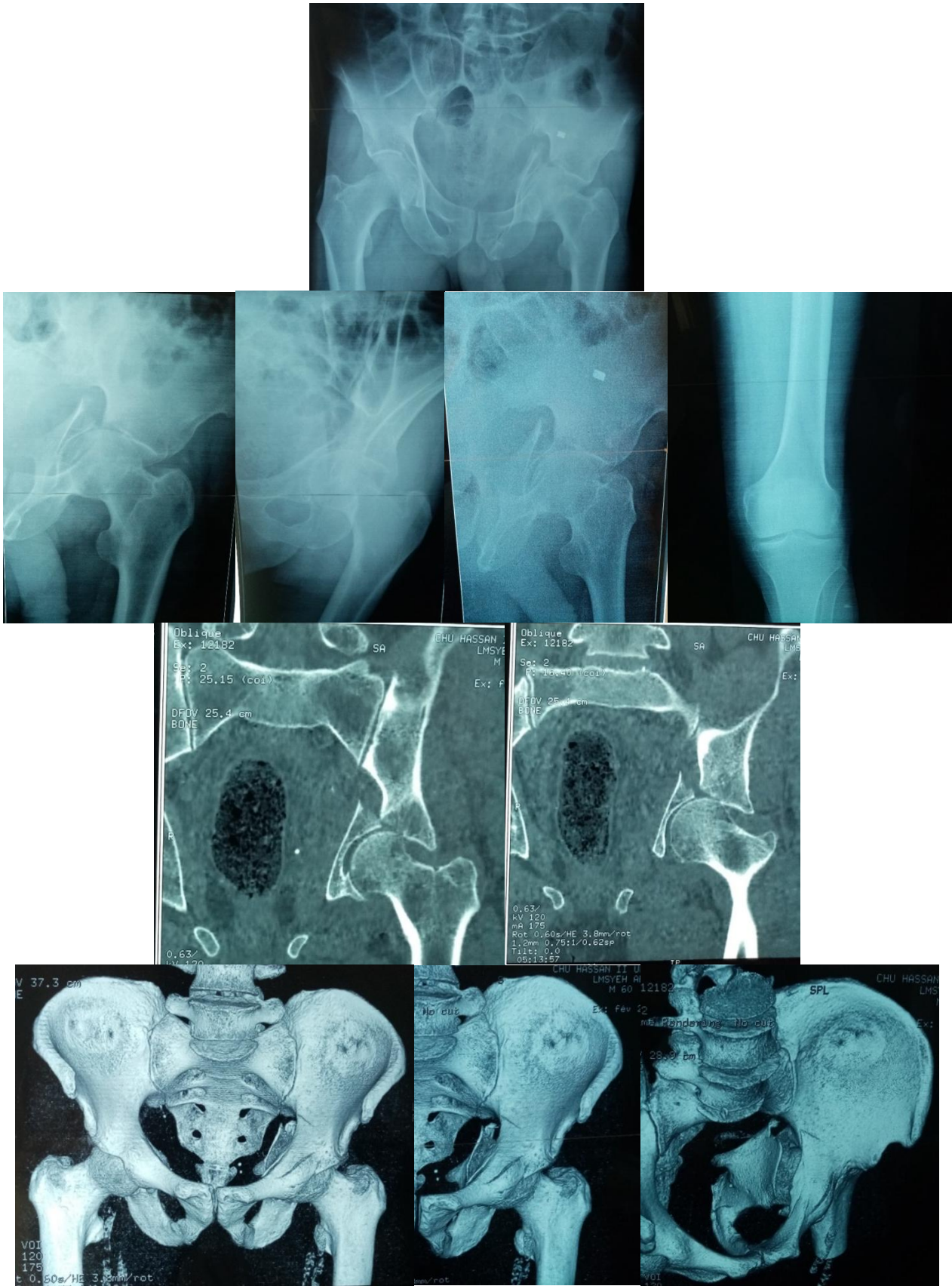
breaking the pelvic ring according classification Sir Letournel (fig. 1).

Radiography abdomen without preparation (ASP left lateral decubitus) revealed no abnormality and in particular no pneumoperitoneum (Fig.2).

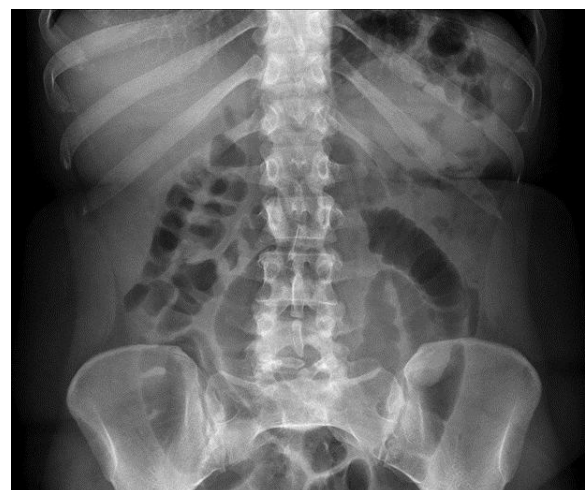

Fig-2: normal x-ray of the abdomen without preparation

Abdominal ultrasound was normal. The CT scan of the acetabulum confirmed diagnosis and better characterization of the fracture (Fig 3 a, b, c, d, e, f, G h; i; j; k, l).



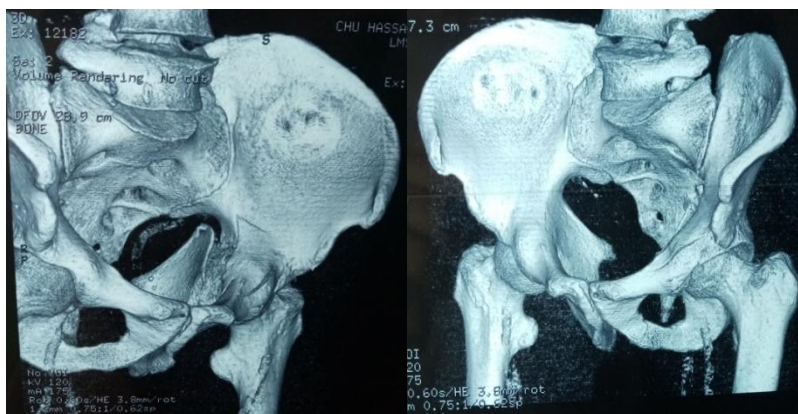


Fig- 3: Patient Radiation Assessment made Basin Radiography face Alaire 3/4 and 3/4 shutter and a left knee radiography (unremarkable) and a pelvic scan with coronal and 3D reconstructions objectifying fracture column moved posterior and fracture the anterior column of the non-displaced acetabulum

The patient underwent a trans-femoral condylar bone strength left sedated for ten days with 1/10 weight of the patient at the surgical ICU and surgical treatment was proposed from the 10th of trauma.

However, abdominal pain reappeared at the 3rd day, predominant in the left iliac fossa. Physical examination revealed a localized defense of the left iliac fossa, decreased bowel sounds. The patient was febrile

at 39.5 °. Leukocytosis neutrophils was demonstrated with a 120 CRP.

The abdomen without preparation objectified pneumoperitoneum and the abdominopelvic CT revealed an irregular appearance of the sigmoid colon show a suffering of the latter with signs that suggest perforation of the posterior wall of the sigmoid (Fig. 4a, b, c) .Gastrointestinal perforation was suspected, by asking the indication of an exploratory laparoscopy.

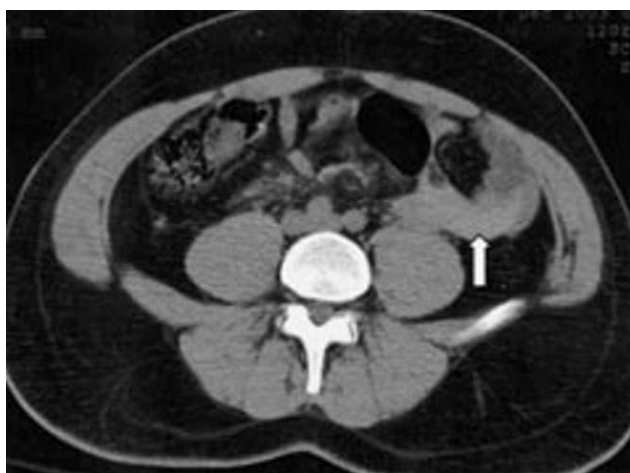

Fig-4a: Infiltration of the root of the mesentery and spontaneously hyperdense liquid in the left iliac fossa

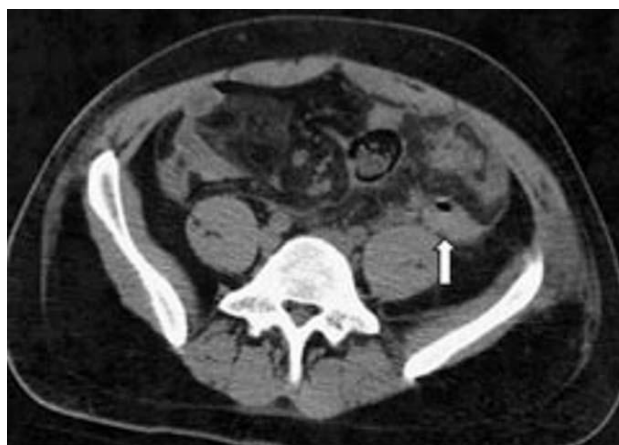

Fig-4b: Increase in the diffuse infiltration of the mesentery. gas appearance in the hematoma of the left iliac fossa

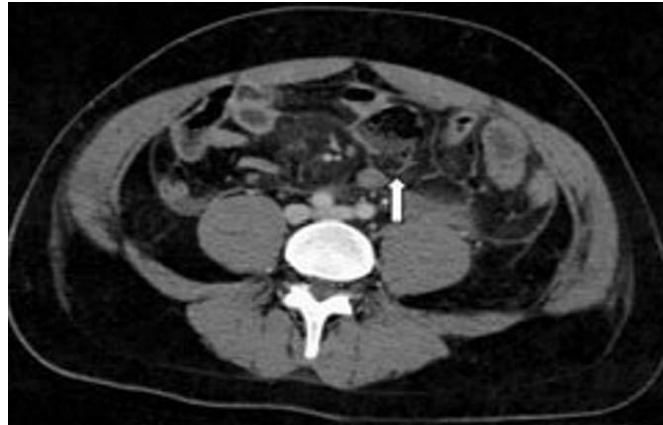

Fig-4c: localized interruption of the posterior wall of the sigmoid signing traumatic perforation site

This was done on the same day or the third day after the accident and who has objectified intraperitoneal effusion but recent inflammatory adhesions épiplo-parietal in the left iliac fossa. The sigmoid colon was dissécable difficult because of the inflammatory reaction. Laparoscopy was converted to laparotomy. The already displayed inflammatory area was organized around a fécaloïde collection. After initially progressive in the region, sigmoid perforation was highlighted. She stood at the left posterolateral aspect of the sigmoid and measured about 1.5 cm in diameter. She sits next to a wound of 2 cm in the posterolateral portion of the pelvic wall, through which a bone fragment protruded.

The postoperative course was simple antibiotic therapy with penicillin G and metronidazole. Regarding the fracture, surgical treatment was carried out by a special fixation with acetabular bone plate by way of Kocher Langenbeck and this has j15 of the digestive surgery after a good clinical and biological and radiological (and fig5 fig6a, b).

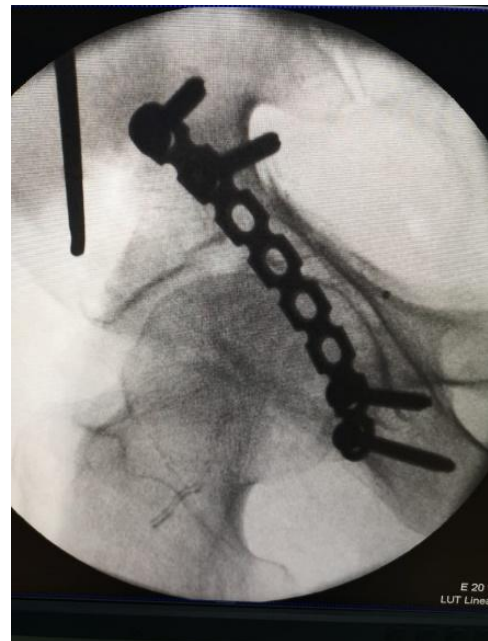


Fig-6a: intraoperative fluoroscopic control

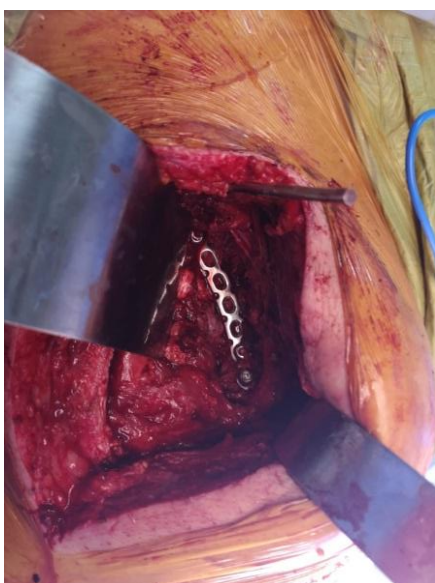

Fig-5: Osteosynthesis view of the acetabulum by special plate acetabulum

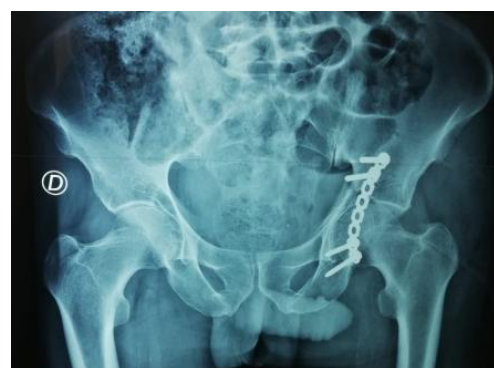

Fig-6b: post-operative radiological control

The consolidation was achieved by 4 months. A year after the accident, the patient had a functional level according to the Merle d'Aubigné score [4] evaluated at 15 and a Harris score [5] 87/100. There was no sign of femoral head osteonecrosis, joint space was normal.

DISCUSSION

Consecutive colonic perforation to a fracture of the acetabulum or pelvis are rare. Those related to an isolated fracture of the acetabulum are more. Letournel and Judet [8] described in their series of 940 fractures of the acetabulum, 5.4% of visceral lesions (thoracic and abdominal) associated above all related to trauma and not with acetabular fractures. Duquennoy *et al.* [4] reported no digestive lesion on 433 acetabular fractures. Nordin [7] quotes 20% of abdominal injuries on 675 pelvic fractures.

Colonic perforation here seems caused by a bone fragment protruding behind the contiguous portion of the sigmoid. A similar case was published.

The mechanisms of occurrence of colonic lesions are numerous. The effect of shear at the junction between the fixed and the movable extraperitoneal colon colon intraperitoneal, causes devascularization and thus ischemic necrosis and perforation according lamina [8]. The third mechanism mentioned crushing of the gastrointestinal tract between the spine and a blunt object.

Dauterive *et al.* [9] have described colonic perforations of consecutive free edge to a sudden increase in intra-abdominal pressure.

For Dalal *et al.* [1], the intensity of trauma would affect the type of injury associated with the fracture. In a study involving 343 fractures of the pelvis, there were less than 4% of colonic lesions in the disjunctions fractures fracture without associated pelvic and acetabular less than 1% in the disjunctions basin associated with a fracture of the acetabulum Dalal *et al.* [1].

This digestive complication was less common complications described in this study. There was no wound colic associated with an isolated fracture of the acetabulum Dalal *et al.* [1].

The fracture mechanism was, according to the classification of Pennal *et al.* [10], anterior-posterior or lateral, the rate of complications colic was the same. It was lower in the frontal-vertical mechanisms as well as the combined mechanisms. The stronger the trauma was, the greater the percentage of colonic lesions increased with a higher incidence for high energy side mechanisms with respect to anteroposterior mechanisms [1]. In our case, it was a likely colonic trauma by direct contact between the sigmoid wall and the fractured bone.

Eight publications include nineteen consecutive cases of gastrointestinal perforations to rupture of the pelvic ring. The wounds of the distal rectum or anal canal are the most common. A series reported four traffic accidents involving a broken pelvis

and without describing injury anorectum Roche *et al.* [11]. Leenen *et al.* [12] report fourteen pelvic fractures, complicated by various injuries including eight include a fracture of the acetabulum.

Among the associated lesions, they find new anorectal perforations. Colic wounds are rare. A case of perforation of the sigmoid secondary to a disjunction fracture joint left sacroiliac described by Shapiro and Wolverson [13]. Hughes [14] relates a case of perforation of the free edge of the colon at the rectosigmoid junction associated with a fracture of the pelvis and femur. A case of colonic wound associated with a hernia of the abdominal wall occurred during a pelvic fracture is quoted by Walcher *et al.* [15]. Naam *et al.* found [15] three cases of colic perforations associated with a fractured pelvis. However, there is a case of colonic perforation on isolated fracture of the acetabulum.

The evolution of post traumatic gastrointestinal damage can take two directions.

- The first is symptomatic perforation immediate or secondary manner (within 48 to 72 hours as in our patient).
- The second is that of stenosis following ischemic changes in the bowel wall [10-12].

A late diagnosis of gastrointestinal involvement is observed frequently. Shapiro [13], about a case discovered puncture one week before the accident in a second procedure, the serving perforation at the rear face of the sigmoid, the collection was formed in the retroperitoneum and was thus unnoticed during the first intervention.

In our case, the diagnosis was made on the third day of the accident. Two hypotheses can explain the delay of onset of clinical signs. The first is the existence of an initial colonic bruise which would secondarily perforate. This would explain the lack of abnormality on ASP and ultrasound done early. The second hypothesis is the existence of a perforation secondary decompensated bite.

Once the diagnosis of digestive complications fact, his treatment done, it must, if it has not already been done, treat the fracture. The question of choice of treatment, orthopedic and osteosynthesis (internal or external), course depends on the type of fracture but also the septic risk related to gastrointestinal lesions hence the need for discussion among orthopedic and gastrointestinal surgeon for better therapeutic care.

The radiological assessment based on CT: it permits visualization of telltale signs of lesions of the gastrointestinal tract [3, 4]. In three quarters of cases, abdominal digestive lesions are accompanied by an effusion fluid intra-abdominal [14]. This effusion is more suggestive of gastrointestinal lesions that an

absence of traumatic injury of solid organs (liver, kidneys and spleen). This effusion is localized in the hypochondria, in paracolic gutters and in the pelvis, but also between the bowel loops. The presence of a pneumoperitoneum (or retroperitoneum), although it is inconstant is a cardinal sign of gastrointestinal perforation. Other more subtle signs are suggestive of a gastrointestinal trauma.

Surgical treatment is proved in case of perforation, in case of detection of focal parietal anomaly or active bleeding and hematoma adjacent to digestive handles. The zonal infiltration of the mesentery and / or a small amount of free liquid intraabdominal can be monitored clinically.

CONCLUSION

Sigmoid perforation secondary to isolated acetabular fractures is extremely rare. The literature review found a case. The cases reported concern acetabular fractures associated with severance of the pelvic ring fractures or pelvic ring alone.

The usual complications of acetabular fractures that are hemorrhagic shock, retroperitoneal hematoma, should not obscure the surgeon as sigmoid colonic lesions in particular may also occur, especially as the trauma was severe.

We need to know this diagnosis before any signs of peritoneal irritation, unexplained fever or disorder of transit and to a balance sheet infectious rise without signs of Clinique call to appreciate the risk of infection to choose, for the fracture, type of adequate treatment.

REFERENCES

1. Butela ST Ferderle MP, PJ Chang. Performance of CT in detection of bowel injury. *Am J Roentgenol.* 2001; 176: 129- 35.
2. AE Hawkins, Mirvis SE. Evaluation of bowel and mesenteric injury: role of multidetector CT. *Abdom Imaging.* 2003; 28: 505-14.
3. Germain MA Soukhni N, Bouzard MD. Small bowel perforation after-blunt abdominal trauma: evaluation with computed tomography scan and laparoscopy. *Ann Surg.* 2003; 128: 258-61.
4. Crema MD, Arrived L-Cholley Monnier L, Tubiana JM. Hematoma intramural colonic traumatic. *J Radiol.* 2004; 85: 2039-41.
5. Yutan E Waitches GM Karmy-Jones R. Blunt duodenal rupture: Complementary roles of sonography and CT. *Am J Roentgenol.* 2000; 175: 1600.
6. Calen S, Moreno P, Nicolau H, Winnock S, January G, J. Videau Duodenopancreatic injuries. Diagnostic and therapeutic considerations of 25 squares. *J Chir (Paris).* 1987; 124: 263-71.
7. Hughes TMD, Elton C Hitos K. gastrointestinal tract intraabdominal injuries following blunt trauma: the experience of an Australian trauma center. *Injury.* 2002; 33: 617-26.
8. Brody JM Leighton DB Murphy BL. CT of blunt trauma bowel and mesenteric injury: typical Findings and pitfalls in diagnosis. *Radiographics.* 2000; 20: 1525-1536.
9. Uppot RN, Gheyi VK Gupta R. Intestinal perforation from blunt trauma to an inguinal hernia. *Am J Roentgenol.* 2000; 174: 1538.
10. Patrick WH Jeffrey MB. Blunt injury to small bowel mesentery and CT Evaluation. *Radiol Clin N Am.* 2003; 41: 1171-1182.
11. Tsushima Y, Yamada S, Aoki J. Ischemic ileal stenosis Following blunt abdominal trauma and Demonstrated by CT. *Br J Radiol.* 2001; 74: 277-9.
12. Lee Elliott C, W Landells, Keane A. Using CT to reveal traumatic ischemic stricture of the terminal ileum. *Am J Roentgenol.* 2002; 178: 403-4.
13. Livingston DH Lavery RF Passannante MR. Free fluid is abdominal computed tomography without solid organ injury after-blunt abdominal injury does not mandate celiotomy. *Am J Surg.* 2001; 182: 6-9.
14. Hahn DD, Offerman SR, Holmes JF. Clinical significance of intraperitoneal fluid in patients with blunt injury intra-abdominal. *Am J Emerg Med.* 2002; 20: 595-600.
15. Halvorsen RA, K. McKenney Blunt trauma to the gastrointestinal tract: CT Findings with small bowel and colon injuries. *Emerg Radiol.* 2002; 9: 141-5.