

# Diagnostic Usefulness of Tru-Cut Needle Biopsy in the Diagnosis of Palpable Breast Lump

Mahbuba Khatun<sup>1\*</sup>, Md. Mustafizur Rahman<sup>2</sup>, Md. Rafiqul Islam<sup>3</sup>, Md. Moktar Hossain<sup>4</sup>

<sup>1</sup>Assistant Professor, Department of Surgery, Ad-din Akij Medical College, Khulna, Bangladesh

<sup>2</sup>Principle & Head, Department of Surgery, Mugda Medical College & Hospital, Dhaka, Bangladesh

<sup>3</sup>Professor & Head, Department of Surgery, Ad-din Akij Medical College Hospital, Khulna, Bangladesh

<sup>4</sup>Associate Professor, Department of Pathology, Khulna Medical College, Khulna, Bangladesh

DOI: 10.36347/sasjs.2023.v09i09.013

| Received: 08.08.2023 | Accepted: 15.09.2023 | Published: 23.09.2023

\*Corresponding author: Mahbuba Khatun

Assistant Professor, Department of Surgery, Ad-din Akij Medical College, Khulna, Bangladesh

## Abstract

## Original Research Article

**Introduction:** Tru-cut biopsy is now one of the useful means of obtaining early and accurate histopathological diagnosis. It is easy and can be performed on an outpatient basis. It also avoids unnecessary excisional biopsy. **Objective:** To correlate findings of trucut biopsy in Diagnosis of Palpable Breast Lesions. **Material and Methods:** A cross sectional, observational study of one years conducted in Dept. Of Surgery, Shaheed Suhrawardy Medical College & Hospital, Dhaka, Bangladesh from January to December 2017. The study includes 100 patients of palpable breast lump. Trucut biopsy was performed using a Tru-Cut gun BARD MAX-CORE with an 18-gauge needle by means of 4 successive insertions with different angulations of the needle into the lesion's core. **Results:** The study includes 100 patients, Trucut Biopsy findings correlated with the histopathological findings in 97 of 100 cases (97.2%), which included 27 of 28 (96.4%) of the benign lesions and 71 of 72 (98.6%) of the malignant lesions. **Conclusion:** The results of this study suggest that TCB is an accurate, reliable and a safe method of establishing the diagnosis of cancer in patients with breast lesions. Our results yielded a high sensitivity of 95.65% with 96.88% specificity when compared with FNAC in the diagnosis of breast cancer especially when radiology is not diagnostic. Thus, trucut biopsy should replace fine needle aspiration in the preoperative assessment of suspicious breast lumps.

**Keywords:** Breast Cancer, Tru-Cut Biopsy.

Copyright © 2023 The Author(s): This is an open-access article distributed under the terms of the Creative Commons Attribution 4.0 International License (CC BY-NC 4.0) which permits unrestricted use, distribution, and reproduction in any medium for non-commercial use provided the original author and source are credited.

## INTRODUCTION

Breast cancer is the most common type of cancer in women [1]. It provides sufficient amount of tissue for pathologist to make an accurate histological diagnosis with its type, grade and degree of differentiation in majority of cases. To ensure an accurate diagnosis, the combination of a good clinical eye, high-quality imaging, and appropriate pathological techniques is important. For several years, fine needle aspiration cytology (FNAC) was the most practiced method for the pathological diagnosis of breast masses. FNAC became popular because of its accuracy, cost effectiveness, and ease of use [2-4]. Tru-cut biopsy of palpable breast lesions can provide all the reliable information to guide the surgeon and the oncologist to plan an ideal therapeutic strategy in surgical decision making [5]. And permits the eventual use of neoadjuvant therapy [6]. On the other hand, excisional biopsy would provide the pathologist with the whole breast lesion and allows him or her to examine its histopathological type,

grade and degree of differentiation of the carcinoma if present. Also receptor status for estrogen, progesterone and tyrosine kinas Her2 (C erb b2) can be assessed. However, it mostly requires general anesthesia [7, 8].

## MATERIAL AND METHODS

A cross sectional, observational study of one years conducted in Dept. Of Surgery, Shaheed Suhrawardy Medical College & Hospital, Dhaka, Bangladesh from January to December 2017. The study includes 100 patients of palpable breast lump. Trucut biopsy was performed using a Tru-Cut gun BARD MAX-CORE with an 18-gauge needle by means of 4 successive insertions with different angulations of the needle into the lesion's core.

## RESULTS

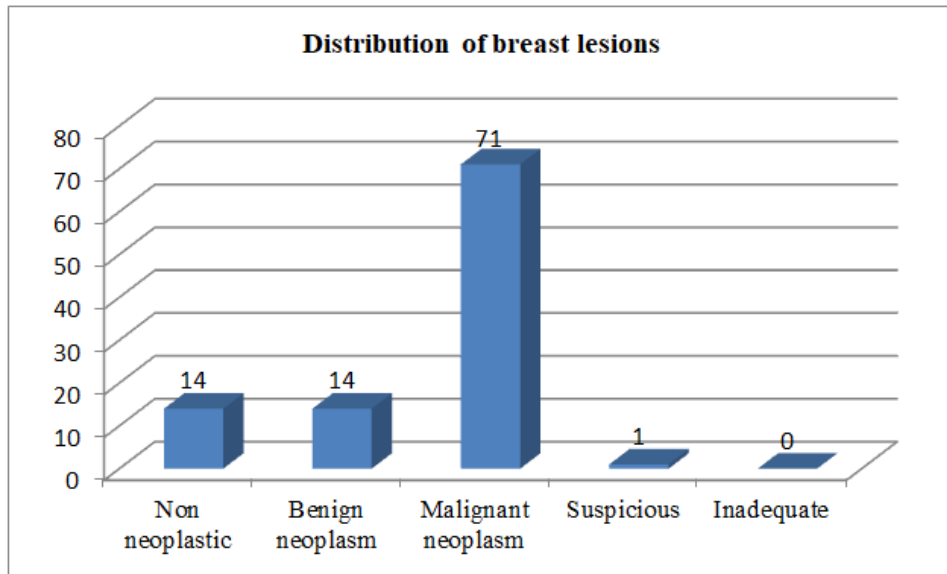
In the present study, majority of the patients (30%) were in the age group of 41-50 years followed by 24% in the age group of 51-60 years, 20% in the age group of 31-40 years, 14% in the age group of 21-30

years and 12% in the age group of >60 years. The most common clinical presentation in our study was a lump (91%) which was not associated with any other complaint (pain/ulcer). The left breast was affected in 49 (49%) patients while the right breast was affected in 50

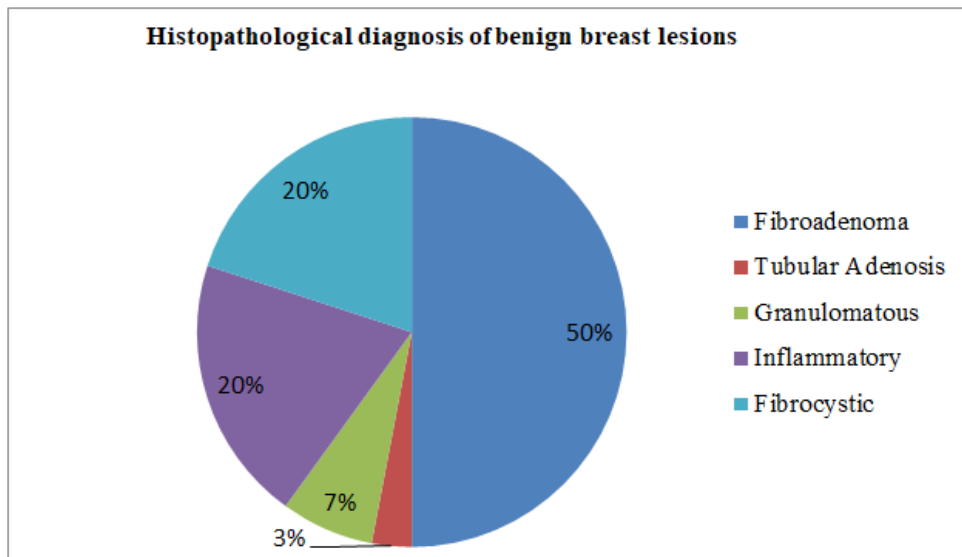
(50%) patients. Bilateral involvement was observed in 1 (1%) patient. In maximum cases (60%), the lump measured between 3-5cms while in minimum (6%) cases, it measured <3 cms.

**Table-1: Distribution of breast lesions on Trucut biopsy according to different CNB categories (N=100)**

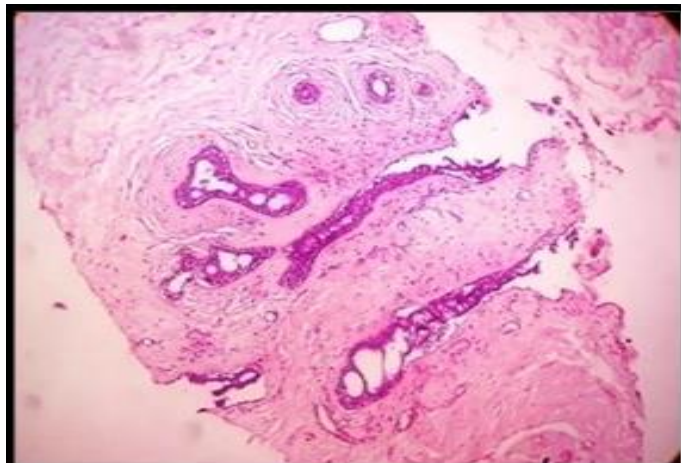
Category	N	%
B1	0	-
B2	28	28.0%
B3	0	-
B4	1	1.0%
B5	71	71.0%
<b>Total</b>	<b>100</b>	<b>100%</b>



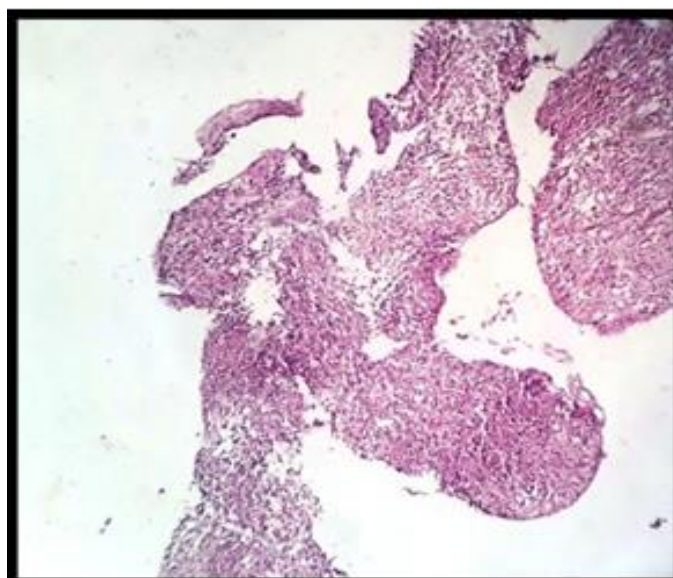
**Figure 1: Distribution of breast lesions on Trucut biopsy.**



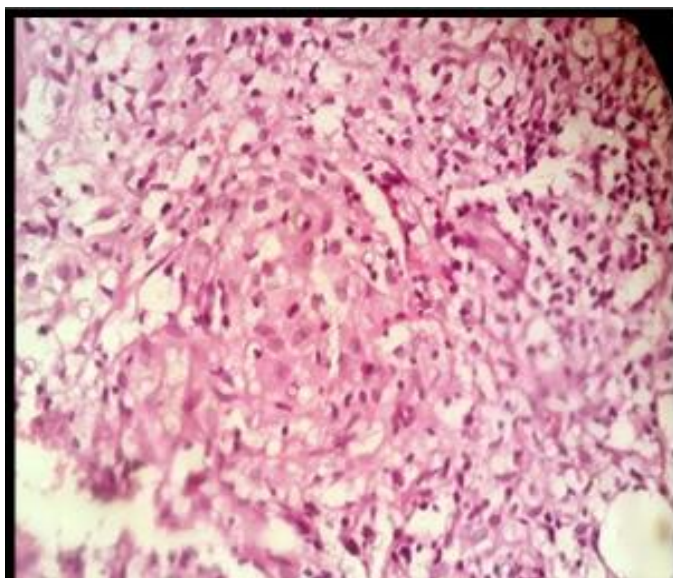
**Figure-3: Histopathological diagnosis of benign breast lesions.**



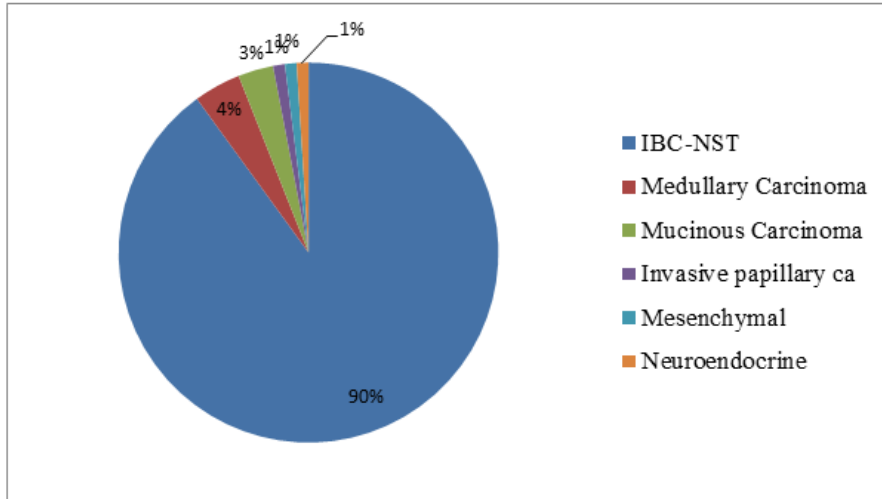
**Figure-3: Photomicrograph of needle core biopsy showing Fibroadenoma (H& E stain,100x).**



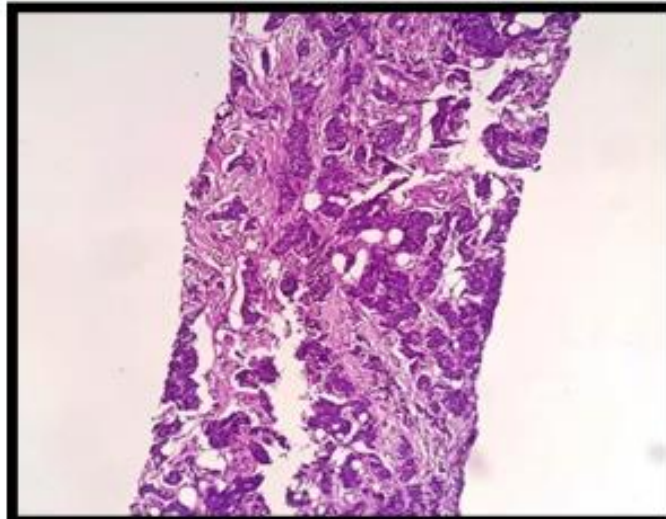
**Figure-4: The needle core biopsy shows features of non-specific Granulomatous Mastitis (H & Estain, 40x&400x).**



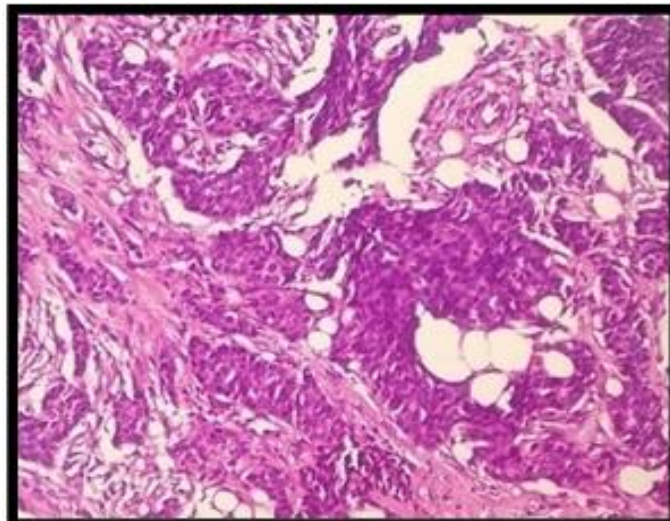
**Figure-5: The needle core biopsy shows features of non-specific Granulomatous Mastitis (H & Estain, 40x&400x).**



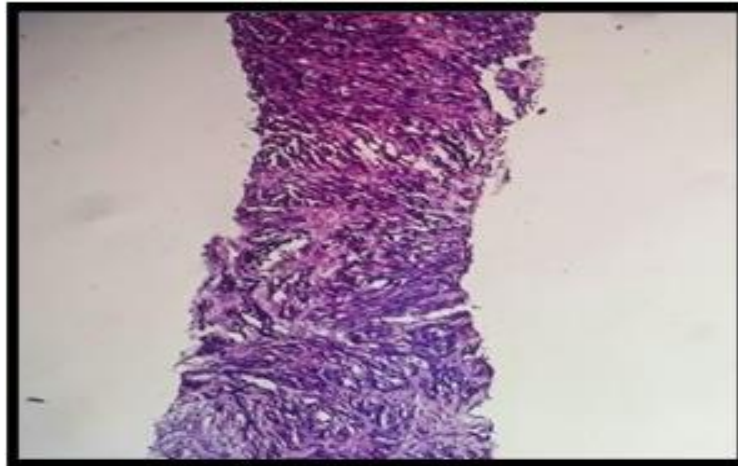
**Figure 6: Histopathological Diagnosis of Malignant Breast Lesions.**



**Figure-7: Needle Core Biopsy showing Invasive Breast Carcinoma NST (H&E stain, 100x&400x).**



**Figure-8: Needle Core Biopsy showing Invasive Breast Carcinoma NST (H&E stain, 100x&400x).**

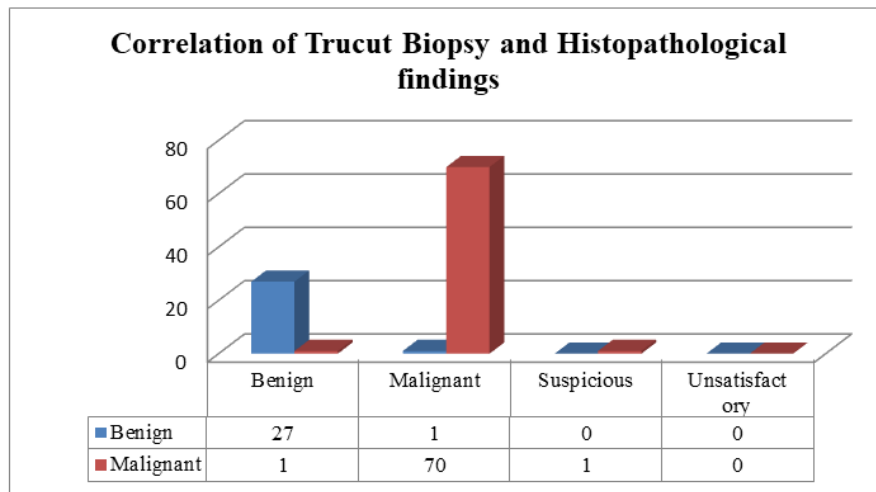


**Figure 9:** The needle core biopsy shows malignant spindle cells (High Grade) (H&E stain, 100 xs).

**Correlation of Trucut Biopsy and Histopathological findings**

In the present study, Trucut Biopsy findings correlated with the histopathological findings in 97 of 100 cases (97%), which included 27 of 28 (96.4%) of the

benign lesions and 71 of 72 (98.6%) of the malignant lesions. 1 case was wrongly diagnosed as malignant while one case each was falsely diagnosed as benign and suspicious on Trucut Biopsy findings. The association was found to be statistically significant ( $p < 0.05$ ).



**Figure-10:** Sensitivity, Specificity, PPV, NPV and Accuracy of Trucut Biopsy.

The Sensitivity, Specificity, Positive Predictive Value (PPV) and Negative Predictive Value (NPV) of Trucut Biopsy were 97.37%, 96.67%, 98.67% and 93.55% respectively. Accuracy of Trucut Biopsy was 97.16%.

**DISCUSSION**

In the present study, majority of the patients (30%) were in the age group of 41-50 years followed by 24% in the age group of 51-60 years, 20% in the age group of 31-40 years, 14% in the age group of 21-30 years and 12% in the age group of >60 years. Singh S *et al.*, [9] did a retrospective study of 98 cases in which 2 patients were males and rest 96 cases were females. Age of the patients ranged from 15-65 years with mean age of 33yrs. In the present study, Trucut Biopsy findings correlated with the histopathological findings in 97 of 100 cases (97%), which included 27 of 28 (96.4%) of the

benign lesions and 71 of 72 (98.6%) of the malignant lesions. 1 case was wrongly diagnosed as malignant while one case each was falsely diagnosed as benign and suspicious on Trucut Biopsy findings. The association was found to be statistically significant ( $p < 0.05$ ). Similar to present study Samantray S *et al.*, [10] also reported 747 cases (83.6%) out of 892 Core biopsies to be diagnosed as malignant Neoplasm. Ajitha MB *et al.*, [11], in a prospective study on fine needle aspiration cytology, trucut biopsy and final histopathological examination in breast lumps found of a total 70 breast lump aspirations, 36 breast lumps were benign and 34 breast lumps were malignant lumps. Of 36 breast lumps with benign lesions, 24(66.6%) were married. Rikabi *et al.*, [12] also reported benign neoplasm to be predominant lesion in their study. Since the place of our study is tertiary care centre where patient presents with disease in advanced stage, which is the reason for

disconcordance with other studies. In the present study, Trucut Biopsy findings correlated with the histopathological findings in 97 of 100 cases (97%), which included 27 of 28 (96.4%) of the benign lesions and 71 of 72 (98.6%) of the malignant lesions. 1 case was wrongly diagnosed as malignant while one case each was falsely diagnosed as benign and suspicious on Trucut Biopsy findings. The association was found to be statistically significant ( $p < 0.05$ ). Rikabi A *et al.*, [8] in a cross-sectional study reported final histopathological diagnosis of the TCB specimens, there were 97 (35.3%) true-positive cases, 173 (62.9%) true-negative cases, 5 (1.8%) false-negative cases and no false positive cases Dimitrov DD *et al.*, [13] in a retrospective clinical study reported Histopathology after tru-cut biopsies showed 74 (93.7%) malignant lesions and 5 benign lesions (6.3%). Histopathology of the post-surgical specimen showed 75 (94.9%) malignant lesions and 4 benign lesions (5.1%). Comparison of TCB to postsurgical histopathology revealed the following results: 74 true positive cases (93.7%), zero false positive cases (0%), one false negative case (1.3%) and 4 true negative cases (5.1%). The one case falsely diagnosed as benign on trucut biopsy came out to be mucinous carcinoma on histopathology Weaver MG *et al.*, [14]. In his study. Mucinous lesion of breast: A pathologic continuum. Reported that the diagnosis of mucinous carcinoma in core needle biopsy is uncomplicated if neoplastic epithelial cells are seen within the mucin. The diagnosis of mucocele like lesion with a frequently minimal epithelial component is more difficult. It is reasonable to view mucocele like lesions as a part of spectrum from benign through to mucinous carcinoma with a significant risk of underdiagnosis from the limited material present on core needle biopsy. Excision of mucocele like lesions is therefore recommended. Rosen PP in his study Mucocele like tumors of the breast also reported that Mucocele like lesions must be considered in the differential diagnosis of mucinous carcinoma [15]. The case falsely diagnosed as malignant on trucut biopsy came out to be Tubular adenosis on histopathology. Patient came for screening mammogram and lump of 1 cm in size was detected in screening mammography. FNAC of lump was inconclusive and Trucut biopsy was reported B5- positive for low grade malignancy, Lee KC *et al.*, [16] in his study.

## CONCLUSION

The results of this study suggest that TCB is an accurate, reliable and a safe method of establishing the diagnosis of cancer in patients with breast lesions. Our results yielded a high sensitivity of 95.65% with 96.88% specificity when compared with FNAC in the diagnosis of breast cancer especially when radiology is not diagnostic. Thus, trucut biopsy should replace fine needle aspiration in the preoperative assessment of suspicious breast lumps.

**Conflict of Interest:** None.

**Source of fund:** Nil.

## REFERENCES

1. Saudi Cancer Registry Report 1999-2005. Saudi Cancer Registry, Saudi Oncology Society.
2. Verenhitch, B. D., Elias, S., Patrocínio, A. C., Nazário, A. C. P., & Waizberg, A. (2011). Evaluation of the clinical efficacy of minimally invasive procedures for breast cancer screening at a teaching hospital. *Journal of clinical pathology*, 64(10), 858-861. 10.1136/jclinpath-2011-200057
3. Mendoza, P., Lacambra, M., Tan, P. H., & Gary, M. T. (2011). Fine needle aspiration cytology of the breast: the nonmalignant categories. *Pathology Research International*, 2011, 547580.
4. Berner, A., & Sauer, T. (2011). Fine-needle aspiration cytology of the breast. *Ultrastructural pathology*, 35(4), 162-167. 10.3109/01913123.2011.576327
5. Florentine, B. D., Cobb, C. J., Frankel, K., Greaves, T., & Martin, S. E. (1997). Core needle biopsy: A useful adjunct to fine-needle aspiration in select patients with palpable breast lesions. *Cancer Cytopathology: Interdisciplinary International Journal of the American Cancer Society*, 81(1), 33-39.
6. Dahlstrom, J. E., Jain, S., Sutton, T., & Sutton, S. (1996). Diagnostic accuracy of stereotactic core biopsy in a mammographic breast cancer screening programme. *Histopathology*, 28(5), 421-427.
7. Pinder, S. E., Elston, C. W., & Ellis, I. O. (1996). The role of pre-operative diagnosis in breast cancer. *Histopathology*, 28(6), 563-566.
8. Mikhail, R. A., Nathan, R. C., Weiss, M., Tummala, R. M., Mullangi, U. R., Lawrence, L., & Mukkamala, A. (1994). Stereotactic core needle biopsy of mammographic breast lesions as a viable alternative to surgical biopsy. *Annals of Surgical Oncology*, 1, 363-367.
9. Singh, S., & Chandra, P. (2015). Diagnostic accuracy of fine needle aspiration cytology of breast lump in rural population of Western U. *P Sch J App Med Sci*, 3, 467-469.
10. Samantaray, S., Panda, N., Besra, K., Pattanayak, L., Samantara, S., & Dash, S. (2017). Utility of tru-cut biopsy of breast lesions-an experience in a regional cancer center of a developing country. *Journal of Clinical and Diagnostic Research: JCDR*, 11(3), EC36.
11. Ajitha, M. B., Babu, V. B., & Singh, A. C. (2017). Comparative study of fine needle aspiration cytology, trucut biopsy and final histopathological examination in breast lumps. *International Journal of Biomedical Research*, 8(3), 154-157.
12. Rikabi, A., & Hussain, S. (2013). Diagnostic usefulness of tru-cut biopsy in the diagnosis of breast lesions. *Oman medical journal*, 28(2), 125-127.
13. Dimitrov, D. D., Karamanliev, M. P., Deliyiski, T. S., Gabarski, A. V., Vatov, P. P., Gencheva, R. O., ... & Petrova, I. U. (2016). Diagnostic value of trucut biopsy in diagnosing breast lesions. *Journal of*

- Biomedical and Clinical Research, 9(2), 126-129.
14. Weaver, M. G., Abdul-Karim, F. W., & Al-Kaisi, N. (1993). Mucinous lesions of the breast: a pathological continuum. *Pathology-Research and Practice*, 189(8), 873-876.
  15. Rosen, P. P. (1986). Mucocoele-like tumors of the breast. *The American journal of surgical pathology*, 10(7), 464-469.
  16. Lee, K. C., Chan, J. K., & Gwi, E. (1996). Tubular adenosis of the breast: a distinctive benign lesion mimicking invasive carcinoma. *The American journal of surgical pathology*, 20(1), 46-54.