

Protective Effect of Aqueous Extract of *Cyperus esculentus* on the Flutamide-Induced Testicular Defect of Male Wistar Rats

Hassan LA*, Anyanwu GE, Nto JN, Abireh IE, Akunna GG

Department of Anatomy, College of Medicine, University of Nigeria Enugu Campus, Enugu, Nigeria

Original Research Article***Corresponding author**

Hassan LA

Article History

Received: 15.04.2018

Accepted: 13.06.2018

Published: 30.06.2018

DOI:

10.36347/sjams.2018.v06i06.015



Abstract: The *Cyperus esculentus* (tiger nuts) have long been used as a liver tonic and heat stimulant. This study evaluated effect of aqueous extract of tiger nuts on serum level of testosterone, LH and FSH in male Wistar rats and histological structures on the flutamide-induced testicular defect of male Wistar rats. Tiger nuts was dried and ground and aqueous extract was prepared using distilled water. Sixteen adult male Wistar rats were randomly divided into four (4) groups (n=4), group A-D. Group A was given distilled water only. Group B was given 5mg/kg of flutamide. Group C was given 150mg/kg of extract of tiger nuts for the period of two weeks before 5mg/kg of flutamide was given for the period of one week. Group D was given 300mg/kg of extract of tiger nuts for the period of two weeks before 5mg/kg of flutamide was given for the period of one week. Rats in group C had a significant increase in level of serum testosterone ($p < 0.05$) when compared with normal control. Also, there was significant increase in levels of LH in group D when compared with normal and positive controls. There was a significant decrease in FSH levels in all treated groups when compared with normal control this may be due to feed mechanism. The histological evidences of testes in group B (positive control) showed a reduction in lining cells of the seminiferous tubules; however, in the other two treatment groups they were similar to the normal control group. The results suggest that extract of tiger nuts elevates the testosterone and LH and protects the adverse effects of flutamide on the testes.

Keywords: *Cyperus esculentus*, flutamide, testis, spermatogenesis.

INTRODUCTION

Many plants have been screened for their medicinal properties [1]. The use of herbs in treatment of different diseases is fast becoming revolutionalized. It is a known fact that most fruits and vegetables are important sources of nourishment and balance diet [2]. Tiger nuts contain high percentage of alkaloids, saponins and tannins are known to have anti-microbial activity, as well as other physiological activities [3]. Tiger nuts was reported as healthy and helps in preventing heart, thrombosis and activates blood circulation and are responsible for preventing and treating urinary tract infections and other bacterial infections [4]. Tiger nuts is a crop of the family (Cyperaceae) native to warm temperate to subtropical regions of the Northern Hemisphere [5]. The tubers are edible, with a slightly sweet, nutty flavour, compared to the more bitter-tasting tuber of the related *Cyperus rotundus*. Abano *et al.*, [6] reported that tiger nut oil can be used in the cosmetic industry. As it is antioxidant (because of its high content in vitamin E) it helps slow down the ageing of the body cells. It also favours the elasticity of the skin and reduces skin wrinkles [7].

Flutamide is a non-steroidal anti-androgen which competitively inhibits the binding of androgens to the androgen receptor [8]. Perobelli *et al.*, [9] reports that the exposure to flutamide during the prepubertal period compromises the function of the epididymis along with epididymal sperm quality at adulthood.

Therefore, this study is designed to confirm the protective effect of tiger nuts extract against adverse effects of flutamide on the histology of the testes.

MATERIALS AND METHODS**Extraction of tiger nuts:**

The nuts were cleaned from soils, dust, washed and sun dried. The nuts were grounded with grinding machine and stone into powder form. The grounded nut was dissolved in specific quantity of water, stirred and left for 48 hours and boiled for about 20 minutes. The extract was obtained through the filtration. The phytochemical was report by [10] to have alkaloid, glycoside, resin, flavonoid, tannins, sterols, saponins, cyanogenic glycoside.

Experimental Animals

Sixteen adult male Wistar rats weighed of 120g to 180g were obtained from the animal house of Faculty of medical Sciences, University of Nigeria Enugu Campus. Animals were housed in different cages placing in the room for period of two weeks for acclimatization in the department of Anatomy.

Experimental designs

Sixteen adult male Wistar rats were divided into four groups (4 in each group), the period of treatment in all groups were 1-14 and 14-21 days. The group A (normal control) was fed daily with normal feed and distilled water for twenty one days. Group B (negative) was treated with a daily 5mg/ kg body weight of flutamide orally for seven days. Group C was given 150mg/kg of extract of tiger nuts daily for fourteen days before they were dosed with flutamide for seven days. Group D was given 300 mg/kg of extract of tiger nuts daily for fourteen days before they were dosed with flutamide for seven days.

Determination of hormone assay

After 24 hours following the administration of the last dose, before the animals sacrificed whole blood

collected by capillary tube through medial optical plexus and kept in non-heparinised vacutainer which was span at 2500rpm for 10min using a bio-centrifuge (MSE, O-5122A, Germany). The level of free serum testosterone, LH and FSH in serum was measured with ECOBAS-6000 hormone analyzing machine as described by Atlas *et al.*, [16].

HISTOLOGICAL STUDY

Animals in all groups were sacrificed under the anesthetic agent called thiopental at dose 50mg/kg. The abdominal cavities were opened up through the midline incision to exposed the reproductive organs (testes). These samples were taken for histological study and these were kept in MDF fluid (modified Davidson’s fluid) until the time of sections [11]. The sections were worked in the department of Anatomy College of Medicine, University of Nigeria Enugu Campus.

Statistical analysis

The data obtained were analyzed with one way ANOVA at 5% level of significance.

RESULTS

Table-1: Showing the body weight differences of experimental models at day 1 and day 22 of the study

Groups	Day 1 (g)	Day 22 (g)
Normal control (A)	150.0±0.3	168.7±0.5 (12.5%)
Positive control (B)	116.3±0.1	167.5 ± 0.2(44.1%)
Protective I (C)	130.0±0.6	165.0±0.1 (26.9%)
Protective II (D)	177.5±0.3	197.5±0.1 (11.3%)

Values are expressed as mean ± SD for n=4 in percentage.

It was noted here that the percentage increase in body weight in group B is 44.1% which is significant when compared with group A (12.5%).

Percentage increase in body weight in all experimental groups is also significant when compared with normal control (group A).

Table-2: Showing the results for testosterone, follicle stimulating hormone and Luteinizing hormone in experimental models.

	A	B	C	D
Testosterone	0.31±0.01	2.61±0.02	2.01±0.02	0.40±0.00
Follicle stimulating hormone	11.51±0.02	4.30±0.16	4.29±0.03	4.30±0.00
Luteinizing hormone	6.60±0.2	4.31±0.01	4.40±0.25	8.30±0.02

OBSERVATION ON HORMONAL ASSAY

The rats in group and E had significant increase in level of serum testosterone with p<0.05 when compared with normal control. There was also significant increase in level of luteinizing hormone in

group D with p<0.001 when compared with both normal and positive controls. FSH was significantly reduced with p<0.01 in all experimental groups when compared with normal control.

HISTOPATHOLOGICAL FINDINGS

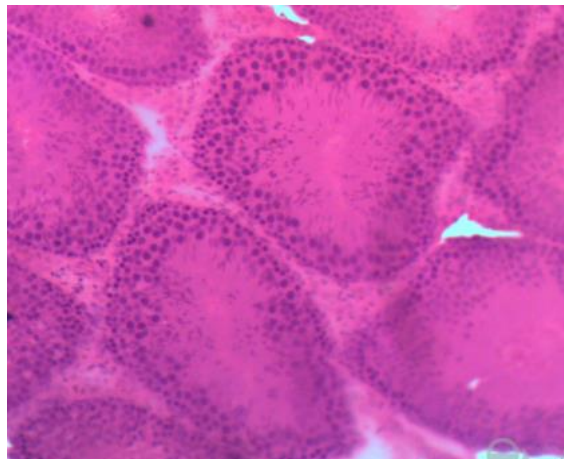


Fig-1: Histoculture of the testis (H&E, x200) in group A (normal control) showing apparently normal outline of the seminiferous tubules, interstitium and spermatogenic cells (arrows) at different stages of development, and lumen.

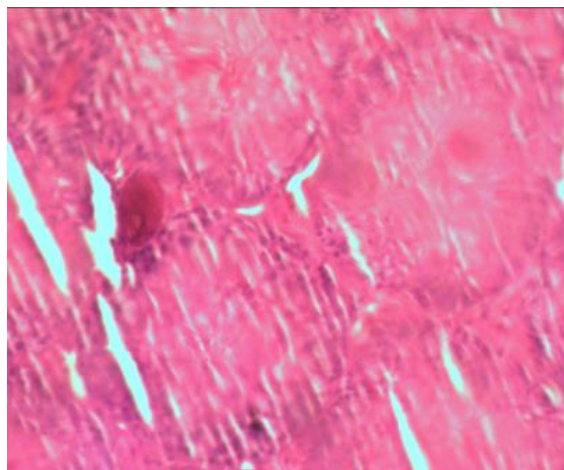


Fig-2: Histoculture of testis (H&E stain, x200) in negative control (B) treated with 5mg/kg body weight of flutamide only showing microstructure and loss of spermatogenic cells, reduced density of mature spermatozoa within the lumens of the seminiferous tubules and some degree of disintegration and degeneration of cells.

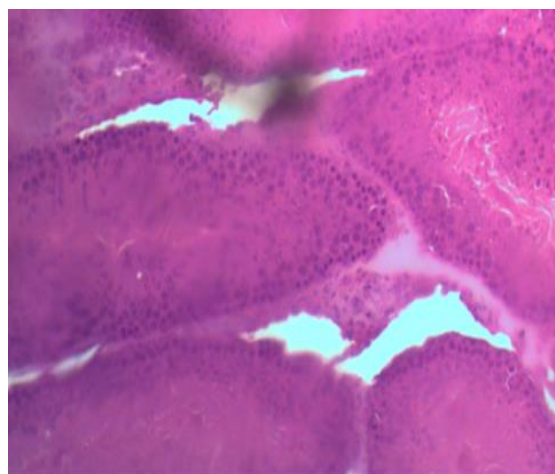


Fig-3: Histoculture of testis (H&E stain, x200) in group C treated with 150mg/kg of extract of tiger nuts for two weeks + 5mg/kg of flutamide for one (1) week, there is hypertrophy of leygid cells, it showed increased number of spermatozoa in seminiferous tubules as compared to positive control.

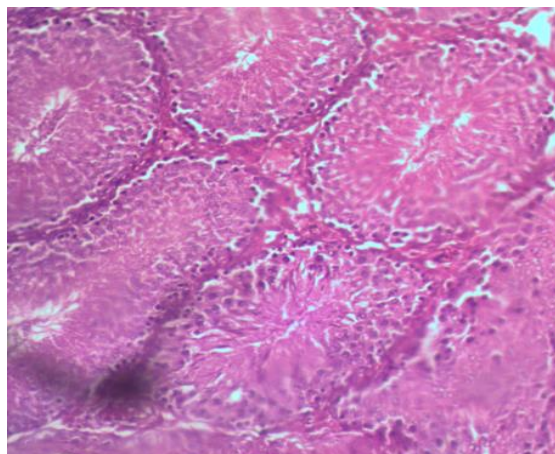


Fig.-4: Histoculture of testis (H&E stain,x200) in group D treated with 300mg/kg of extract of *Cyperus esculentus* for two (2) weeks + 5mg/kg of flutamide for one (1) week, there is hypertrophy of leydig cells, showed increased number of spermatozoa in seminiferous tubules as compared groups C and D (curative group)

DISCUSSION

This present study investigated the protective properties of aqueous extract of tiger nuts on the testis against the testicular defect that may be induced by flutamide. Generally, elevated testosterone level enhances the sexual behavior in humans. Sexual desire may be enhanced directly by increasing serum testosterone level or by having testosterone like effect [12]. Luteinizing hormone (LH) and Follicle Stimulating Hormone (FSH) produced by anterior pituitary lobe are necessary for maintaining testosterone levels such that as LH and FSH increases so do the testosterone. This study showed that *tiger nuts* had a significant increase ($p < 0.01$) in LH serum level and this agrees with the higher testosterone level observed for this plant extract in treatment groups when compared with controls *with dose-dependent*. The dose-dependent increase in body weight at high extract dose of extract shows their anabolic effects. This is attributable to the anabolic effects of raised testosterone levels which causes increase in metabolism, tissue generation and muscle building which results to general increase in body mass index. The results of anabolic effects correspond with those of the raised serum testosterone levels in the high doses of extract-treated groups. This agrees with elevated LH and testosterone levels in extract treated groups. Interestingly there was statistically significant reduction in level of FSH in all experimental groups irrespective of the use of anti-androgen drug (flutamide). This may be due to feed back mechanism. In the histoculture of testes of rats treated with extract, all stages of spermatogenesis were more pronounced but with dose-dependent when compared with normal and negative controls (A and B respectively). In the extract-treated groups the spermatogonia are in their first stage of repetitive and multiplicative cell division and the lumen size was decreased. There is hypertrophy of leydig cells and spermatid differentiation in extract-treated groups as compared to both normal and negative controls which further

support their androgenic activity. We have demonstrated that aqueous extract of *tiger nuts* has an androgenic activity in flutamide treated male rats. This agrees with reports from Kamatenesi and Oryem [13], Malviya N *et al.*, [14], and Ayyanar and Ignacimuthu [15] that leaves were the most preferred part to treat ED, constituting 57.6% of herbal remedies in western Uganda. This exceptionally high usage relate to their availability throughout the year.

CONCLUSION

From these results it will be concluded that extract of tiger nuts increases the body weight, it may also has positive libido effect because it increased testosterone. This also showed that extract of tiger nuts has protective effects on the spermatogenic cells of testes of experimental animals against adverse effects of flutamide. Therefore this study will validate the use of the tiger nuts extract as a protective agent of reproductive organs against adverse effects on the testis by any agent. However, isolation and identification of active constituents from Tiger nuts will important from further research in other to bring a dynamic change in the modern world.

REFERENCES

1. Tamunotonye W, Jacks SA, Asala JP. Testicular enhancement activity of Aqueous extract of *Pausinystalis macroceras* stem bark in Wistar rats. *J Anat Sci.* 2007;1(1):3-6.
2. Ibrahim TA, Jude BS, Giwa EO, and Adebote VT. *Rea search Journal of Agric and Biological Sciences*, 2009, 5(6): 1143-1145.
3. Sofowora EA. *Medicinal plants and Traditional Medicine in Africa*. Ibadan-Owerri-Kaduna-Lagos Spectrum Books Limited, 1993: 159-238.
4. Adejuyitan JA, Otunola ET, Akande EA, Bolarinwa IF and Oladokun FM. Some Physicochemical properties of Flour obtained from fermentation of tiger nut (*Cyperus esculentus*)

- sourced from a market in Ogbomoso, Nigeria. *Afric. J. of Food Science*, 2009; 3: 51-55.
5. Miller, D. A. (2010). Are optical transistors the logical next step?. *Nature Photonics*, 4(1), 3.
 6. Abano EE, Amoah KK. Effect of moisture content on the physical properties of tiger nut (*Cyperus esculentus*). *Asian Journal of Agricultural Research*. 2011;5(1):56-66.
 7. Tiger nut traders SL, tiger nut oil, 2012, <http://www.tigernut.com>.
 8. Dorfman RI. Biological activity of anti-androgens. *British Journal of Dermatology*. 1970;82(6):3-8.
 9. Perobelli JE, Alves TR, de Toledo FC, Fernandez CD, Anselmo-Franci JA, Klinefelter GR, Kempinas WD. Impairment on sperm quality and fertility of adult rats after antiandrogen exposure during prepuberty. *Reproductive toxicology*. 2012 Jun 1;33(3):308-15.
 10. Ekeanyanwu RC, Njoku O, & Ononogbu IC. The Phytochemical Composition and Some Biochemical Effect of *Cyperus esculentus*. *Pakistan Journal of Nutrition*. 2010: 9(7): 709-715.
 11. Latendresse JR, Warbritton AR, Jonassen H, Creasy DM. Fixation of testes and eyes using a modified Davidson's fluid: comparison with Bouin's fluid and conventional Davidson's fluid. *Toxicologic pathology*. 2002 Jun;30(4):524-33.
 12. Davis SR, Tran J. Testosterone influences libido and well being in women. *Trends in Endocrinology & Metabolism*. 2001 Jan 1;12(1):33-7.
 13. Kamatenesi-Mugisha M, Oryem-Origa H. Traditional herbal remedies used in the management of sexual impotence and erectile dysfunction in western Uganda. *African Health Sciences*. 2005;5(1):40-9.
 14. Malviya NE, Jain SA, Gupta VB, Vyas S. Recent studies on aphrodisiac herbs for the management of male sexual dysfunction--a review. *Acta Pol Pharm*. 2011 Jan 1;68(1):3-8.
 15. Ayyanar M, Ignacimuthu S. Herbal medicines for wound healing among tribal people in Southern India: Ethnobotanical and Scientific evidences. *International Journal of Applied Research in Natural Products*. 2009 Sep 15;2(3):29-42.
 16. Ronald MA, Alfred EB, Lawrence CP. Laboratory manual experimental microbiology. JM Smith, St. Louis: Mosby pub, USA. 1995:68-9.