

White-Centred Retinal Hemorrhage Revealing Medullar Aplasia

Karmoun S*, Elmarzouqi B, Hajji Z, Aboulanouar A, Berraho A

Service d'ophtalmologie B, Hôpital des Spécialités de Rabat, Morocco

DOI: [10.36347/sjams.2020.v08i04.024](https://doi.org/10.36347/sjams.2020.v08i04.024)

| Received: 15.04.2020 | Accepted: 24.04.2020 | Published: 30.04.2020

*Corresponding author: Karmoun Souhaila

Abstract

Case Report

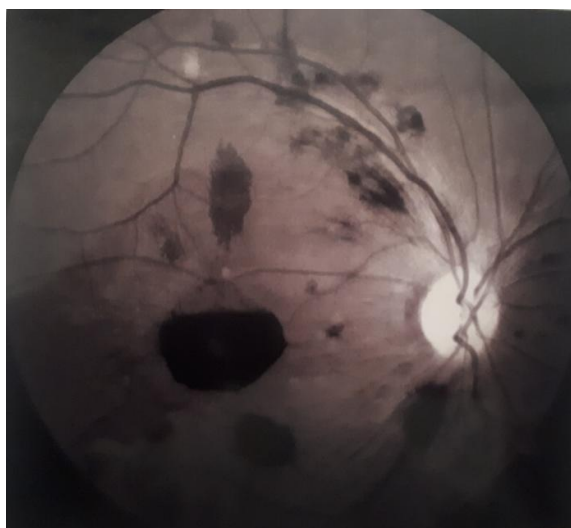
Previously considered pathognomonic for subacute bacterial endocarditis, white center retinal hemorrhages or Roth spots are currently recognized in connection with several pathologies. We report a case of a patient with white center hemorrhages due to medullar aplasia. Roth spots constitute a retinal morphological manifestation that can occur during several pathological conditions, some of which can be life-threatening. Hence the interest of a serious etiological investigation in the presence of these tasks in the fundus examination. The role of the ophthalmologist is important at the time of diagnosis and during post-treatment surveillance.

Keywords: White-Centred pathognomonic surveillance Medullar Aplasia Hemorrhage.

Copyright @ 2020: This is an open-access article distributed under the terms of the Creative Commons Attribution license which permits unrestricted use, distribution, and reproduction in any medium for non-commercial use (NonCommercial, or CC-BY-NC) provided the original author and source are credited.

INTRODUCTION

Retinal angiography of the right eye showing retinal hemorrhages + Roth spots



Previously considered pathognomonic for subacute bacterial endocarditis, white center retinal hemorrhages or Roth spots are currently recognized in connection with several pathologies.

We report a case of a patient with white center hemorrhages due to medullar aplasia. We insist on the fact that retinal hemorrhages with white center can be inaugural of pathologies which can involve the vital

prognosis. Hence the importance of a serious etiological investigation in the face of this type of hemorrhage.

OBSERVATION

A 33-year-old man, with no particular medical history, who presented to the ophthalmic emergency department for a sudden drop in visual acuity in both eyes, evolving for 5 days. The examination revealed at the right eye a visual acuity: 2 / 10 P8 and at the left eye a visual acuity: 7/10 P4. The examination of both eyes shows a calm anterior segment and FO: diffuse superficial and deep hemorrhages with some Roth spots. Fluorescein angiography did not show delayed filling or retinal ischemia; she confirmed the retinal hemorrhages (fig 1 and fig 2).

On the biological assessment, we noted a pancytopenia: hemoglobin 6g / dL, a leukocyte level 1440 / mm³ and platelets at 1400 / mm³. The patient underwent a bone marrow biopsy concluding with medullar aplasia. The rest of the etiological assessment was carried out in the internal medicine department, concluding in the diagnosis of multiple myeloma. The patient has been scheduled for medullar transplantation.

The evolution at 3 months on the right eye was marked by the appearance of a macular scar probably fibrohemetic pre-foveal responsible for the persistence of visual acuity at 4 / 10 P8 (fig 3), while on the left eye the visual acuity was at 10/10 P2 (fig 4 and fig 5).

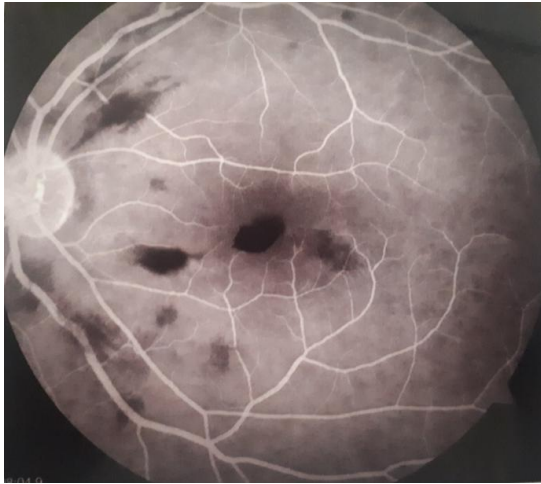


Fig-1: retinal angiography of the left eye showing retinal hemorrhages + Roth spots

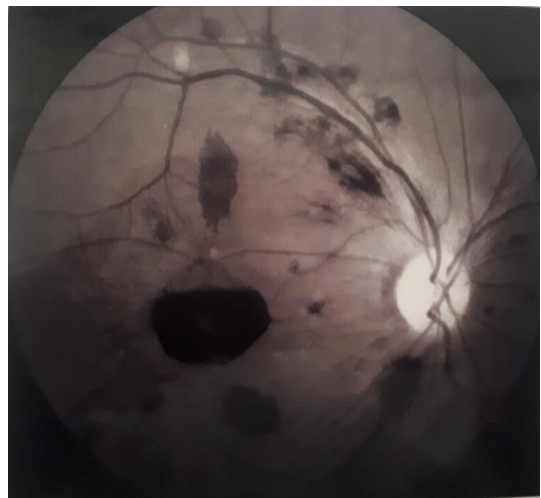


Fig-2: Retinal angiography of the right eye showing retinal hemorrhages + Roth spots

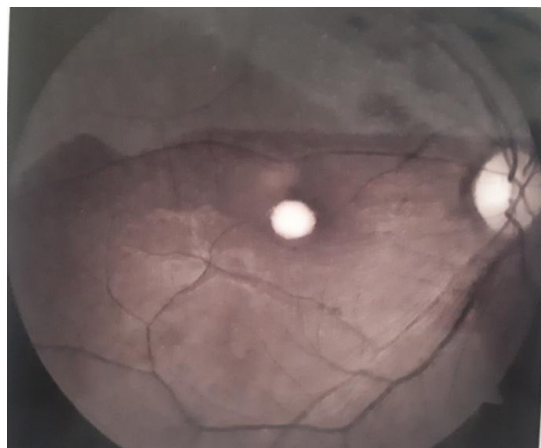

Fig-3: Image showing a macular lesion in the left eye strongly evoking scar fibrosis

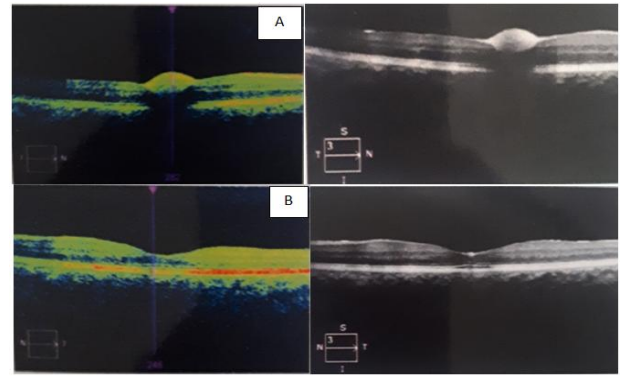


Fig-4 and Fig 5: Macular OCT of the right eye (A) showing an alteration of the internal retinal layers explaining the persistence of the decrease in visual acuity in connection with scar fibrosis
Left eye macular OCT (B) showing OCT with no detectable abnormality

DISCUSSION

Recent histological studies have shown the presence of a white thrombus formed of aggregates of leukocytes, platelets and fibrin in the white center of the hemorrhage, which is part of the process of repairing a capillary rupture, and not a bacterial abscess as it was presumed [1].

Despite the fact that retinal hemorrhage in spinal cord aplasia is relatively common, patients usually come to the hospital for reasons other than blurred vision [2]. In the literature, we have found six cases reporting blurred vision as their first complaint. The age of the patients in these cases varies between 4 and 60 years.

White center retinal hemorrhages can appear and disappear very quickly (less than half an hour) [1]. The visual prognosis depends on the location of these hemorrhages (macular or not), the associated lesions and the etiology involved. In the absence of associated lesions, the resorption of macular hemorrhages would be accompanied by visual improvement.

CONCLUSION

Roth spots constitute a retinal morphological manifestation that can occur during several pathological conditions, some of which can be life-threatening. Hence the interest of a serious etiological investigation in the presence of these tasks in the examination of the FO. The role of the ophthalmologist is important at the time of diagnosis and during post-treatment surveillance.

REFERENCES

1. Ling R, James B. White-centred retinal haemorrhages (Roth spots). *Postgraduate medical journal*. 1998 Oct 1;74(876):581-2.
2. Issaragrisil S, Kaufman DW, Anderson T, Chansung K, Leaverton PE, Shapiro S, Young NS. The epidemiology of aplastic anemia in Thailand. *Blood*. 2006 Feb 15;107(4):1299-307.