

Role of Platelet Rich Plasma via Lumbar Epidural Route in Chronic Prolapsed Intervertebral Disc

Dr. Mustafa Johar¹, Dr. Anshul Patel^{2*}, Dr. Setul Shah³, Dr. Himanshu Suman⁴, Dr. Rajeev Parmar⁵, Dr. Murtaza Rassiwal⁶

¹Prof. Dept. of Orthopaedics, Index Medical College Hospital & Research Centre, Indore

²Junior Resident, Dept. of Orthopaedics, Index Medical College Hospital & Research Centre, Indore, Madhya Pradesh, India

³Junior Resident, Dept. of Orthopaedics, Index Medical College Hospital & Research Centre, Indore, Madhya Pradesh, India

⁴Junior Resident, Dept. of Orthopaedics, Index Medical College Hospital & Research Centre, Indore, Madhya Pradesh, India

⁵Junior Resident, Dept. of Orthopaedics, Index Medical College Hospital & Research Centre, Indore, Madhya Pradesh, India

⁶Resident, Sahaj Hospital, Indore, Madhya Pradesh, India

Original Research Article

***Corresponding author**

Dr. Anshul Patel

Article History

Received: 15.07.2018

Accepted: 26.07.2018

Published: 30.07.2018

DOI:

10.36347/sjams.2018.v06i07.055



Abstract: To determine whether injections of autologous platelet-rich plasma (PRP) into MRI proved Chronic Prolapsed Intervertebral Disc will improve participant-reported pain and function. Adults with chronic (≥ 6 months), lumbar Prolapsed Intervertebral Disc, Radiculopathy for more than 4 weeks duration with a positive symptomatology and MRI proved PIVD that was unresponsive to drug and physical therapy.

Keywords: Platelet, Plasma, Lumbar Epidural route, Intervertebral Disc.

INTRODUCTION

Low back pain has become a major Orthopaedic OPD burden for people under 45 years. It has become one of the main causes for limitation of all activities and is increasing in huge proportions. Risk factors for developing spine pain may be physical, socio- economical, poor medical health, psychological state, occupational and environmental. These all factors partially or totally contribute to the the back pain[1].

Origin of low back pain may be from different sources as spinal ligaments, spinal nerve roots, the vertebral periosteum, facet joints, the paravertebral musculature and annulus fibrosus etc.

Age related degenerative processes in the vertebral discs and facet joints are most common process. In patients with Prolapsed Intervertebral Disc (PIVD), there is acute disc herniation which leads to mechanical compression of the nerve within the intervertebral foramina and an inflammatory phenomenon which causes swelling and after neuronal activity.

Anatomically, the intervertebral disc (IVD) consists of the central highly hydrated nucleus pulposus (NP), the peripheral lamellae annulus fibrosus (AF), and the superior and inferior cartilage endplates (CEPs). Physiologically, the swelling pressure within the NP region caused by the negatively charged proteoglycans facilitates spinal load absorption. During IDD, the disc undergoes complex biochemical and cellular changes including loss of proteoglycan content, the transition of type II collagen to type I collagen, and decreases in NP cell density. These degenerative changes directly lead to

attenuated mechanical function of the IVD and ultimately induce structural disruptions, such as AF tears and NP protrusion[2].

The treatment ranges from conservative to surgical. Different methods of conservative management include rest, analgesics, traction, spinal manipulation and psychological treatment. Others may require surgery for LBA and even after that there may not be complete relief (failed back syndrome).

There has been use of epidural injections since long time with steroids for the purpose of pain relief. Risk factors for se procedure include infection, paralysis and spinal headache, haemorrhage or haematoma. Septic and aseptic meningitis as well as spinal cord embolisms have been seen due to steroid use. Apart from reducing the hypoglycaemic effect of insulin and interfering with blood glucose control in diabetic patients, severe cases of cushing syndrome, adrenal suppression and myopathy have been reported with steroid use. Till present only steroids alone or in combination with opioids and local anaesthetics has been an option to allow with the pain by decreasing inflammation via epidural route. That too, pain relief not lasting for 1 week or upto 1 year only.

Autologous Platelet Rich Plasma is a novel therapeutic tool that has evolved in recent years due to successful therapeutic efficiency. Famous professional football players, Tiger Woods and Rafael Nadal attribute, in part, their “miraculous” recoveries to the employment of this enigmatic treatment dubbed as the “PRP phenomenon.” Use of autologous PRP treatment is quite frequent in rheumatology, orthopaedics and sports medicine field. Despite the controversy the treatment is effective and there is lack of any known side effects till now. Mostly autologous PRP has been used for chronic tendinopathy and enthesopathy, including knee osteoarthritis. It has become a very important tool for use of pain management consultant because of low cost, ease of use and its apparent safety. In spine PRP has been applied to intervertebral discs, facet joints, ligaments and for radiculopathies [3,4].

MATERIALS AND METHODS

Primary Hypothesis

Infiltration of autologous PRP into Dural sleeve of nerve root (at target) will improve participant-reported pain and function especially radicolopathy.

Methodology

The study was carried out in the Department of Orthopaedic, Index medical college hospital and

research centre over a period of 3 year between August 2015 and July 2017 with due approval of ethics committee. This study included patients with findings of Prolapsed Intervertebral Disc revealed on MRI, having complaints of backache for more than 6 months duration radiculopathy for more than 4 weeks duration with a positive Straight Leg Raising Test (SLRT) and not responding to the conventional treatment.

After fulfilling the criteria, patients were explained in detail about the treatment modality & a written informed consent was taken. Diagnostic work up included complete haemogram with ESR, coagulation profile, blood sugar, X-Ray Spine (AP and lateral view). Baseline Visual Analogue Scale (VAS) score, Modified Oswestry Disability Questionnaire (MODQ), SLRT and neurological examination of lower limb prior to the procedure was recorded. PRP was prepared by fully equipped machine in blood bank of IMCHRC under guidance of senior blood transfusion consultant under aseptic condition from patient own blood. About 100ml of patients own blood was taken which was centrifuged and 5ml of platelet rich plasma was prepared in blood bank.

Under strict aseptic precautions a single injection of five ml autologous PRP was infiltration in dural sleeve of nerve root with 18G tuohys needle using fluoroscopic guidance. After the procedure haemodynamic parameters were monitored and recorded every 5 minutes for 60 minutes and also for any possible complications.

Patients were evaluated after 1 hour of procedure and discharged with advice to avoid too much bending, lifting heavy weight or walking long distances and told to follow-up at 3 week and 3 month. VAS score, MODQ and SLRT were noted at all follow up visits. Neurological examination of lower limb was also done which included motor examination in form tone, power, reflexes and sensory examination.

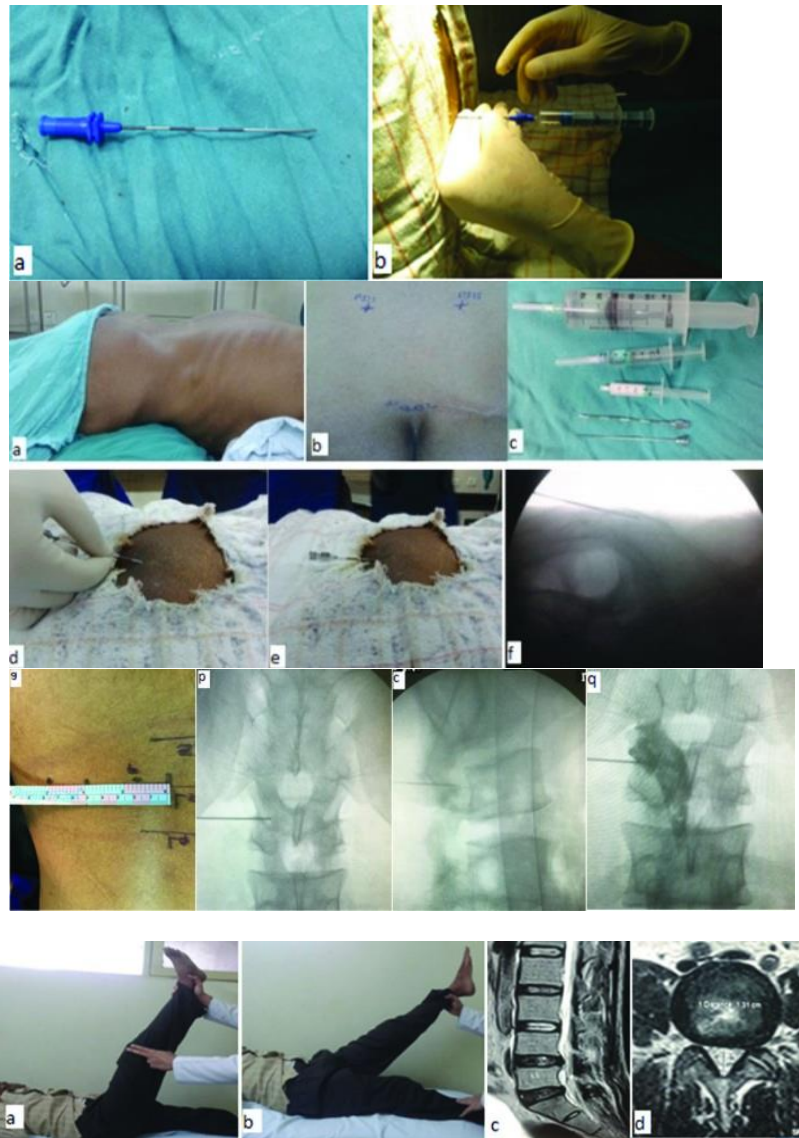


Fig-01: Patient Evaluation & Neurological examination of lower limb

Inclusive Criteria

- Refractory low back pain persisting for ≥ 6 mo
- Failure of conservative treatment measures (oral medications, rehabilitation therapy,* and/or injection therapy)
- Disk protrusion less than 5 mm on magnetic resonance imaging or computed tomography scan
- Absent contraindications (eg, spinal stenosis)

Exclusive criteria

- Presence of a known bleeding disorder
- Current anticoagulation therapy
- Pregnancy
- Systemic infection or skin infection over the puncture site
- Allergy to contrast agent
- Presence of a psychiatric condition (eg, posttraumatic stress disorder, schizophrenia)
- Solid bone fusion preventing access to the disk

- Severe spinal canal compromise at the levels to be investigated
- Extrusions or sequestered disk fragments
- Spondylolisthesis

RESULTS

It was seen that 200 patients who underwent autologous PRP injection via lumbar epidural showed a gradual improvement of symptoms as in terms of VAS scores, MODQ index and SLRT.

This improvement of symptoms was sustained through a period of 3 months till the patients were followed up. Apart from 20 patients VAS score was 5, rest of them showed improvement and their VAS SCORE was 4 or less than 4 at three months. For most of the patients MODQ score was less than 30% and SLRT improved to >70 at three months. It showed that the gradual improvement seen was sustained till the follow-up period of 3 months. There were no

complications seen & patients were able to do their daily activities without pain medications.

Table-1: VAS Score of 200 patients

S. No.	Patient	VAS Score
1.	180	04 or less than 04
2.	20	05 or more
Total	200	

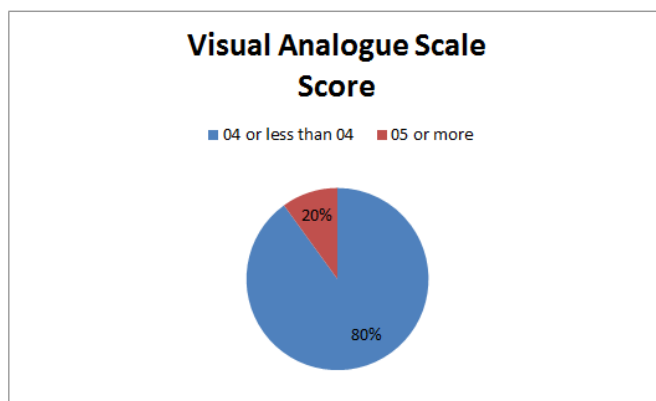


Fig-2: VAS Score

LIMITATION

The limitations of ongoing study include the gradual improvement of pain symptoms. Patients in acute pain may not get immediate effect and may need to be supplemented with pain killers for a few days post PRP injection. Second limitation is more of subjective in nature as many patients are hesitant in nature to sampling blood. Patients need to be counselled properly pre- procedurally about benefits.

DISCUSSION

Initially, prolapsed disc was believed to cause back and leg pain by mechanically compressing the nerve roots. Now, it's well known that leakage of the contents of the nucleus pulposus causes pain producing an inflammatory reaction in the disc itself, around the facet joint and a chemical neuroradiculitis due to the synthesis of various inflammatory mediators [5].

A degenerated disc undergoes serial pathological changes in its metabolism, biomechanics, geometric appearance, and cellular phenotype. These changes are characterized as reduced cell density, increased cell senescence and apoptosis, unbalanced matrix metabolism, upregulated inflammatory cytokines, and decreased disc height and NP hydration

PRP application would promote IDD regeneration is based on the role of platelets in wound healing. When activated, platelets can secrete a variety of growth factors, including PDGF, IGF-1, TGF-β, VEGF, bFGF, EGF, and CTGF, among others. All these growth factors might play significant roles in promoting the proliferation of tissues. Platelets also

contain antibacterial and bactericidal proteins that may influence the process of inflammatory responses by inducing the synthesis of some molecules, such as integrins, interleukins and chemokines. Last but not least, platelets may serve as a biological sponge because they can absorb, store and transfer some small molecules that regulate tissue regeneration. PRP represents a new biotechnology in tissue engineering and has become a popular clinical treatment for various tissue healing applications without any immune rejections [6].

In our technique we have used trans foraminal approach for injecting PRP in epidural space which involves passage of a needle through ligamentum flavum. Interlaminar epidural injections have been studied extensively regarding their role in radicular pain due to disk herniation, pain due to spinal stenosis, axial back pain in the absence of disk herniation and failed back surgery syndrome. Advantages include the increased likelihood that injected PRP will reach adjacent spinal levels, the ability to treat bilateral pain and the need for a lower volume of PRP. There appears to be a good evidence for the treatment of radicular pain due to disk herniation and somewhat weaker evidence for treatment of spinal stenosis, discogenic pain and postsurgical pain with this technique [7].

CONCLUSION

This study suggests a definitive role for PRP via lumbar epidural injection in reducing symptomatology for chronic prolapsed intervertebral disc patients.

REFERENCES

1. Abbasipour-Dalivand S, Mohammadi R, Mohammadi V. Effects of local Administration of Platelet Rich Plasma on functional recovery after bridging sciatic nerve defect using silicone rubber chamber; an experimental study. *Bulletin of Emergency and Trauma*. 2015;3(1):1–7.
2. BhAtiA R, ChopRA G. Efficacy of Platelet Rich Plasma via Lumbar Epidural Route in Chronic Prolapsed Intervertebral Disc Patients-A Pilot Study. *Journal of clinical and diagnostic research: JCDR*. 2016 Sep;10(9):UC05.
3. Elgazzar RF, Mutabagani MA, Abdelaal SE, Sadakah AA. Platelet rich plasma may enhance peripheral nerve regeneration after cyanoacrylate reanastomosis: a controlled blind study on rats. *Int J Oral Maxillofac Surg*. 2008;37(8):748–755.
4. Strunk D. Human platelet lysate can replace fetal bovine serum for clinical-scale expansion of functional mesenchymal stromal cells. *Transfusion*. 2007;47(8):1436–1446.
5. Liang G, Cline GW, Macica CM. IGF-1 stimulates de novo fatty acid biosynthesis by Schwann cells during myelination. *Glia*. 2007;55(6):632–641.
6. Tuakli-Wosornu YA, Terry A, Boachie-Adjei K, Harrison JR, Gribbin CK, LaSalle EE, Nguyen JT, Solomon JL, Lutz GE. Lumbar Intradiskal platelet-rich plasma (PRP) injections: a prospective, double-blind, randomized controlled study. *Pm r*. 2016;8(1):1–10.
7. Manchikanti L, Pampati V, Benyamin RM, Boswell MV. Analysis of efficacy differences between caudal and lumbar interlinear epidural injections in chronic lumbar axial discogenic pain: local anesthetic alone vs. local combined with. *Steroids*. 2015;12(3):214.