

A Very Incongruous Ecchymotic Macules and Nodules Revealing a Blastic Plasmacytoid Dendritic Cell Neoplasm

H. Chehab^{1*}, F. Hali², F. Mernissi³, D. Tolba⁴, S. Chiheb⁵

^{1,2,5}Department of Dermatology, IBN Rochd University Hospital, Casablanca, Morocco

^{3,4}Anatomopathology Department, IBN Rochd University Hospital, Casablanca, Morocco

DOI: [10.36347/sjams.2020.v08i04.010](https://doi.org/10.36347/sjams.2020.v08i04.010)

| Received: 30.03.2020 | Accepted: 06.04.2020 | Published: 14.04.2020

*Corresponding author: Hafssa Chehab

Abstract

Case Report

Blastic plasmacytoid dendritic cell neoplasm previously known as CD4+/CD56+ blastic NK cell tumors or hematodermic tumors. We report a case of a 76-year-old woman presented with disseminated violaceous nodular, 'bruise like' patches and macules of the trunk and subconjunctival hemorrhage. Immunohistochemistry showed a CD4+/CD56+ expression which confirmed the diagnosis of BPDCN was made. We emphasize that careful analyses should be performed to make the correct diagnosis.

Keywords: hematodermic tumors, Immunohistochemistry, CD4+/CD56+, BPDCN.

Copyright © 2020: This is an open-access article distributed under the terms of the Creative Commons Attribution license which permits unrestricted use, distribution, and reproduction in any medium for non-commercial use (NonCommercial, or CC-BY-NC) provided the original author and source are credited.

INTRODUCTION

Blastic plasmacytoid dendritic cell neoplasm previously known as CD4+/CD56+ blastic NK cell tumors or hematodermic tumors. They were reclassified as a neoplastic entity in the 2008 World Health Organization classification [1].

This leukemia is regarded as an orphan tumor due to its rareness and usual clinical aggressiveness with poor response to conventional chemotherapies [2].

It derives from precursors of plasmacytoid dendritic cells (pDCs), also known as professional type

I interferon-producing cells or plasmacytoid monocytes. In the Revised WHO Classification of Tumors of Hematopoietic and Lymphoid Tissues, BPDCN is quoted after acute myeloid leukemia [3].

CASE REPORT

76-year-old woman presented with disseminated violaceous nodular, 'bruise like' patches and macules with variable size involving the trunk, the left shoulder and subconjunctival hemorrhage. Pain and itching were absent (Figure-1).

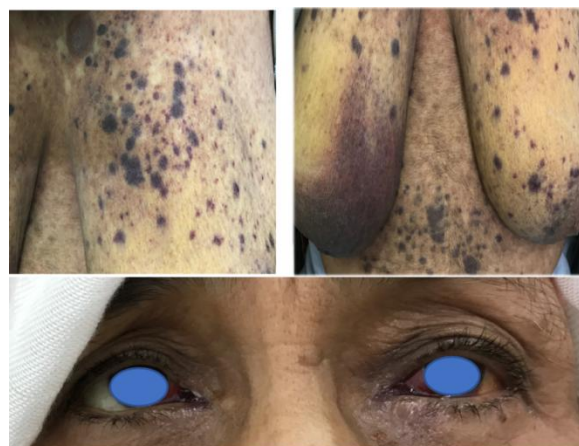
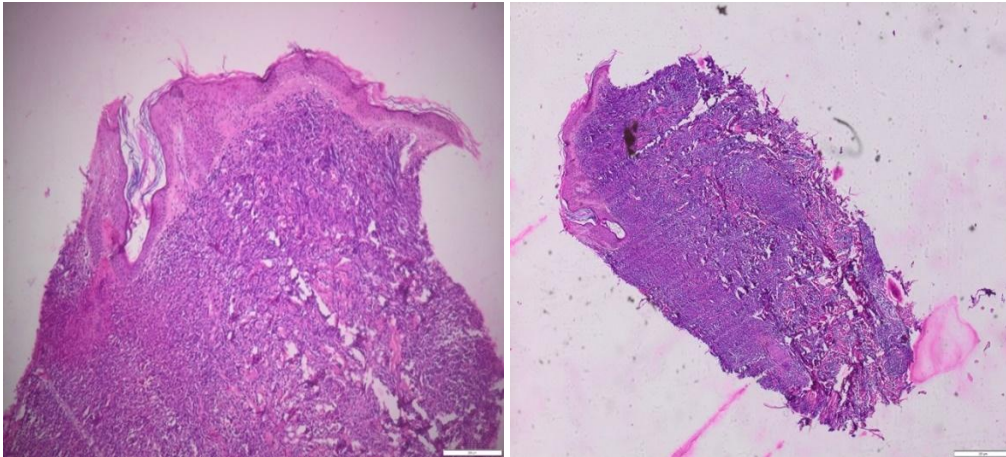


Fig-1: Characteristic violaceous nodules and papules of cutaneous involvement by blastic plasmacytoid dendritic cell neoplasm with subconjunctival hemorrhage

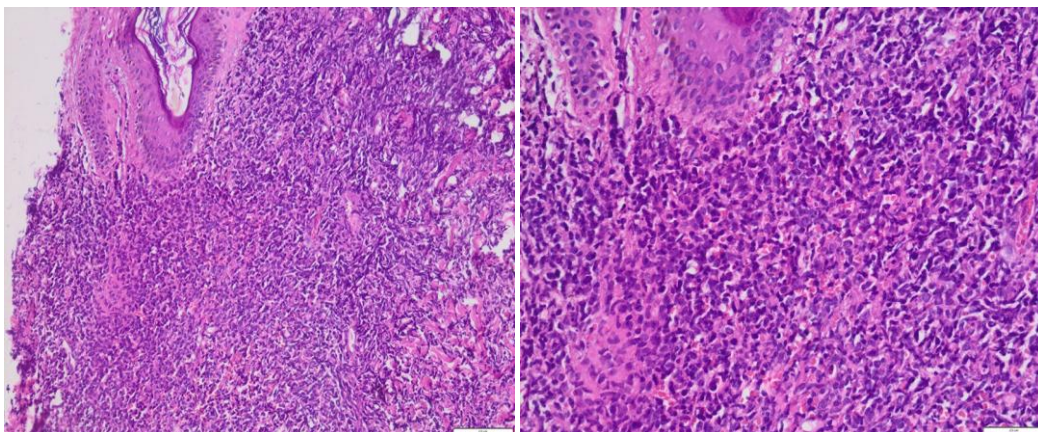
The lesions had been present for more than 4 months without any other symptoms. Hematologic explorations revealed a hemoglobin concentration of 6 g/dL. Serum lactate dehydrogenase (LDH) was elevated to 500 IU/L.

The first biopsy revealed undifferentiated lymphoma and the second one performed with immunohistochemistry showed that neoplastic cells expressed CD43. They were positive for CD56, CD4 and KI67 was 80%.

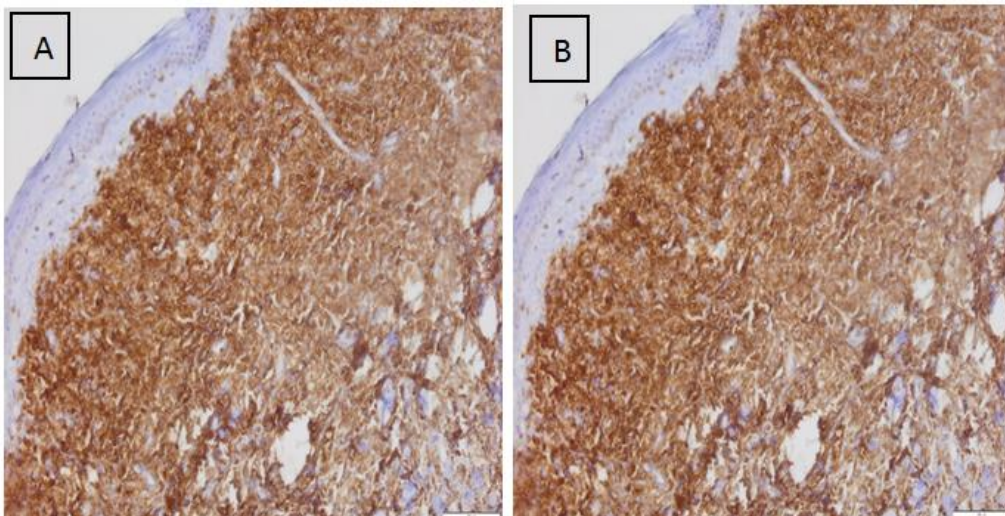
Morphologic features of blastic plasmacytoid dendritic cell neoplasm:

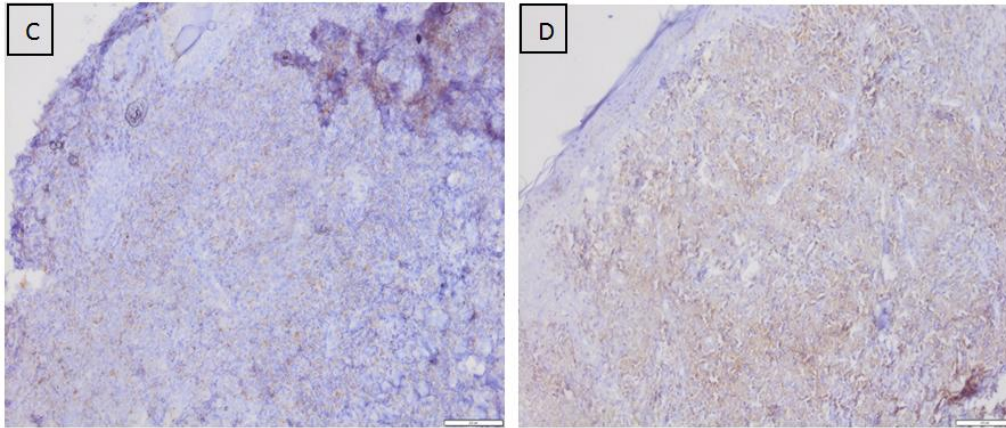


A: Dense neoplastic infiltrate in the dermis with a patchy periadnexal accentuation. The epidermis is intact

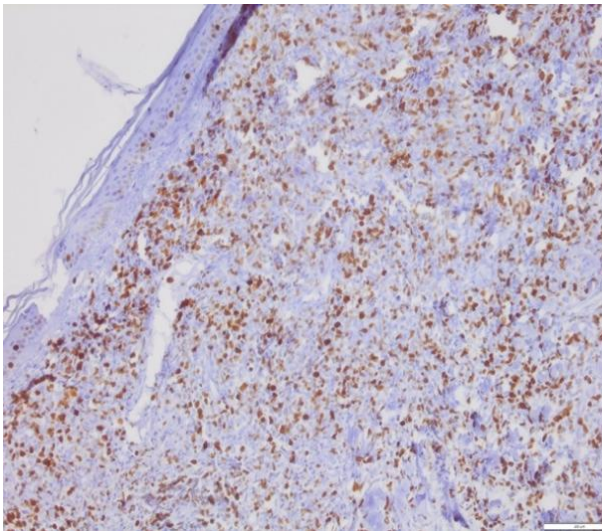


B: The neoplastic cells are medium to big sized with moderate cytoplasm with irregular border fine chromatin





Tumor cells show immunoreactivity for CD43(A), CD4 (B), CD68 « en dot » (C) et le CD56 (D) IHC x 200



High Ki-67 expression in 76%

The bone marrow expressed 54% of lymphoid cells with different size and shape with lymphoplasmacytic and undifferentiated cells. The plasma cells were expressed in 4%.

No lymphadenopathy, splenomegaly or hepatomegaly were palpable. Based on skin lesions, monomorphic and diffuse infiltrate in the dermis composed of medium and big sized cells with blastic appearance and phenotypic (CD4+, CD56+) features the diagnosis of BPDCN was made.

Three week later the initial diagnosis the patient presented general fatigue and dyspnea. The staging investigations were not done, the patient died 4 weeks after.

DISCUSSION

BPDCN is a very rare form of lymphoma-like disease, reported in 1994, for the first time, in a patient with violaceous nodules on the skin [4].

The 2008 update of the WHO classification of Tumors of Haematopoietic and Lymphoid Tissue included the title 'blastic plasmacytoid dendritic cell

neoplasm (BPDCN) [5]. Less than 100 cases of BPDCN have been reported in the English literature.

Immunophenotypical studies have confirmed the expression of CD123 by tumor cells, suggesting that hematological neoplasm derives from plasmacytoid dendritic cell (PDC) precursor [6, 5, 7].

The few available data reported that its extremely rare, accounting from 0,44% of all hematological malignancies [28] to 0,7% of cutaneous lymphomas [29]. The leukemic form of disease represents less than 1% of acute leukemia cases [30].

BPDCN typically affects older males, with a median diagnostic age of 67 years [8]. In the pediatric population, BPDCN is exceedingly rare, with only 33 cases published cases to date [9].

According to the literature, almost 85% of cases of BPDCN show cutaneous involvement at presentation [10, 11]. Cutaneous lesions typically present with asymptomatic, solitary or multiple nodules, plaques or bruise-like infiltrates with variable shape and color and size associated or not with purpura or hyperpigmentation [12].

Lymphadenopathy, splenomegaly and cytopenia due to bone marrow involvement can be present at diagnosis or may occur at disease progression [13].

To our knowledge this is the first study to describe the aggressiveness of BPDCN presenting with subconjunctival hemorrhage, disseminated lesions and fatal outcome.

Mucosal involvement has rarely been described in the literature. Two cases with pharynx involvement have been reported [14].

Disseminated cutaneous lesions are characterized by the association of nodules, papules and purpuric generalized macules.

Diagnosis is made on skin biopsy, which shows an infiltration of the dermis by a population of monomorphous intermediate size cells, with fine chromatin without necrosis or vascular infiltration. Bone marrow aspiration may show or not atypical blast cells.

The presence of more than 20% of blast cells infiltrating the bone marrow confirms leukemia of plasmacytoid dendritic cell lineage diagnosis. Phenotypic features have recently been confirmed [15, 16].

The diagnosis must be confirmed by either immunohistochemistry or by flow cytometry, depending on the material available.

The diagnosis relies on the demonstration of CD4 and CD56 positivity by tumor cells, together with markers more restricted to plasmacytoid dendritic cells, CD123, TCL1.

BPDCN has been assessed by array comparative genomic hybridization (CGH) analyses confirm that loss of genetic material is much more frequent than presence of additional genetic material [17-19].

It was suggested in recent study that genes CDKN2A/CDKN2B on 9p21.3 is frequently lost [13, 20]. The clinical course of BPDCN is aggressive leukemia median overall survival ranging from 12 to 16 months [21, 6]. Because of its low incidence, prospective data are lacking and the few series published so far rarely exceed 15 cases [13].

The best treatment for BPDCN is unknown. In general, intensive induction regimens (hyperCVAD) are considered more effective compared to standard therapies (CHOP-like). In general, ALL-like treatments seem to be more effective in term of response rates than AML-like induction therapies [21-24].

There are several reports suggesting better results with allogeneic-stem cell transplantation (allo-SCT) compared to auto-SCT in BPDCN therapy.

These studies demonstrated durable complete remissions with allo-SCT at 3 years depending on the follow-up period. With chemotherapy, prognosis is still poor, and median overall survival often remains inferior to 2 years [13].

Targeted therapies are currently under development with promising results [2]. Recent studies show that BPDCN survival depends on the anti-apoptotic protein BCL-2, which is highly expressed in BPDCN compared to normal plasmacytoid dendritic cells [25].

The BCL-2 inhibitor venetoclax is currently under evaluation in combination with induction chemotherapy and hypomethylating agents [26, 27].

Several experiences show that venetoclax seems safe, effective and adapted in treatment of BPDCN, in elderly patients with skin involvement. In conclusion BPDCN is a rare disease with a poor prognosis underdiagnosed and underreported.

Given this aggressiveness multiple analysis including genetic, molecular and immunohistochemical are needed to make an exact and quick diagnosis of BPDCN and to optimize the therapeutic management of this disease.

REFERENCES

1. Campo E, Swerdlow SH, Harris NL, Pileri S, Stein H, Jaffe ES. The 2008 WHO classification of lymphoid neoplasms and beyond: evolving concepts and practical applications. *Blood, The Journal of the American Society of Hematology*. 2011 May 12;117(19):5019-32.
2. Sapienza MR, Pileri A, Derenzini E, Melle F, Motta G, Fiori S, Calleri A, Pimpinelli N, Tabanelli V, Pileri S. Blastic plasmacytoid dendritic cell neoplasm: state of the art and prospects. *Cancers*. 2019 May;11(5):595.
3. Norris D, Stone J. WHO classification of tumours of haematopoietic and lymphoid tissues. Geneva: WHO. 2008:22-3.
4. Adachi M, Maeda K, Takekawa M, Hinoda Y, Imai K, Sugiyama S, Yachi A. High expression of CD56 (N-CAM) in a patient with cutaneous CD4-positive lymphoma. *American journal of hematology*. 1994 Dec;47(4):278-82.
5. Swerdlow SH. WHO classification of tumours of haematopoietic and lymphoid tissues. WHO classification of tumours. 2008;22008:439.
6. Petrella T, Comeau MR, Maynadié M, Couillault G, De Muret A, Maliszewski CR, Dalac S, Durlach A, Galibert L. Agranular CD4+ CD56+ hematodermic neoplasm (blastic NK-cell lymphoma) originates from a population of CD56+ precursor cells related to plasmacytoid monocytes. *The American journal of surgical pathology*. 2002 Jul 1;26(7):852-62.
7. Chaperot L, Bendriss N, Manches O, Gressin R, Maynadié M, Trimoreau F, Orfeuvre H, Corront B, Feuillard J, Sotto JJ, Bensa JC. Identification of a leukemic counterpart of the plasmacytoid dendritic cells. *Blood, The Journal of the American Society of Hematology*. 2001 May 15;97(10):3210-7.
8. Magro CM, Porcu P, Schaefer J, Erter JW, Furman RR, Shitabata PK, Crowson AN. Cutaneous CD4+ CD56+ hematologic malignancies. *Journal of the American Academy of Dermatology*. 2010 Aug 1;63(2):292-308.

9. Nguyen CM, Stuart L, Skupsky H, Lee YS, Tsuchiya A, Cassarino DS. Blastic plasmacytoid dendritic cell neoplasm in the pediatric population: a case series and review of the literature. *The American Journal of Dermatopathology*. 2015 Dec;37(12):924.
10. Guo J, Si L, Kong Y, Flaherty KT, Xu X, Zhu Y, Corless CL, Li L, Li H, Sheng X, Cui C. Phase II, open-label, single-arm trial of imatinib mesylate in patients with metastatic melanoma harboring c-Kit mutation or amplification. *Journal of clinical oncology*. 2011 Jul 20;29(21):2904-9.
11. Rauh MJ, Rahman F, Good D, Silverman J, Brennan MK, Dimov N, Liesveld J, Ryan DH, Burack WR, Bennett JM. Blastic plasmacytoid dendritic cell neoplasm with leukemic presentation, lacking cutaneous involvement: Case series and literature review. *Leukemia research*. 2012 Jan 1;36(1):81-6.
12. Julia F, Petrella T, Beylot- Barry M, Bagot M, Lipsker D, Machet L, Joly P, Dereure O, Wetterwald M, d'Incan M, Grange F. Blastic plasmacytoid dendritic cell neoplasm: clinical features in 90 patients. *British Journal of Dermatology*. 2013 Sep;169(3):579-86.
13. Pagano L, Valentini CG, Grammatico S, Pulsoni A. Blastic plasmacytoid dendritic cell neoplasm: diagnostic criteria and therapeutical approaches. *British journal of haematology*. 2016 Jul;174(2):188-202.
14. Hashikawa K, Niino D, Yasumoto S, Nakama T, Kiyasu J, Sato K, Kimura Y, Takeuchi M, Sugita Y, Hashimoto T, Ohshima K. Clinicopathological features and prognostic significance of CXCL12 in blastic plasmacytoid dendritic cell neoplasm. *Journal of the American Academy of Dermatology*. 2012 Feb 1;66(2):278-91.
15. Marafioti T, Paterson JC, Ballabio E, Reichard KK, Tedoldi S, Hollowood K, Dictor M, Hansmann ML, Pileri SA, Dyer MJ, Sozzani S. Novel markers of normal and neoplastic human plasmacytoid dendritic cells. *Blood, The Journal of the American Society of Hematology*. 2008 Apr 1;111(7):3778-92.
16. Petrella T, Facchetti F. Tumoral aspects of plasmacytoid dendritic cells: what do we know in 2009?. *Autoimmunity*. 2010 May 1;43(3):210-4.
17. Lucioni M, Novara F, Fiandrino G, Riboni R, Fanoni D, Arra M, Venegoni L, Nicola M, Dallera E, Arcaini L, Onida F. Twenty-one cases of blastic plasmacytoid dendritic cell neoplasm: focus on biallelic locus 9p21. 3 deletion. *Blood, The Journal of the American Society of Hematology*. 2011 Oct 27;118(17):4591-4.
18. Oiso N, Tatsumi Y, Arao T, Rai S, Kimura M, Nakamura S, Itoh T, Nishio K, Matsumura I, Kawada A. Loss of genomic DNA copy numbers in the p18, p16, p27 and RB loci in blastic plasmacytoid dendritic cell neoplasm. *European Journal of Dermatology*. 2012 May 1;22(3):393-4.
19. Stenzinger. Which confirm that loss of genetic material is much more frequent than presence of additional genetic material. Furthermore, proteins that regulate cell cycle are preferentially targeted. CDKN2A/CDKN2B on 9p21_3 is frequently lost. Other frequently deleted regions include 13q13_1-q14_3 (RB1), 12p13_2-p13_1 (CDKN1B), 13q11-q12 (LATS2). 2014.
20. Lucioni M, Novara F, Fiandrino G, Riboni R, Fanoni D, Arra M, Venegoni L, Nicola M, Dallera E, Arcaini L, Onida F. Twenty-one cases of blastic plasmacytoid dendritic cell neoplasm: focus on biallelic locus 9p21. 3 deletion. *Blood, The Journal of the American Society of Hematology*. 2011 Oct 27;118(17):4591-4.
21. Feuillard J, Jacob MC, Valensi F, Maynadié M, Gressin R, Chaperot L, Arnoulet C, Brignole-Baudouin F, Drénou B, Duchayne E, Falkenrodt A. Clinical and biologic features of CD4+ CD56+ malignancies. *Blood, The Journal of the American Society of Hematology*. 2002 Mar 1;99(5):1556-63.
22. Deotare U, Kim D, Michelis FV, Lipton JH. Allogeneic Hematopoietic Stem Cell Transplantations in Blastic Plasmacytoid Dendritic Cell Neoplasm in first complete remission: an effective therapy for a rare disease. *Leukemia & lymphoma*. 2016 Aug 2;57(8):1942-4.
23. Pagano L, Valentini CG, Pulsoni A, Fisogni S, Carluccio P, Mannelli F, Lunghi M, Pica G, Onida F, Cattaneo C, Piccaluga PP. Blastic plasmacytoid dendritic cell neoplasm with leukemic presentation: an Italian multicenter study. *Haematologica*. 2013 Feb 1;98(2):239-46.
24. Tsagarakis NJ, Kentrou NA, Papadimitriou KA, Pagoni M, Kokkini G, Papadaki H, Pappa V, Marinakis T, Anagnostopoulos NI, Vadikolia C, Anagnostopoulos A. Acute lymphoplasmacytoid dendritic cell (DC2) leukemia: results from the Hellenic Dendritic Cell Leukemia Study Group. *Leukemia research*. 2010 Apr 1;34(4):438-46.
25. Montero J, Stephansky J, Cai T, Griffin GK, Cabal-Hierro L, Togami K, Hogdal LJ, Galinsky I, Morgan EA, Aster JC, Davids MS. Blastic plasmacytoid dendritic cell neoplasm is dependent on BCL2 and sensitive to venetoclax. *Cancer discovery*. 2017 Feb 1;7(2):156-64.
26. DiNardo CD, Pratz K, Pullarkat V, Jonas BA, Arellano M, Becker PS, Frankfurt O, Konopleva M, Wei AH, Kantarjian HM, Xu T. Venetoclax combined with decitabine or azacitidine in treatment-naive, elderly patients with acute myeloid leukemia. *Blood*. 2019 Jan 3;133(1):7-17.
27. DiNardo CD, Rausch CR, Benton C, Kadia T, Jain N, Pemmaraju N, Daver N, Covert W, Marx KR, Mace M, Jabbour E. Clinical experience with the BCL 2- inhibitor venetoclax in combination therapy for relapsed and refractory acute myeloid leukemia and related myeloid malignancies.

- American journal of hematology. 2018 Mar;93(3):401-7.
28. Bueno PR, Orlandi MO, Simoes LG, Leite ER, Longo E, Cerri JA. Nonohmic behavior of SnO 2-MnO polycrystalline ceramics. I. Correlations between microstructural morphology and nonohmic features. Journal of Applied Physics. 2004 Sep 1;96(5):2693-700.
 29. Ng K, Lee J, Yap E, Kuan Y, Cheng H, inventors; Avago Technologies ECBU IP Singapore Pte Ltd, assignee. Field-sequential color display with feedback control. United States patent application US 10/970,911. 2006 May 11.
 30. Nielsen J. Jakob Niensens Alertbox, August 25, 2003.