

## Role of Nasal Endoscopy for the Evaluation of Epistaxis

Dr. Md. Mukhlesur Rahman<sup>1\*</sup>, Dr. Mojibul Haque Khan<sup>2</sup>, Dr. Mostafa Mahfuzul Anwar<sup>3</sup>, Dr. Mahmuda Begum<sup>4</sup>

<sup>1</sup>Assistant Professor, Dept. of Otolaryngology- Head and Neck, Surgery, Chittagong Medical College, Chattogram, Bangladesh

<sup>2</sup>Professor and Head (Ex), Dept. of Otolaryngology- Head and Neck, Surgery, Chittagong Medical College, Chattogram, Bangladesh

<sup>3</sup>Professor and Head, Dept. of Otolaryngology- Head and Neck, Surgery, Chittagong Medical College, Chattogram, Bangladesh

<sup>4</sup>Assistant Professor, Dept. of Pathology, Chittagong Medical College, Chattogram, Bangladesh

DOI: [10.36347/sjams.2020.v08i05.007](https://doi.org/10.36347/sjams.2020.v08i05.007)

| Received: 12.04.2020 | Accepted: 24.04.2020 | Published: 06.05.2020

\*Corresponding author: Dr. Md. Mukhlesur Rahman

### Abstract

### Original Research Article

**Objective:** In this study our main goal is to evaluate the role of nasal endoscopy for the evaluation of epistaxis. **Method:** This cross-sectional study was conducted among 50 patients who fulfilled criteria from department of otolaryngology-Head and neck surgery, Chittagong medical College and hospital, Chattogram from January 2017 to January 2019. **Results:** During the study, most of the patients belong to 41-50 years age group, 36%. 10% had nasal polyp, 26% had DNS, septal spur with ulceration, and 30% had bleeding point high in lateral nasal wall crevices. 38% treated with endoscopic nasal packing. Followed by 10% treated with endoscopic polypectomy, 26% treated with endoscopic nasal cautery. **Conclusion:** From our study we can conclude that, a nasal endoscope is the only hope to prevent trauma to the normal mucosa due to these packing materials and Instruments. Further study is needed for better outcome.

**Keywords:** Nasal endoscopy, epistaxis, otolaryngology.

**Copyright © 2020:** This is an open-access article distributed under the terms of the Creative Commons Attribution license which permits unrestricted use, distribution, and reproduction in any medium for non-commercial use (NonCommercial, or CC-BY-NC) provided the original author and source are credited.

## INTRODUCTION

Epistaxis is one of the common symptoms encountered in the otolaryngology. Many times, the cause for epistaxis is not found on anterior and posterior rhinoscopy. It is a common clinical condition and not a specific disease process, but it is essentially a symptom complex. It is the most frequent emergency in Otolaryngology, presenting with a prevalence of about 10% to 12% [1-3]. Most of the time, it is able to locate the cause or the bleeding point. One of the principal reasons being the poor visualization of the covert areas of the nose, which are situated in the deep crevices of the lateral wall of the nose. Anterior and posterior

rhinoscopy thus, has its limitations. In this study our main goal is to evaluate the role of nasal endoscopy for the evaluation of epistaxis [4].

## OBJECTIVE

### General objective

- To assess the role of nasal endoscopy for the evaluation of epistaxis.

### Specific objective

- To detect abnormalities found in nasal endoscopy.
- To identify endoscopic management of epistaxis.

## METHODOLOGY

| Type of study      | Cross-sectional study  |
|--------------------|--|
| Place of study     | Department of otolaryngology-Head and neck surgery, chittagong medical college and hospital, chattogram. |
| Study period       | January 2017 to January 2019.  |
| Study population   | 50 patients included in the study who were fulfilled criteria.   |
| Sampling technique | Purposive  |

### Study procedure

During the study, face to face interview of the participants were conducted with the semi-structured, pre-tested questionnaire. The interview was conducted anonymously and privately as much as possible. Before

preceding the data collection, the detail of the study was explicitly explained to each eligible respondent and informed written consent from the respondents were obtained.

### Data Analysis

Descriptive statistics were presented with relative frequency and percentage.

## RESULT

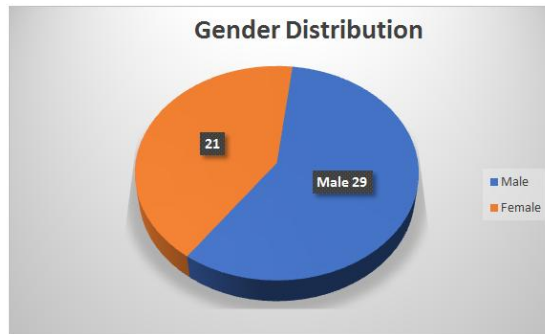
In table-1 shows age distribution of patients where most of the patients belong to 41-50 years age group, 18(36%). The following table is given below in detail:

**Table-1: Age distribution of patients**

| Age group in years | Frequency | Percentage (%) |
|--------------------|-----------|----------------|
| ≤20                | 5         | 10             |
| 21-30              | 7         | 14             |
| 31-40              | 5         | 10             |
| 41-50              | 18        | 36             |
| 51-60              | 11        | 22             |
| 61-70              | 4         | 8              |
| Total              | 50        | 100            |

In figure-1 shows distribution of patients according to the gender where (29) 58% patients were

male, which was 16% higher than female (21) 42%. The following figure is given below in detail:



**Fig-1: Distribution of patients according to the gender**

In table-3 shows abnormalities found in nasal endoscopy. Where 15 (30%) has bleeding point in the crevices of lateral nasal wall followed by 13 (26%) had

DNS, Septal spur with ulceration. The following table is given below in detail:

**Table-3: Endoscopic diagnosis**

| Diagnosis  | Frequency | Percentage (%) |
|--|-----------|----------------|
| Bleeding point in the crevices of lateral nasal  | 15        | 30             |
| DNS, Septal spur with ulceration                 | 13        | 26             |
| Nasal Polyp                                      | 5         | 10             |
| Enlarge adenoids                                 | 5         | 10             |
| Scabs or crust in crevices in lateral nasal wall | 6         | 12             |
| Angiofibroma                                     | 2         | 4              |
| No significant cause                             | 4         | 8              |
| Total  | 50        | 100            |

In table-4 shows endoscopic management of epistaxis. 19 (38%) treated with endoscopic nasal packing. Followed by 13 (26%) treated with endoscopic

cautery or diathermy. The following table is given below in detail:

**Table-4: Endoscopic management of epistaxis**

| Endoscopic management                 | Frequency | Percentage (%) |
|---------------------------------------|-----------|----------------|
| Endoscopic nasal cautery or diathermy | 13        | 26             |
| Endoscopic nasal packing              | 19        | 38             |
| Endoscopic polypectomy                | 5         | 10             |
| Adenoidectomy                         | 5         | 10             |
| Nasal douching                        | 6         | 12             |
| Excision of angiofibroma              | 2         | 4              |
| Total                                 | 50        | 100            |

## DISCUSSION

Epistaxis is one of the commonest ENT emergencies. Prevalence of the disease can be up to 60% of the general population [5, 6]. Male patients are more prone to be affected [7, 11, 12]. Which is supported by our studies where 58% patients were male and 42% were female.

Usually epistaxis is spontaneous, mild and stops spontaneously following pinching of external nose (Hippocratic method), but it may occur following nose blowing and strenuous work. Sometimes it may be profuse which can lead to haemodynamic instability requiring urgent interference. Epistaxis can be divided into two types, anterior and posterior, depending upon the source of bleeding anterior or posterior to pyriform aperture. Usually, anterior epistaxis is commonly seen in young population and posterior epistaxis is seen in old population. In our study, we found that, most of the patients belong to 41-50 years age group 36%, similar findings were seen in one study [11].

In one study they found that, between 70 - 80% of all cases of epistaxis are idiopathic, spontaneous bleeds without any proven precipitant or casual factor. This type is called primary epistaxis. Whereas, when a clear and defined cause of epistaxis is found, then it is called secondary epistaxis [7].

Nasal endoscopy takes an important role in evaluating the epistaxis. It helps to reveal the hidden pathologies inside the nasal cavity that can be missed during the anterior and posterior rhinoscopy. It is not always possible to detect the pathology of nasal cavity by anterior and posterior rhinoscopy. Moreover, posterior rhinoscopy is very difficult in most of the cases due to excessive gag reflex. So, pathologies for posterior epistaxis remain undetected by conventional examination. Nasal endoscopy helps to detect those pathologies inside nasal cavity that can be easily missed by clinical examination [10]. In our study we also identified that, 10% had nasal polyp, 26% had DNS, septal spur with ulceration, 30% had bleeding point high in lateral nasal wall crevices, similar findings were seen in one study [13]. Most of these diagnosed cases were managed successfully by endoscopic nasal packing 38%, and by endoscopic nasal cautery or diathermy 26%, similar finding was seen in one study [14].

## CONCLUSION

From our study we can conclude that, a nasal endoscope is the only hope to prevent trauma to the normal mucosa due to these packing materials and instruments. Further study is needed for better outcome.

## REFERENCES

1. Vershney S, Saxena RK. Epistaxis- a retrospective clinical study. Indian J Otolaryngol Head Neck Surg. 2005; 57: 125 – 5.
2. Nwaorgu OGB. Epistaxis – an overview. Ann Ibadan Postgrad med. 2004; 1: 1597- 627.
3. Kucik CJ, Clenney T. Management of epistaxis. Am Fam Physician. 2005; 71:305-11.
4. Viehweg TL, Robertson JB, Hudson JW. Epistaxis: diagnosis and management and treatment. J Oral Maxillofac Surg. 2006; 64: 511 – 8.
5. Abbas N, Hussain I, Amjad M, Akthar FP. Etiological incidence of epistaxis in various age and sex groups in a hospital, Lahore. Ann King Edward Med Coll. 1998; 4: 18-9.
6. Ahmed I, Raza SN, Bashir T, Arshad M. Paediatric epistaxis. Pak Postgrad Med J. 2000; 11: 106 – 8.
7. Stell PM. Epistaxis. Clinical Otolaryngology. 1977; 2: 263 – 73.
8. Hazarika P, Nayak DR, Balakrishnan R, Raj G, Pillai S. Endoscopic and KTP laser-assisted surgery for juvenile nasopharyngeal angiofibroma. American journal of otolaryngology. 2002 Sep 1;23(5):282-6.
9. Mann WJ, Jecker P, Amedee RG, and Juvenile angiofibromas: Changing surgical concept over the last 20 years. Laryngoscope. 2004; 114: 291 - 3.
10. Jorissen M, Eloy P, Rombaux P, Bachert C, Daele J. Endoscopic sinus surgery for juvenile nasopharyngeal angiofibroma. Acta oto-rhino-laryngologica belgica. 2000;54(2):201-19.
11. Vanshney S, Saxena RK. Epistaxis: A retrospective clinical study. 2005;5(2):125-129 .
12. Almeida GS, Diógenes CA, Pinheiro SD. Nasal endoscopy and localization of the bleeding source in epistaxis: last decade's revolution. Brazilian journal of otorhinolaryngology. 2005;71(2):146-8.
13. Vinay Kumar MV, Raghavendra Prasad KU, Belure Gowda PR, Manohar SR, Chennaveerappa PK. Rigid nasal endoscopy in the diagnosis and treatment of epistaxis. Journal of clinical and diagnostic research: JCDR. 2013 May;7(5):831.
14. Babu DMM, Gowda DB, Satish DHS. Role of rigid endoscopy in the diagnosis and management of epistaxis. 2014;13(3):40-45.