

The Spectrum of Benign Breast Diseases in Ile-Ife: A 5 Year Clinicopathologic Review of Breast Lumps

KOLAWOLE Oladapo Adedayo^{1*}, ADESUNKANMI Abdul Rasheed Kayode², ADEROUNMU Adewale Abdulwasiiu³¹Department of Surgery, Ladoke Akintola University of Technology Teaching Hospital, Osogbo, Osun State, Nigeria^{2,3}Department of Surgery, Obafemi Awolowo University Teaching Hospitals Complex, Ile-Ife, Osun State, NigeriaDOI: [10.36347/sjams.2020.v08i05.011](https://doi.org/10.36347/sjams.2020.v08i05.011)

| Received: 29.04.2020 | Accepted: 07.05.2020 | Published: 08.05.2020

*Corresponding author: Kolawole, Oladapo Adedayo

Abstract

Original Research Article

The magnitude of breast complaints to the general surgeon cannot be overemphasized, as breast diseases are rather common conditions presenting to the surgeon, and the vast majority of these conditions are benign. We undertook a review of breast biopsies performed at the Obafemi Awolowo University Teaching Hospitals Complex, Ile Ife, Southwestern Nigeria over a 5 year period, with the aim of determining the clinical and pathologic spectrum of benign breast diseases in patients who had excision biopsy of breast lumps. Out of the 238 breast lump excisions, Fibroadenoma had the highest frequency, 148 (62.3%), followed by fibrocystic disease being 48 (20.2%). The remaining 17.4% being accounted for by Inflammatory and other conditions. Fibroadenoma occurred mostly in females in their 2nd and 3rd decades, while fibrocystic disease occurred mostly in females in their 3rd - 5th decades. Most of the lesions were situated in the upper outer quadrant of the breast. The associated symptoms are breast pain (8.8%), and nipple discharge (3.8%). There were 20 recurrent cases (8.4%), all of which were fibroadenomas. Fibroadenoma remains the most common benign breast lesion in our environment, followed by fibrocystic disease.

Keywords: Benign breast disease, Fibroadenoma, Fibrocystic disease, Excision.

Copyright @ 2020: This is an open-access article distributed under the terms of the Creative Commons Attribution license which permits unrestricted use, distribution, and reproduction in any medium for non-commercial use (NonCommercial, or CC-BY-NC) provided the original author and source are credited.

INTRODUCTION

Diseases of the breast are quite common conditions presenting to General Surgical Clinics, and benign breast diseases are the most common lesions, accounting for about 90% of the clinical presentation of breast complaints [1]. Breast complaints usually cause anxiety and fear in patients due to the fear of the possibility of the diagnosis of breast cancer [2]. Common complaints of breast problems are mostly breast lump or mass, occasionally breast pain, and nipple discharge [3]. Up to 50% of women suffer from a benign breast disorder requiring treatment at some time in their lives [4, 5], these benign breast lesions being confined to the breast throughout the course of the disease [6]. The most common benign breast disorders in premenopausal women are Fibroadenomas and Fibrocystic disease [2]. Fibroadenomas are benign solid tumors developing from a terminal duct lobular unit and present as localized, discrete masses [7] while Fibrocystic disease comprises a complex of cyst formation, apocrine metaplasia, sclerosing adenosis and epithelial hyperplasia, and presents with cyst formation, as a semi discrete mass or an ill-defined thickening or nodularity [7]. Duct ectasia, breast abscess, fat necrosis, nipple retraction and duct papilloma are other benign

breast conditions seen in surgical clinics, amongst others.

This study aims to evaluate the clinicopathologic pattern and treatment outcome of benign breast lumps excised in a Nigerian Tertiary Hospital.

MATERIALS AND METHODS

This was a retrospective review of breast biopsies taken at the Obafemi Awolowo University Teaching Hospitals Complex, Ile-Ife, Southwestern Nigeria between January 2006 and December 2010.

A total of 238 patients with clinical diagnosis of benign breast lumps had breast biopsies during the period of the study. Clinical information of the cases and histology data were obtained from the case notes and from the Department of Histopathology. Details included the patients' age, sex, duration of symptoms, side affected, menarche, parity and hormonal contraceptive use, history of pain, palpable lumps, and nipple abnormality were also obtained. Histopathology reports were studied, and significant events occurring during the follow-up period were recorded. Statistical analysis was done using the SPSS version 20.

RESULTS

There were 238 patients who had lump excision for clinically diagnosed benign breast lesions during the period of the study, 235 (98.7%) females and 3 (1.3%) males, giving a Male: Female ratio of 1:76.

The age range was from 10 to 80 years, with a mean age of 27.58 ± 11.41 . The age group with the highest frequency of breast pathology is the 20-29 year group, followed by the teenagers, in the 10-19 year group. The age distribution is shown in Figure-1 below.

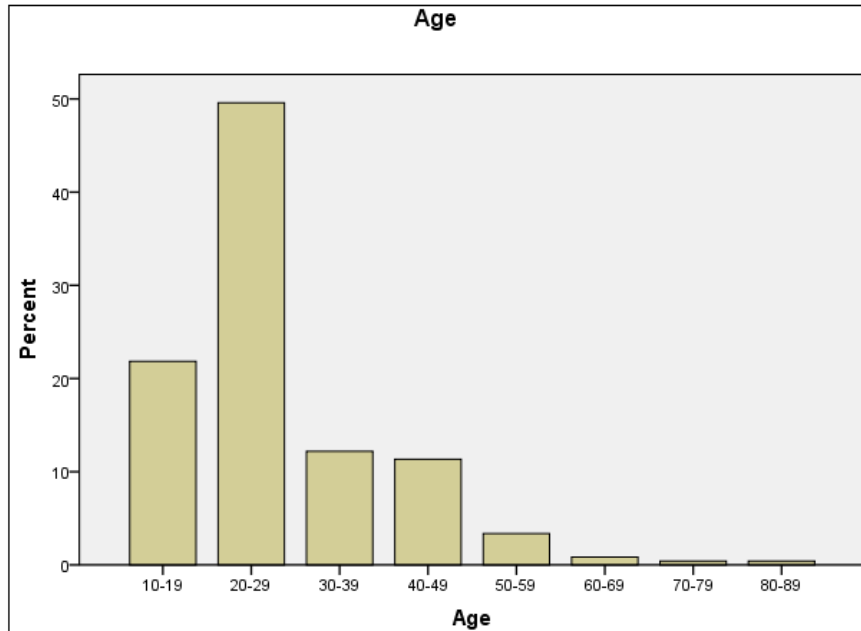


Fig-1: Age Distribution

The histopathology reports confirmed 220 of the specimens to be benign and 18 malignant, thus 92.4% of the excised lumps were benign.

Fibroadenoma was most common 148 (62.3%), followed by fibrocystic disease being 48

(20.2%). The remaining 17.4% being accounted for by inflammatory conditions, breast abscess, intraductal papilloma, fibrolipoma, phyllodes tumor, malignant lesions, etc. These are illustrated in Table-1 and Figure-2 below.

Table-1: Diagnosis

Histology	Frequency	Percent
Fibroadenoma	148	62.2
Fibrocystic disease	48	20.2
Inflammation	3	1.26
Tuberculosis	2	.84
Fibrolipoma	3	1.26
Gynaecomastia	3	1.26
Phylloides	2	.84
Breast abscess	4	1.68
Duct ectasia	2	.84
Malignant	18	7.56
Benign cyst	2	.84
Intraductal papilloma	3	1.26
Total	238	100.0

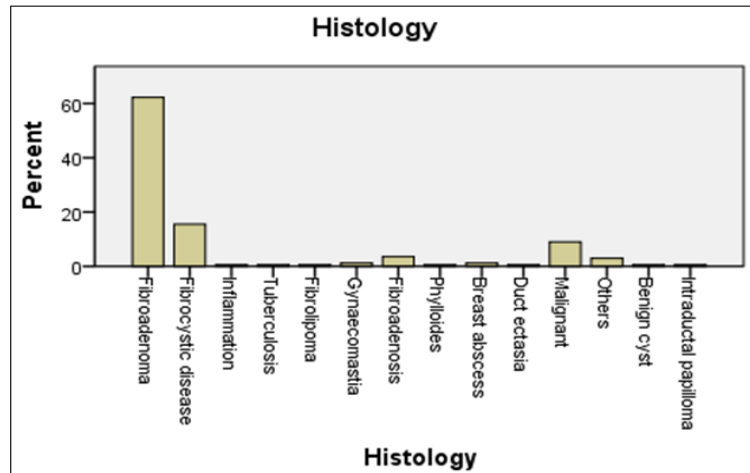


Fig-2: Histologic Diagnosis

Fibroadenoma, being the most common pathology, was found mostly in the 20-29 year age group, followed by the 10-19 year age group. The mean age was 24.3 years. The next was fibrocystic disease which occurred mostly in the 40-49 year age group,

followed by the 30-39 year age group, with a mean age of 37.2 years. Other pathologies occurred in patients mostly in their fourth to sixth decades, and the elderly patients having the least. These are shown in the Table 2 and Figure-3 below.

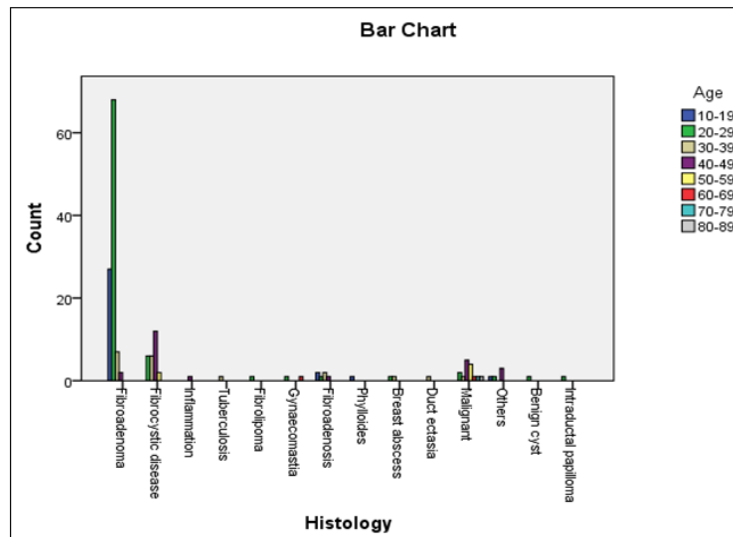


Fig-3: Diagnosis with age distribution

Table-2: Histology with Age Cross-tabulation

Histology	Age								Total
	10-19	20-29	30-39	40-49	50-59	60-69	70-79	80-89	
Fibroadenoma	37	93	13	5	0	0	0	0	148
Fibrocystic disease	2	9	14	20	3	0	0	0	48
Inflammation	0	0	2	1	0	0	0	0	3
Tuberculosis	0	0	2	0	0	0	0	0	2
Fibrolipoma	0	2	1	0	0	0	0	0	3
Gynaecomastia	0	2	0	0	0	1	0	0	3
Phylloides	1	0	1	0	0	0	0	0	2
Breast abscess	0	2	2	0	0	0	0	0	4
Duct ectasia	0	0	1	1	0	0	0	0	2
Malignant	0	2	1	5	5	2	2	1	18
Benign cyst	0	2	0	0	0	0	0	0	2
Intraductal papilloma	0	2	1	0	0	0	0	0	3
Total	40	114	38	32	8	3	2	1	238

The duration of symptoms prior to presentation was between 1 and 520 weeks for the fibroadenoma cases, with a mean of 59.49 ± 95.87 weeks. Twenty of them were pre-pubertal, and the age range at menarche was from 10 to 18 years with a mean of 14.18 ± 2.01 . For the 62 (26%) that were parous, the parity was from

1 to 8, with a mean of 3.11 ± 1.64 . Of those who have been sexually active, only 4% had a positive history of use of hormonal contraceptives. Figure-4 below illustrates the association of contraceptive use with the various conditions, and this was not statistically significant with regards to the diagnosis.

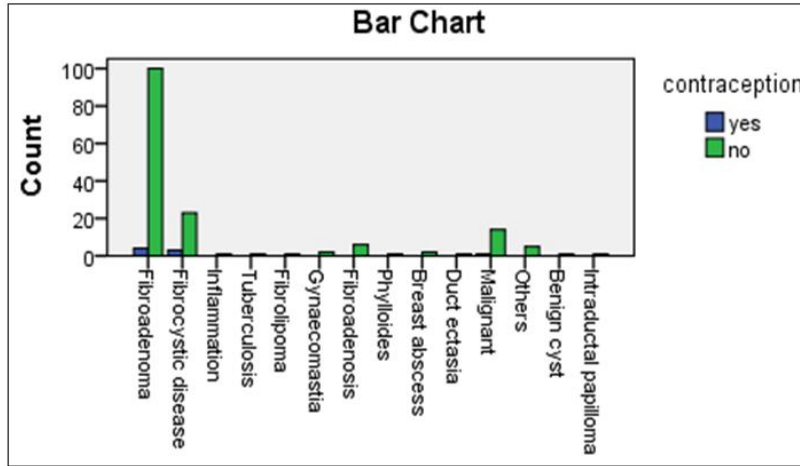


Fig-4: Use of hormonal contraceptives

One hundred and two (42.9%) of the biopsies were performed on the right breast and the same number were performed also on the left breast, while

biopsy was performed on both breasts in 34 (14.3%) cases. This is shown in Figure-5 below.

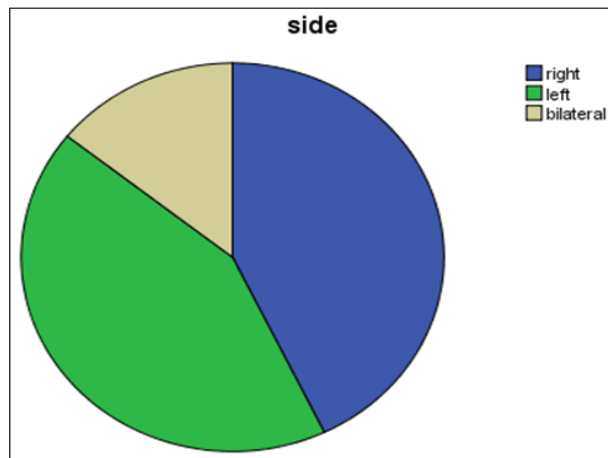


Fig-5: Side of lesion

The quadrants on the right breast from which the lumps were excised were stated in 127 (53.4%) cases while those on the left breast from which the

lumps were excised were stated in 129 (54.2%) cases. These are shown in Table-3 below.

Table-3: Location of lumps in the breast

	Right Breast		Left Breast	
	Frequency	Percentage	Frequency	Percentage
UOQ	49	20.6	59	24.8
UIQ	32	13.4	24	10.1
LOQ	32	13.4	29	12.2
LIQ	14	5.9	17	7.1
Not stated	111	46.7	109	45.8
Total	238	100.0	238	100.0

On both sides, the Upper Outer Quadrant (UOQ) was the location for majority of the lumps (20.6% on the right and 24.8% on the left) while the Lower Inner Quadrant (LIQ) had the least number of lumps (5.9% on the right and 7.1% on the left).

There was unilateral multiplicity of the lumps in 28 (11.8%) cases, and bilateral multiplicity in 4 (1.7%) cases.

Associated symptoms that the patients presented with include breast pain in 21 (8.8%), and nipple discharge in 9 (3.8%). Pain was associated with all the cases of abscess, and 32% of those with fibrocystic disease.

During the period of follow up, there were 20 (8.4%) recurrences, all fibroadenomas. Six (2.5%) were located on the right, 7 (2.9%) on the left, and 7 (2.9%) were bilateral.

DISCUSSION

Breast lumps are a very common presentation to general surgical clinics and a great number of patients present mainly due to the fear that the breast lump may be the very “dreaded” cancerous lesion. However, our study has shown over 90% of breast lumps were benign, similar to findings from several previous studies [1, 2].

Ninety eight point seven percent of our patients were females, which is similar to many other studies [2, 8] and quite close to 99% reported by Wahane *et al.*, in India[9].

The age range was from 10 to 80 years, the commonest age group was 20-29 year group, followed by the 10-19 year group, which agrees with findings by Isah *et al.*, [6]. Also, the mean age was 27.58 ± 11.4 years. It is seen that the cluster of breast conditions occurred mostly in those below 50 years. This is quite similar to many other studies. Das *et al* and other authors reported the common age group for benign breast diseases to be 21-40 years [5, 7, 10-13].

Fibroadenoma was the most common benign lesion in our study, which agrees with many other studies in Nigeria [6, 8, 16-18], among African-american teenage girls [19], in Pakistan [11], and India [13, 14, 16]. Though some other studies showed that Fibrocystic disease was the most common benign breast disease, [1, 7] in contrast to our study and other studies in this environment, though these occurred in older age groups, mostly in the 4th to 6th decades. In our study, fibrocystic disease was the 2nd most common benign breast lesion, occurring in 20.2% of cases, in consonance with several studies [3, 6, 11, 12, 14-16], with the highest number of cases occurring in the 40-49 year age group followed by the 30-39 year group, with a few occurring in patients less than 30 years. The mean

age for fibrocystic disease in our study was 37.2 years, similar to those in many other studies [12, 14-16]. Other histologic diagnoses accounted for 17.4%, including Breast abscess (1.68%) in lactating women, chronic inflammatory conditions like chronic breast abscess in 1.26%, tuberculosis in 0.84%, and malignancy in 7.56%. Seven point six percent in this study were to malignant breast lumps as supported by several studies which state that benign breast lumps are far more common than malignant lumps [1-3, 14-16].

History of hormonal contraceptive use was positive in 3.85% of the fibroadenoma cases, while 11.54% of the patients with fibrocystic disease had history of use, though this was not significantly associated with the diagnosis. This was probably due to the fact that majority of the patients with fibrocystic disease were older and in the more sexually active and child bearing age (mean age 37.2 years) than the majority of the patients with fibroadenoma (mean age 24.3 years). This is also corroborated by previous studies by Adesunkanmi and Agbakwuru in Ilesha, where the mean age for fibroadenoma presentation was 24 years and that of fibrocystic disease was 31.6 years [8], and also similar to a study by Uwaezuoke *et al* in Bayelsa, where the mean age for fibroadenoma presentation was 23.1 years, and that of fibrocystic disease 31.1 years [18]. A number of studies also corroborated the occurrence of fibroadenomas mostly in the 2nd to 3rd decades, while that of fibrocystic disease between the 3rd and 5th decades [13, 23]. Vakil *et al.*, reported in their study of Pakistan women, the peak age for fibroadenoma as 18 years, which is quite lower than that in our study, and that of fibrocystic disease being 45 years [11].

Our study showed that equal number of biopsies were performed on the right and left breasts (42.9%) for each side, while 14.3% biopsies were performed on both breasts simultaneously, indication bilateral lesions. This is however different from some other studies in which there was a right sided preponderance [8, 9, 13, 21] and few other studies which showed a left sided preponderance [22].

We also showed that the quadrant with the highest frequency of masses was the upper outer quadrant. This is corroborated by studies and one of the factors responsible for this is due to the increased density of the breast tissue in the upper outer quadrant [23] and the same was given to predilection for the upper outer quadrant in malignant lesions as well [23].

There were multiple lumps unilaterally in 11.8% of the cases (7.2% in fibrocystic disease and 4.6% in fibroadenomas), and bilateral multiplicity in 1.7% of the cases, all fibrocystic disease cases. Unilateral and bilateral multiplicity have also been documented in literature, for both fibroadenoma and fibrocystic disease [1]. The most common associated

symptom in our study was breast pain, which occurred in 8.8% of cases, followed by nipple discharge which was clear in all cases and occurred in 3.8% of cases. This finding is however different from several studies in which pain was associated with a much higher percentage of cases, with values ranging between 22 and 66% [5, 9, 13, 16,] and also higher percentages of associated nipple discharge Wahane *et al.*, 9% and Sangma *et al.*, 8% [9, 13]. The differences could be accounted for by the fact that our study was based mainly on excised lesions and not really as seen at the clinics where complaints of breast pain are much more common.

A total of 20 cases (8.4%) recurred within the period of the study and these were all fibroadenomas. 2.5% were located on the right, 2.9% on the left while 2.9% were bilateral. There was no malignancy found in any of the recurrent lumps. Our recurrence frequency of 8.4% is though lower, but rather close to other reports by Shrivastava and Jain who reported a recurrence rate of 10.52% each [3, 16]. Memon A *et al.*, in Pakistan, however reported a much lower recurrence rate of 3.4% [1].

The inflammatory conditions seen in this study may be deemed rather low, but this could be due to the fact that though inflammatory conditions are less common than the other benign conditions discussed above, most clinically diagnosed inflammatory conditions are treated with antibiotics and some have been incised and drained, thus leaving a very small proportion falling into the group requiring biopsy. This is also corroborated by other studies [24].

CONCLUSION

Benign breast diseases remain common in our environment, the most common being fibroadenoma, followed by fibrocystic disease, and most of these breast pathologies occur in women in their 2nd to 4th decades of life. Although most of the breast diseases that affect women in this age group are benign, the advocacy for better breast health education among women in terms of regular self and clinical breast examination, prompt presentation for early and prompt diagnosis and therapy cannot be overemphasized.

REFERENCES

- Memon A, Parveen S, Sangrarasi AK, Malik AM, Laghari A, Talpur KA. Changing Pattern of Benign Breast Lumps in Young Females World Journal Medical Sci. 2007; 2(1): 21-24.
- Prajapati CL, Jegoda RK, Patel UA, Patel J. Breast Lumps in a Teaching Hospital: A 5 Year Study. National Journal of Medical Research. 2014; 4(1): 65-67.
- Jain SB, Jain I, Shrivastav J, Jain B. A Clinicopathological study of breast lumps in patients presenting in Surgery OPD in a referral hospital in Madhya Pradesh, India. International Journal Current Microbiology Applied Science. 2015; 4(8): 919-923.
- Naveen N, Avijeet M, Vikrant M. A clinical study of benign breast disease in rural population. Journal of Evolution of Medical and Dental Sciences. 2003; 12: 5499-511.
- Bhargava GS, Grover A, Ded KS, Gupta A. Evaluation of Benign Breast Disorders in Females of Rural Punjab. Cibtech Journal of Surgery. 2015; 4(1): 19-23.
- Isah RT, Sahabi SM, Muhammad AT, Okechi OO, Mohammed OM. Analysis of Female Breast Biopsies in Usmanu Danfodiyo University Teaching Hospital (UDUTH) Sokoto, Nigeria; A Ten Year Retrospective Study. Journal of Dental and Medical Sciences (IOSR-JDMS) 2013; 8(4): 55-58.
- Ghani NA. Benign Breast Disorders –A Histiopathological Study in Tikrit City. Diyala Journal of Medicine. 2012; 3(1): 27-34.
- Adesunkanmi AR, Agbakwuru EA. Benign breast disease at Wesley Guild Hospital, Ilesha, Nigeria. West Afr Journal Med. 2001 Apr-Jun;20(2):146-51.
- Wahane SM, Pandya B, Narang R. Spectrum of Benign Breast Disease at Rural Teaching Hospital of Central India: A Cross Sectional Study. Cibtech Journal of Surgery. 2015; 4(2): 12-16.
- Das N, Debbarma A, Debbarma G. A clinicopathological study of benign breast diseases in rural population. International Journal Res Med Sci. 2014; 2(3): 1067-1069
- Vakil M, Ali A, Mustanser T, Rasool S. Magnitude of breast diseases in Ojha histopathology department. Medical Channel. 2013; 19(2): 44-49.
- Bagale P, Dravid NV, Bagale S, Ahire N. Clinicopathological Study of Benign Breast Diseases. International Journal Health Sci Res. 2013; 3(2): 47-54.
- Sangma MB, Panda K, Dasiah S. A Clinico-Pathological Study on Benign Breast Diseases. Journal of Clinical and Diagnostic Research. 2013; 7(3): 503-506
- Rasheed A, Sharma S, Rasool M, Bashir S, Hafiz A, Bashir N. A Three Year Study of Breast Lesions in Women aged 15-70 years in a Tertiary Care Hospital. Scholars Journal Applied Medical Science, 2014; 2(1B):166-168
- Shirley SE, Mitchell DIG, Soares DP, James M, Escoffery CT, Rhoden AM. Clinicopathologic Features of Breast Disease in Jamaica: Findings of the Jamaican Breast Disease Study, 2000–2002. West Indian Med Journal, 2008; 57(2): 90-94.
- Shrivastava JP, Shrivastava A. Fine Needle Aspiration Cytology of Breast Lumps with Clinical and Histopathological Correlation: A 2 Year Study in Gwalior, India. Journal of Evolution

- of Medical and Dental Sciences, 2015; 4(56): 9729-9734.
17. Echejoh G, Dzuachi D, Jenrola A. Histopathologic analysis of benign breast diseases in Makurdi, North Central Nigeria. *International Journal of Medicine and Medical Sciences*. 2011; 3(5): 125-128.
 18. Uwaezuoke SC, Udoye EP. Benign breast lesions in Bayelsa State, Niger Delta Nigeria: A 5 year Multicentre Histopathological audit. *Pan African Medical Journal*. 2014; 19:394-398.
 19. El-Tamer MB, Song M, Wait RB. Breast masses in African American teenage girls. *Journal Pediatr Surg*. 199; 34(9):1401-4
 20. Nggada HA, Gali BM, Bakari AA, Yawe-Terna EH, Tahir MB, Apari E, Dahiru AB, Yawe KDT. The spectrum of female breast diseases among Nigerian population in Sahel climatic zone. *Journal Medical Science*. 2011; 2(10): 1157-1161.
 21. Adeniji KA, Adelusola KA, Odesanmi WO. Benign disease of the breast in Ile –Ife: a 10 year experience and Literature review. *Central African Journal of Medicine*, 1997; 43(5):140-143.
 22. Akhator A. Benign Breast Masses in Nigeria. *Nigerian Journal of Surgical Sciences*. 2007; 17: 105 - 8.
 23. Fwu PT, Chen J, Li Y, Chan S, Su M. Quantification of Regional Breast Density in Four Quadrants using 3D MRI- A Pilot Study. *Translational Oncology*. 2015; 8(4): 250-257.
 24. Dener C, Inan A. Breast abscesses in lactating women. *World Journal Surg*. 2003 Feb;27(2):130-3.