

The Role of Transvesical Adenectomy in the Era of Endourology (TURP, PVP, Holmium Laser) at the Mohammed V Military Training Hospital, Rabat, Urology Department: A Case Report and Literature Review

Dr. Conde Fadama^{1,2}, Dr. Belhaj Karim^{1,3*}, Pr Louardi Nabil^{1,2}, Pr El Bahri Abdessamad^{1,2}, Pr Alami Mohamed^{1,2}, Pr Ameer Ahmed^{1,2}

¹Mohammed V Military Training Hospital, Av. Abderrahim Bouabid, Rabat, Morocco

²Faculty of Medicine and Pharmacy, Mohammed V University, Rabat, Morocco

³Health of Health Sciences, Mohammed VI University, Lot 660, Ben Guerir 43150, Morocco

DOI: [10.36347/sasjs.2023.v09i11.010](https://doi.org/10.36347/sasjs.2023.v09i11.010)

| Received: 22.09.2023 | Accepted: 31.10.2023 | Published: 19.11.2023

*Corresponding author: Dr. Belhaj Karim

Mohammed V Military Training Hospital, Av. Abderrahim Bouabid, Rabat, Morocco

Abstract

Case Report

Transvesical adenectomy according to Fuller-Freyer- Hryntschak, although challenged by other endoscopic techniques, is one of the surgical options validated and recommended by the majority of urology societies for managing and operating on large prostate adenomas with volumes greater than 100 cc, such as the one described in this case report with an ultrasound-measured prostate volume of 238g. Long-term results are excellent, but it is important to note marked perioperative morbidity, including bleeding, and a significant complication that should be explained to the patient prior to the procedure: retrograde ejaculation. We present a case of a 60-year-old patient with a prostate volume of 238g with failure of dual alpha-blocker and 5-alpha reductase therapy, who underwent urodynamic assessment revealing a Qmax of 9ml and a post-void residual volume of 180ml, acute urinary retention requiring Foley catheterization with unsuccessful trial of voiding after Foley catheter removal. A comprehensive report of his evaluation is provided, including clinical history, physical examination, and para-clinical findings. We discuss the operative indication and review the relevant literature.

Keywords: Transvesical Adenectomy, Hryntschak, Retzius space, retrograde ejaculation.

Copyright © 2023 The Author(s): This is an open-access article distributed under the terms of the Creative Commons Attribution 4.0 International License (CC BY-NC 4.0) which permits unrestricted use, distribution, and reproduction in any medium for non-commercial use provided the original author and source are credited.

INTRODUCTION

Benign prostatic hyperplasia (BPH), also known as prostate adenoma, is a benign proliferation of prostatic epithelial and stromal tissue, resulting in an increase in volume without clinical or histopathological signs of malignancy, causing varying degrees of urinary obstruction. Its management ranges from medical treatment to surgery. It primarily affects aging men.

We present a case report of the management of a patient with transvesical adenectomy in the era of laser and transvesical prostate resections, with a frequency of 0.01% at the HMIMV Rabat.

CASE REPORT

Mr. H.M., a 60-year-old male, had a history of hypertension treated with amlodipine 10mg and type II diabetes managed with oral antidiabetic drugs. He had been under treatment for BPH with Tamsulosine 0.4mg an alpha-blocker and Dutasteride 0.5mg 5-alpha

reductase inhibitor for over a year, with no improvement. He presented with lower urinary tract symptoms, including dysuria and a slow start to urination, complicated by acute urinary retention requiring catheterization, which failed to remove the catheter during his hospitalization.

- IPSS score before acute urinary retention was calculated, classifying the patient as severe with a score of 25 out of 35 under combination therapy, consisting of an alpha-blocker (Alfuzocin 10mg) and the 5-alpha reductase inhibitor, Dutasteride 0.5g at a daily dose before bedtime.
- Quality of life evaluation related to urinary symptoms before acute urinary retention: The patient reported a significant negative impact on his quality of life.
- Physical examination revealed a markedly enlarged prostate on rectal examination with an estimated volume exceeding 80g.
- A uroflowmetry test before acute urinary retention showed a Qmax of 9ml/s, a voiding time of one

Citation: Conde Fadama, Belhaj Karim, Louardi Nabil, El Bahri Abdessamad, Alami Mohamed, Ameer Ahmed. The Role of Transvesical Adenectomy in the Era of Endourology (TURP, PVP, Holmium Laser) at the Mohammed V Military Training Hospital, Rabat, Urology Department: A Case Report and Literature Review. SAS J Surg, 2023 Nov 9(11): 919-923.

minute, a voided volume of 200cc, and a post void residual volume of 180cc.

- A KUB and prostate ultrasound before acute urinary retention revealed a prostate volume measured at 238g and a post-void residual volume of 190cc.
- Laboratory results showed hemoglobin level of 14g/dl, white blood cells at 1300/mm³ and platelets at 401,000/mm³.
- Serum electrolytes: Sodium 141mmol/L, Potassium 3.6mmol/L, Alkaline reserve 26mmol/L, Urea 0.18g/L, Creatinine 10m/L, glomerular filtration rate (GFR) 76ml/min/m²
- Urinalysis was normal while urine culture was sterile.
- Blood type: O+
- Total PSA: 6.25ng/L
- PSA Ratio: 35%
- PSA density: 0.026

Summary: This is a 60-year-old male, known case of hypertension and Type 2 diabetes mellitus, that has been treated for BPH with poor response to combination therapy (Alfuzocin 10mg and Dutasteride 0.5mg) for 12 months. Urodynamic assessment revealed a significantly reduced Qmax (9ml/s), a prostate volume of 238g, and a post-void residual volume of 180cc. Thus, a suprapubic adenomectomy was proposed and performed on August 14, 2023, following the Hryntschak technique.

PATIENT PREPARATION

A pre-anaesthetic consultation was conducted, and spinal anaesthesia was indicated.

The surgical approach and indication for suprapubic adenomectomy according to Hryntschak.

A rectal enema was performed to facilitate rectal examination during adenomectomy. The indication for surgery was based on a prostate volume of 238g, poor response to therapy, a Qmax of 9, PVR of 182, and a severe IPSS score of 25/35.

PATIENT SETUP AND OPERATING ROOM ARRANGEMENT:

The patient is placed in a lithotomy position, and an initial cystoscopy is performed to assess the prostate's volume and to explore the bladder, with the aim of identifying any potential bladder tumor. Afterward, the patient is put in dorsal decubitus position to enable catheterization, with his legs slightly apart, allowing for the digital rectal examination (DRE).

The surgical field is prepared by disinfecting the surgical field with povidone iodine while including the rectum within the operative field to facilitate a possible intraoperative rectal examination and to provide counter-pressure during the prostate enucleation.

REQUIRED EQUIPMENT:

1. Suction.
2. Monopolar cautery pen.
3. Hryntschak retractor.
4. Museux forceps.
5. 2.0 absorbable ligature thread in a monofilament coil.

MAIN OPERATIVE STEPS:

- a) A suprapubic skin incision was made using a scalpel. The aponeurosis of the rectus abdominis muscle was opened, followed by the separation of the rectus muscle.
- b) The Retzius space was opened, the anterior bladder wall was cleared of fat, and the anterior wall was exposed.

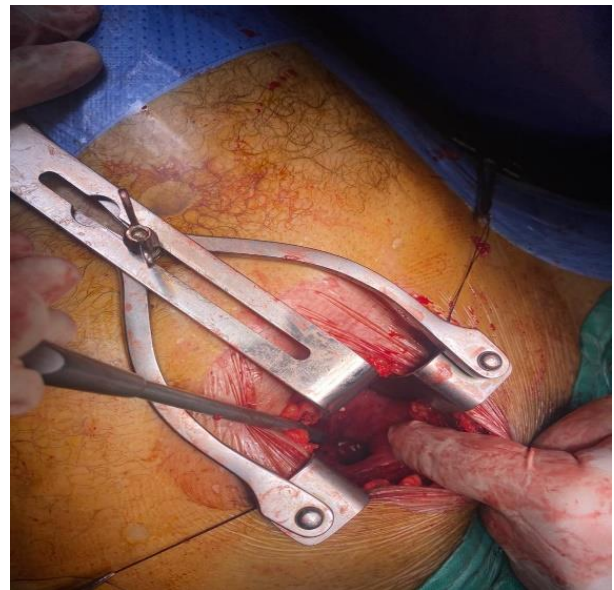


Figure 1: Bladder approach, exposure of the Retzius space, bladder opening, placement of the Hryntschak retractor

- c) The bladder was filled with 300 cc of sterile normal saline using the placed Foley catheter and immediately clamped for better visualization, followed by the placement of two stay Vicryl sutures to mark the incision site.
- d) A vertical, midline incision was made on the bladder's median face, cutting through the adventitia, detrusor muscle, and bladder mucosa. The bladder was then opened, and the saline was aspirated.
- e) The Hryntschak retractor was placed, ureteric orifices were identified, and the median lobe was separated.
- f) A circumferential cervical incision was started then a digital enucleation was performed from the anterior commissure, followed by urethral section and removal of the operative specimen.

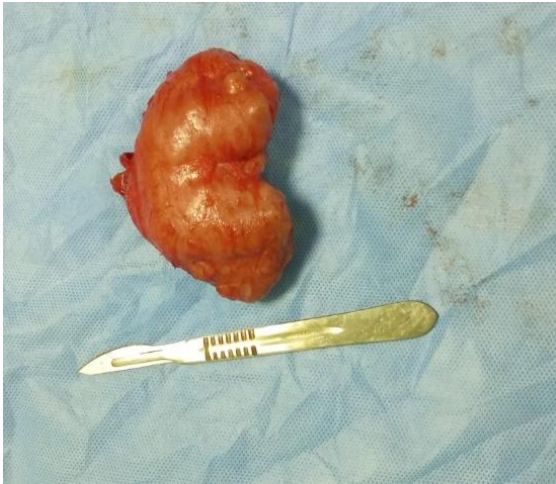

Figure 2: Posterior view of the enucleated specimen

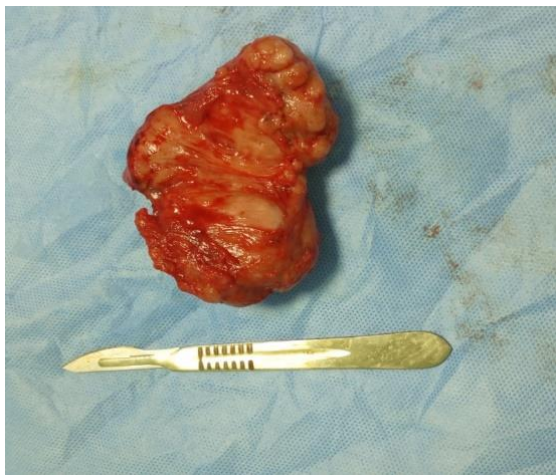


Figure 3: Internal View of the median lobe, lateral lobes and the verumontanum

g) Haemostasis was achieved with stitches, targeting the major arteries at 5 o'clock and 7 o'clock. As the stitches were placed, the prostatic tissue was removed.

Hemostasis of the prostatic enucleation bed was achieved by targeting the main arteries located at 5 o'clock and 7 o'clock, and to a lesser extent at 2 o'clock and 10 o'clock. A thread with a 5/8 circle needle is ideal for suturing the bladder mucosa and the entire thickness of the remaining prostate up to the capsule. "X" stitches are made in these different clock positions until bleeding diminishes. As the stitches are placed, the prostatic tissue is removed, which achieves hemostasis through compression.

h) Trigonization may be performed if the bladder mucosa allows, two midline sutures can be added to bring the bladder mucosa into the prostatic bed on the midline. Caution must be exercised during the placement of these sutures to avoid injuring the ureteral meatus

DISCUSSION

Review of MacNeal's zonal anatomy [1]:

Since MacNeal's work in 1981, five zones organized around the prostatic urethra have been identified [1]. The peripheral zone covering 60-70% of

the prostate volume, which is the most common site for prostate cancer [1]. The central zone accounting for 15-20% of prostate volume and is responsible for a small percentage of prostate cancers [1]. The transitional zone located on both sides of the prostatic urethra and is associated with benign nodular prostatic hyperplasia [1]. The peri-urethral glandular zone representing less than 1% of prostate gland mass [1]. The anterior fibromuscular zone: Covering one-third of prostate volume and is generally free from pathological processes [1].

Epidemiology:

Benign prostatic hyperplasia (BPH) is a condition commonly affecting aging men, representing the leading cause of urology consultations. About 80% of men will develop BPH, with the highest prevalence occurring between 60-70 years of age, affecting 40% of those aged 60 [1]. Surgical treatment in the form of adenomectomy represents only 0.1% of the surgeries performed in our department, which is comparable to many Western urology departments. Suprapubic adenomectomy is rarely practiced in our facility for the management of complicated BPH cases. Over one year, only three suprapubic adenomectomy were performed, which aligns with the rates in Western countries [2]. In France, transurethral resection reaches 81%, 97% in the USA, 70% in Japan, and 79.89% in Guinea's Ignace Deen University Hospital between 2005-2017, according to Dr. Diallo's series [2, 3]. In these Western countries, open surgery comprises only 5-30% of cases, thanks to advances in materials and techniques. The patient's age, 60 years, is consistent with the literature, with an average age of 67 in Dr. Diallo's series, ranging from 50 to 79 years (3). Kambou and Diallo reported an average age of 68 years [3, 8]. BPH is primarily a condition of men aged 50 and older.

Diagnosis:

In the presence of obstructive or irritative symptoms in an aging man, the initial diagnostic evaluation is dominated by the digital rectal examination (DRE) [4, 5, 6, 8]. This examination assesses the anal sphincter, rectal ampulla, prostate volume and consistency, and the presence of prostate cancer. Our patient had a prostate volume exceeding 80 grams upon DRE. Our patient's PSA level was 6.26 ng/ml, with a low PSA density. Dr. Diallo's series included parameters such as DRE, PSA, PSA ratio, and PSA density, with an average PSA of 2.1 ng/ml and extremes of 0.2 and 6 ng/ml [3]. Botcho reported an average PSA level of 9.7 ng/ml [5].

- **Urinalysis:** An essential test to exclude infection, and in our patient, it was sterile. However, Dr. Diallo's series reported a 68.12% rate of *E. coli*-positive results [4]. Massandé in Gabon reported a 71.4% positivity to *E. coli*.
- **KUB and prostate ultrasonography:** An imperative step in diagnosing BPH [7]. Our patient underwent KUB and Prostatic

ultrasonography, revealing a prostate volume of 238 grams, a post-void residual volume of 92 cc, and signs of bladder decompensation. Dr. Diallo's series included ultrasound findings in 100% of his patients, with an average prostate volume of 98 grams [2]. Fall in Dakar reported a similar volume of 95 cc [6], while Botcho in Togo found an average volume of 104.7 cc [5].

Indications for Transvesical Adenomectomy:

In our case surgical intervention was indicated due to failure of medical therapy, a prostate volume of 238 grams, a Qmax of 9 ml/s (normal being >15 ml/s), bladder decompensation, and a history of acute urinary retention dating back six months. Dr. Bah at the Ignace Deen University Hospital reported complications, including acute urinary retention with high residual urine (83.33%), while Botcho reported acute urinary retention in 14.48% of cases. Our patient underwent spinal anesthesia, which was consistent with Dr. Bah Ibrahima's series, where 78% of patients received spinal anesthesia due to significant comorbidities [2]. Our patient exhibited a well-developed bladder wall with mucosal trabeculation due to bladder decompensation, with Dr. Diallo reporting a 78.67% thickening rate [2, 4].

The enucleation procedure was preceded by a cervical incision with ureteral meatus identification. Hemostasis was ensured by sutures as recommended in the literature at 5 and 7 o'clock positions with Vicryl 2/0, followed by a Trigonization. A three-way silicone catheter with a 30 cc balloon was inserted. Irrigation was performed for three days, with a blood loss of 50 cc. The resected specimen was sent for pathology, confirming benign adenomatous hyperplasia without signs of malignancy. The hospital stay lasted four days, with catheter removal on day five and suture removal on day ten. The patient was followed up at the outpatients' department on day 15 with improved symptoms and improved urinary symptoms.

Risks and Complications:

Every surgical procedure carries a certain percentage of complications and risks, including vital risks related not only to the underlying disease but also to individual variability, which can be unpredictable. Some of these complications are exceptionally rare and may not have a cure. During the procedure, the surgeon may encounter unexpected events or findings, often necessitating additional procedures or even discontinuation of the surgery. Some complications are related to the patient's general health (comorbidities) or anaesthesia and should be thoroughly explained to the patients, including the risk of pulmonary embolism and thrombophlebitis. Various complications can arise from the surgical procedure, falling into three categories:

Common Complications:

These may include mild bleeding that can be resolved by removing clots, typically managed through

irrigation. Urinary tract infections and epididymitis may also occur.

Occasional Complications:

In some cases, patients may experience complications like hematoma or infection at the incision site or scar, infection of the pubic bone, or injuries to adjacent organs, including the intestine or pelvic vessels. There is also a risk of electrical accidents resulting in burns.

Rare and Exceptional Complications:

These complications are less frequent and may include urine leakage through the incision, urethral stenosis, fibrosis of the vesical neck, and incontinence that necessitates the use of pads. Erectile dysfunction may also occur, although its onset is rare and typically occurs later, with the timing influenced by age and preoperative conditions.

These complications should be considered within the context of the surgical procedure, and patients should be informed of these potential risks during the preoperative consultation.

CONCLUSION

Benign prostatic hyperplasia is a condition commonly affecting aging men. Despite advances in the treatment of BPH, including transurethral resection of the prostate, Transurethral incision of the prostate (HoLEP), and transvesical adenomectomy via techniques such as Hryntschak suprapubic or Millin retropubic prostatectomy, these procedures still have their place and yield good results, despite their low rates of implementation. Haemostatic control and the occurrence of retrograde ejaculation remain significant challenges.

Conflict of Interest: All authors have read and accepted this manuscript; there are no conflicts of interest.

REFERENCES

1. Common Residency Course. (August 2020). Topic No. 73: Prostate Tumors. Epidemiology, Diagnosis, Therapeutic Guidelines; Validation No. 0873202062.
2. Bah, I., Bah, M. B., Barry, M., Diallo, A., Kanté, D., Diallo, M. T., & Cissé, D. Transvesical adenomectomy: Results and complications at the Urology Andrology Department of Ignace Deen Hospital, Conakry University Hospital.
3. Diallo, M. (2018). Prostate adenoma in the general surgery unit of the Bamako District VI reference health center: Clinical, paraclinical, and therapeutic aspects. *Health Sci Dis*, 21.
4. Diallo, M. P. (2001). Early complications of transvesical prostatic adenomectomy at the Conakry Urology Service: A study of 96 cases. *Ann Urol*, 35, 120-124.

5. Boctcho, G. (2018). Morbidity and mortality after transvesical prostatic adenomectomy at Kara University Hospital, Togo. *Afr J Urol*, 24.
6. Fall, P. A. (2002). Mortality and early morbidity after transvesical adenomectomy. *Afr J Urol*, 8, 20-23.
7. Massandé Mouyendi, J. M., Mougougou, A., Ndong Ngou Milama, S., & Adandé Menest, E. (2017). Mortality and morbidity after transvesical prostatic adenomectomy at Libreville University Hospital: A study of 56 cases. *Rev Afr Urol Androl*, 1.
8. Kabou, T. (2006). Surgical treatment of benign prostatic hypertrophy at Sanou Souro University Hospital, Bobo-Dioulasso, Burkina Faso: Short and medium-term results. *Med Afr Noire*, 53(1), 515-521.