

## Imaging Findings of Esthesioneuroblastoma

Dr. Mekala Uday<sup>1\*</sup>, Dr. Muralee Naik<sup>1</sup>, Dr. Pooja<sup>1</sup>, Dr. Rasi Priya<sup>1</sup>, Dr. Pankaj Sharma<sup>1</sup>

<sup>1</sup>All India Institute of Medical Sciences, Rishikesh, Uttarakhand, India

DOI: [10.36347/sjmcr.2023.v11i11.015](https://doi.org/10.36347/sjmcr.2023.v11i11.015)

Received: 12.10.2023 | Accepted: 17.11.2023 | Published: 19.11.2023

\*Corresponding author: Dr. Mekala Uday

All India Institute of Medical Sciences, Rishikesh, Uttarakhand, India

### Clinical History

Copyright © 2023 The Author(s): This is an open-access article distributed under the terms of the Creative Commons Attribution 4.0 International License (CC BY-NC 4.0) which permits unrestricted use, distribution, and reproduction in any medium for non-commercial use provided the original author and source are credited.

## CLINICAL HISTORY

A 28 year female presented to hospital with chief complaints of nasal stuffiness, epistaxis and headache since 5 months.

### Imaging Findings

Patient subsequently underwent CEMRI BRAIN with PNS to look for the underlying etiology.

MR Imaging revealed an ill-defined T2 iso to hyperintense lobulated solid cystic mass lesion extending from posterior nasal cavity into anterior cranial fossa through bilateral posterior ethmoidal air cells and sphenoid sinus to involve bilateral frontal lobes with significant perilesional edema. On T1 images, it showed iso to hypointense signal. DWI showed mild diffusion restriction within the solid component of the mass. On postcontrast images, the mass showed heterogenous enhancement.

Imaging findings were suggestive of esthesioneuroblastoma with intracranial extension. Patient underwent surgical resection of the entire tumour. Histopathological examination from the post operative specimen confirmed it as esthesioneuroblastoma (olfactory neuroblastoma).

## DISCUSSION

- A. Olfactory neuroblastoma or esthesioneuroblastoma is a rare malignant neoplasm arising from the superior nasal cavity's olfactory epithelium with a incidence of ~0.4 per million[1, 2].
- B. Patients usually present with nasal obstruction, epistaxis. Head ache, hyposmia or anosmia are other associated symptoms[3, 4].As the esthesioneuroblastoma symptoms are non-specific in early stages, usually there is delay in

diagnosis with a median interval of 6 to 12 months between the onset of symptoms and diagnosis [5–8]. Patients survival depends upon the stage at the initial presentation, so accurate staging must be done at initial presentation. To know the extent of the disease, appropriate imaging evaluation includes both a CT and an MRI [9].

- C. CT helps in assessing bony destruction, in cases of esthesioneuroblastoma erosion of cribriform plate, lamina papyracea and fovea ethmoidalis are commonly noted. MRI is better at evaluating extent of tumour into surrounding soft tissues and intracranial extension, it also helps in differentiating tumour from mucus [10, 11]. CT on bone window shows expansile bony remodelling with bone destruction usually of the cribriform plate. Esthesioneuroblastoma is hypo to isointense on T1WI and iso to hyperintense on T2WI in relative to grey matter of brain. Areas of cystic degeneration and haemorrhage are common. The presence of intracranial cysts strongly suggests esthesioneuroblastoma but it is not diagnostic. On post contrast images, it shows avid and homogenous enhancement. Tumour may show orbital and intracranial extension [12-14]. Neck metastasis are found in nearly 5 % of esthesioneuroblastoma, so imaging of neck must be included in work up of these patients [9]. The modified kadish staging is done to predict the survival of patients with esthesioneuroblastoma. According to modified kadish staging, four stages were determined. In stage A, tumour is limited to nasal cavity, In stage B tumour is limited to nasal cavity and paranasal sinuses, In stage C tumour, tumour extends beyond nose and PNS to involve cribriform plate, base of skull, orbit or

intracranial cavity. Tumour with metastasis to cervical nodes is categorized under stage D [2-16].

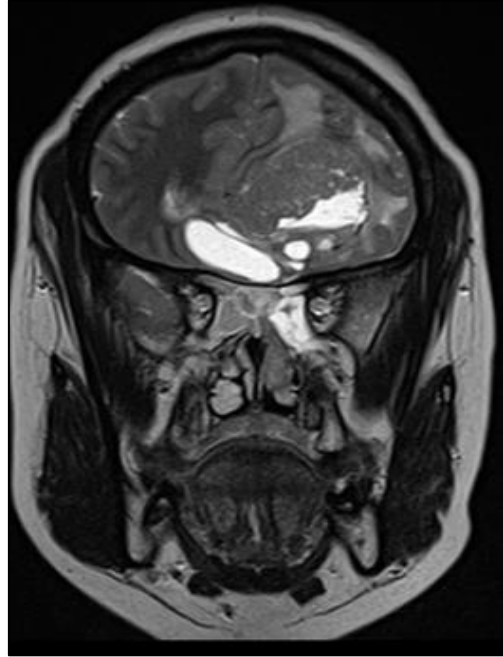Treatment of esthesioneuroblastoma depends upon the tumour extension and histological grade. Multimodality treatment offers the best cure in most of the cases. Surgery followed by radiation therapy is the best therapy as reported in literature [17, 18]. The prognosis of esthesioneuroblastoma depends on stage and histological grade of tumour. 5 year survival rate for low grade tumours is around 80% and for high grade tumours is nearly 25% [18].

**Final Diagnosis**

**Esthesioneuroblastoma**

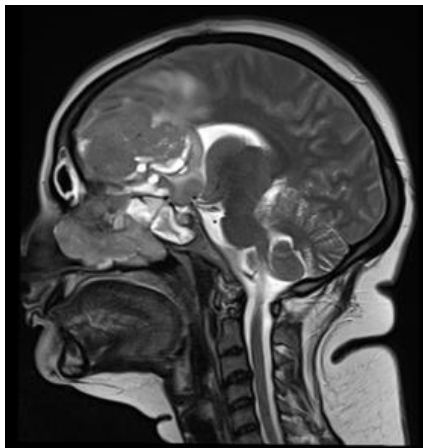**Differential Diagnosis List**

1. Sinonasal squamous cell carcinoma: epicentered in maxillary antrum and does not show intense enhancement.
2. Sinonasal adenocarcinoma: History of wood dust exposure. No T2 hyperintense cysts within the mass.
3. Sinonasal melanoma: Lower nasal cavity is the most common site. T1 hyperintense and t2 hypointense mass.
4. Sinonasal non Hodgkin lymphoma: Hyperdense on NCCT images, shows diffusion restriction on DWI. Rarely extends into anterior cranial fossa.

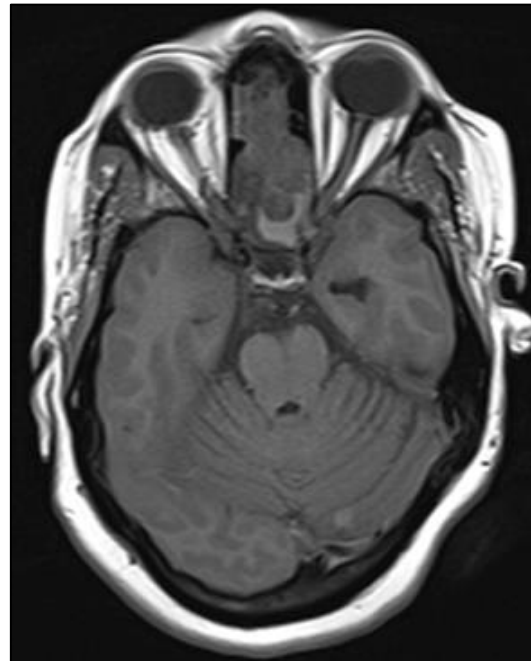


**Fig 1b: Coronal T2 weighted image- An ill-defined iso to hyperintense lobulated solid cystic mass lesion extending from posterior nasal cavity into anterior cranial fossa through bilateral posterior ethmoidal air cells and sphenoid sinus to involve bilateral frontal lobes with significant perilesional edema.**

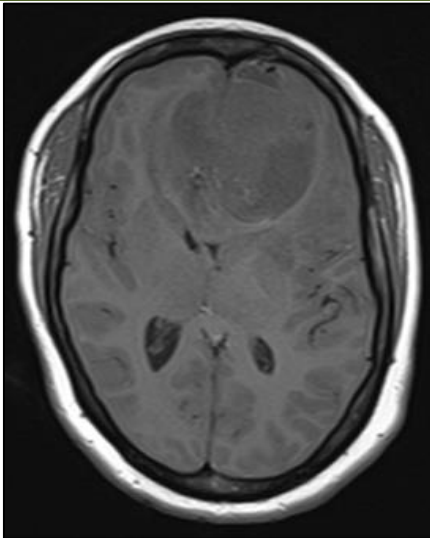
**FIGURES**



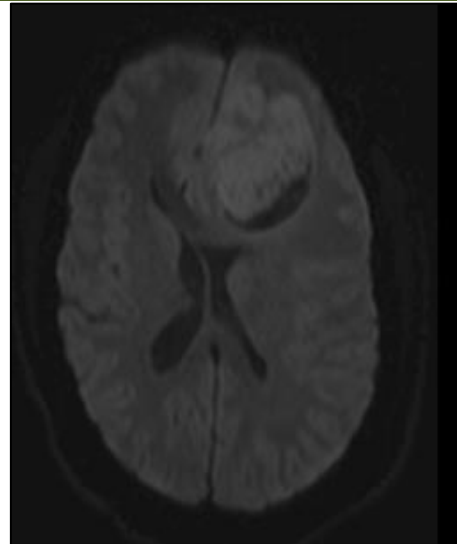
**Fig 1a: Axial T2 weighted image – An ill-defined iso to hyperintense lobulated solid cystic mass lesion extending from posterior nasal cavity into anterior cranial fossa through bilateral posterior ethmoidal air cells and sphenoid sinus to involve bilateral frontal lobes with significant perilesional edema.**



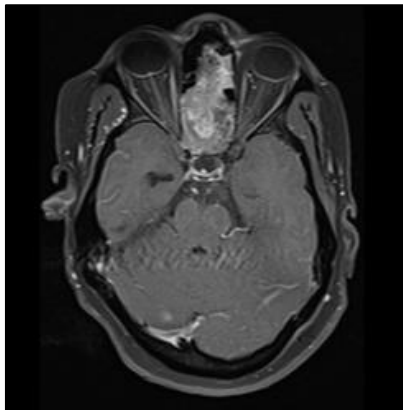
**Fig 2a: Precontrast axial T1 image - Iso to hypointense mass with ill defined margins in posterior ethmoidal air cells .**



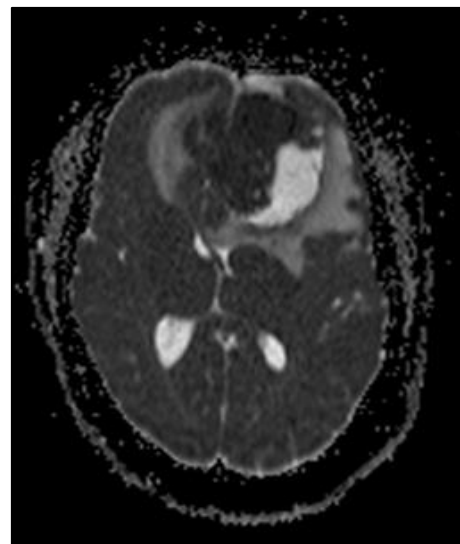
**Fig 2b: Precontrast axial T1 image - Iso to hypointense mass with ill defined margins extending from posterior ethmoidal cells into bilateral frontal lobes.**



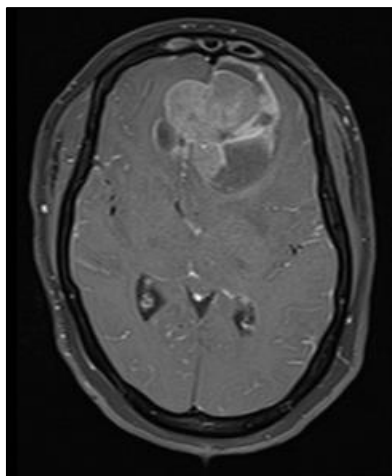
**Fig 3a: DWI - Hyperintense signal within the solid component of the mass in bilateral frontal lobes.**



**Fig 2c: Postcontrast axial T1 image - Heterogenous enhancement of the solid component of the mass within the posterior ethmoid air cells.**



**Figure 3b: ADC -Low signal within the solid component of the mass in bilateral frontal lobes.**



**Fig 2d: Postcontrast axial T1 image - Heterogenous enhancement of solid component of the mass within the bilateral frontal lobes**

## REFERENCES

1. Broich, G., Pagliari, A., & Ottaviani, F. (1997). Esthesioneuroblastoma: a general review of the cases published since the discovery of the tumour in 1924. *Anticancer Res*, 17(4A), 2683–706.
2. Jethanamest, D., Morris, L. G., Sikora, A. G., & Kutler, D. I. (2007). Esthesioneuroblastoma: a population-based analysis of survival and prognostic factors. *Archives of Otolaryngology–Head & Neck Surgery*, 133(3), 276–280.
3. Lund, V. J., & Milroy, C. (1993). Olfactory neuroblastoma: clinical and pathological aspects. *Rhinology*, 31(1), 1–6.
4. Ward, P. D., Heth, J. A., Thompson, B. G., & Marentette, L. J. (2009). Esthesioneuroblastoma: Results and Outcomes of a Single Institution’s Experience. *Skull Base*, 19(2), 133–40.

5. Bak, M., & Wein, R. O. (2012). Esthesioneuroblastoma: a contemporary review of diagnosis and management. *Hematology/Oncology Clinics*, 26(6), 1185-1207. [https://www.google.com/search?client=safari&rls=en&q=BakM%2CWein+RO.+Esthesioneuroblastoma%3A+a+contemporary+review+of+diagno+sis+and+management.+Hematol+Oncol+Clin+North+Am.+2012%3B26\(06\)%3A1185%E2%80%931207&ie=UTF-8&oe=UTF-8#cobssid=s](https://www.google.com/search?client=safari&rls=en&q=BakM%2CWein+RO.+Esthesioneuroblastoma%3A+a+contemporary+review+of+diagno+sis+and+management.+Hematol+Oncol+Clin+North+Am.+2012%3B26(06)%3A1185%E2%80%931207&ie=UTF-8&oe=UTF-8#cobssid=s).
6. Dulguerov, P., & Calcaterra, T. (1992). Esthesioneuroblastoma: the UCLA experience 1970–1990. *The Laryngoscope*, 102(8), 843-849. [https://www.google.com/search?client=safari&rls=en&q=Dulguerov+P%2C+Calcaterra+T.+Esthesioneuroblastoma%3A+the+UCLA+experience+1970+1990.+Laryngoscope.+1992%3B102\(08\)%3A843%E2%80%93849&ie=UTF-8&oe=UTF-8](https://www.google.com/search?client=safari&rls=en&q=Dulguerov+P%2C+Calcaterra+T.+Esthesioneuroblastoma%3A+the+UCLA+experience+1970+1990.+Laryngoscope.+1992%3B102(08)%3A843%E2%80%93849&ie=UTF-8&oe=UTF-8).
7. Olfactory neuroblastoma: a review and update - PubMed [Internet]. [cited 2023 Jul 25]. Available from: <https://pubmed.ncbi.nlm.nih.gov/19700942/>
8. Su, S. Y., Bell, D., & Hanna, E. Y. (2014). Esthesioneuroblastoma, neuroendocrine carcinoma, and sinonasal undifferentiated carcinoma: differentiation in diagnosis and treatment. *International Archives of Otorhinolaryngology*, 18, 149-156. <https://pubmed.ncbi.nlm.nih.gov/25992139/>
9. Bradley, P. J., Jones, N. S., & Robertson, I. (2003). Diagnosis and management of esthesioneuroblastoma. *Current opinion in otolaryngology & head and neck surgery*, 11(2), 112-118.
10. Imaging of the olfactory system - PubMed [Internet]. [cited 2023 Jul 25]. Available from: <https://pubmed.ncbi.nlm.nih.gov/11770926/>
11. Pickuth, D., Öbrunner, S. Y. K., & Spielmann, R. P. (1999). Computed tomography and magnetic resonance imaging features of olfactory neuroblastoma: an analysis of 22 cases. *Clinical Otolaryngology & Allied Sciences*, 24(5), 457-461.
12. Som, P. M., Lidov, M., Brandwein, M., Catalano, P., & Biller, H. F. (1994). Sinonasal esthesioneuroblastoma with intracranial extension: marginal tumor cysts as a diagnostic MR finding. *American journal of neuroradiology*, 15(7), 1259-1262.
13. Sievers, K. W., Greess, H., Baum, U., Dobritz, M., & Lenz, M. (2000). Paranasal sinuses and nasopharynx CT and MRI. *European journal of radiology*, 33(3), 185-202.
14. Dulguerov, P., & Allal, A. S. (2006). Nasal and paranasal sinus carcinoma: how can we continue to make progress?. *Current opinion in otolaryngology & head and neck surgery*, 14(2), 67-72.
15. Koka, V. N., & Julieron, M. (1998). J Bourhis J, Janot F, Le Ridant AM, Marandas P, Luboinski B, Schwaab G. Aesthesioneuroblastoma. *J Laryngol Otol*, 112(7), 628-33.
16. Esthesioneuroblastoma: prognosis and management - PubMed [Internet]. [cited 2023 Jul 27]. Available from: <https://pubmed.ncbi.nlm.nih.gov/8492845/>
17. Ow, T. J., Hanna, E. Y., Roberts, D. B., Levine, N. B., El-Naggar, A. K., Rosenthal, D. I., ... & Kupferman, M. E. (2014). Optimization of long-term outcomes for patients with esthesioneuroblastoma. *Head & neck*, 36(4), 524-530.
18. Ow, T. J., Bell, D., Kupferman, M. E., DeMonte, F., & Hanna, E. Y. (2013). Esthesioneuroblastoma. *Neurosurgery Clinics*, 24(1), 51-65.