

## An Abdominal Textiloma Simulating an Intestinal Tumour: A Case Report

Oubihi Ahmed<sup>1\*</sup>, Tsimba Tsonda Appolinaire<sup>1</sup>

<sup>1</sup>Department of Visceral Surgery, Hospital Center Sud-Essonne, Etampes, France

DOI: [10.36347/sasjs.2023.v09i12.001](https://doi.org/10.36347/sasjs.2023.v09i12.001)

| Received: 24.10.2023 | Accepted: 29.11.2023 | Published: 05.12.2023

\*Corresponding author: Oubihi Ahmed

Department of Visceral Surgery, Hospital Center Sud-Essonne, Etampes, France

### Abstract

### Case Report

The textiloma, being an inflammatory granuloma that is secondary to a foreign body left involuntarily at the level of the operative site with an unpredictable evolution, constitutes a relatively rare postoperative complication, with a misleading clinical-radiological presentation, as well as potentially serious complications and forensic proceedings involving the responsibility of the surgeon. Although surgery is the means of choice to confirm the diagnosis and to treat the disease, taking serious preventive measures remains the only solution to avoid this type of incident. We report the case of an intestinal tumor syndrome revealing an abdominal textiloma.

**Keywords:** Textiloma; Gossypiboma; Tumor syndrome; Prevention.

Copyright © 2023 The Author(s): This is an open-access article distributed under the terms of the Creative Commons Attribution 4.0 International License (CC BY-NC 4.0) which permits unrestricted use, distribution, and reproduction in any medium for non-commercial use provided the original author and source are credited.

## INTRODUCTION

Textiloma is among the relatively most rare unwanted events of all surgeons; Also called Gossypiboma (derived from 'gossypium' meaning: 'cotton' in Latin and 'boma' meaning 'hiding place' in Swahili), which is defined as an inflammatory granuloma centered by textile fibers forgotten at the level of an operative site [1- 9], can lead to serious complications, as well as forensic proceedings engaging the responsibility of the surgeon. In this article we will discuss the case of an abdominal textiloma initially mistaken as an intestinal tumour.

## CASE REPORT

We report the case of a 64-year-old female patient, with a history of a left mastectomy for a left breast tumor 12 years ago, a total thyroidectomy for Multiheteronodular goiter 10 years ago, put on life-long replacement hormone therapy, and a bilateral adnexectomy 14 months ago for a large left ovarian tumor by laparoscopy then converted to laparotomy (given the size of the tumor) with the notion of correct textile counting, and whose anatomopathological study of the operating specimen returned in favour of a serous cystadenoma. The postoperative consequences was simple.

The history of the disease goes back to six months by the installation of an atypical abdominal pain with epigastric starting points, resisting to symptomatic treatment, given the installation of intermittent transit

disorders and a weight loss estimated at 7 kg in two months, her gastroenterologist performed an abdominal ultrasound, a FOGD and a total colonoscopy, all of which returned without anomaly; in the meantime, the patient underwent a pelvic MRI as part of the surveillance set up by her gynaecological surgeon, the sections of the MRI passing through the abdomen revealed a tumour-like mass, probably hail-shaped, on the left flank, which is difficult to characterize requiring CT examination (Figure 1). The thoracic-abdominal-pelvic CT scan performed later showed the presence of well-limited a cystic mass at the level of the left flank, measuring 80\*45 mm, containing a tissue contingent with a metallic density giving rise of suspecting a textiloma without any other scan abnormalities (Figure 2).

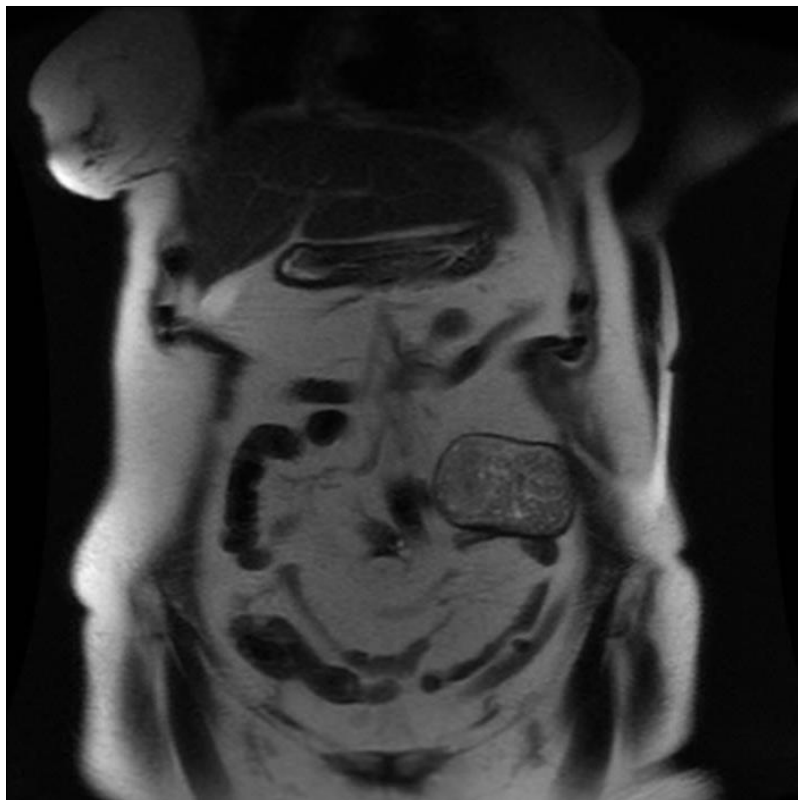
In fact, the patient was referred to our department where the clinical examination showed a good general condition, some abdominal scars at the sites of insertion of the laparoscopic trocars, as well as another scar of Pfannenstiel laparotomy, and a palpable mass on the left flank, slightly sensitive making about 10 cm long axis.

Surgical exploration through a midline straddle laparotomy on the navel revealed omental-parietal and omental-grelic adhesions, which were freed, as well as a mass of about 90 mm in diameter on the left flank. of hard consistency, adherent to the anterior abdominal wall, to the greater omentum and to a few ileal loops, the release of which was laborious at the cost of a few

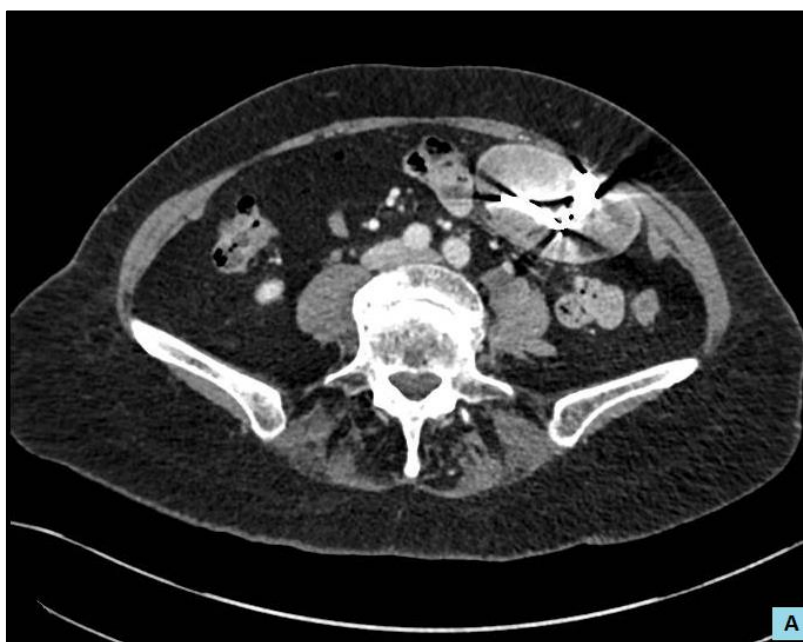respected serous lacerations, except for one loop which was firmly adhered to the mass, which forced performing a small intestine resection on either side of the adhesion, and a manual end-to-end small intestine anastomosis. The opening of the operating specimen objectified that it contains a compress marked by metal thread (Figure 3),

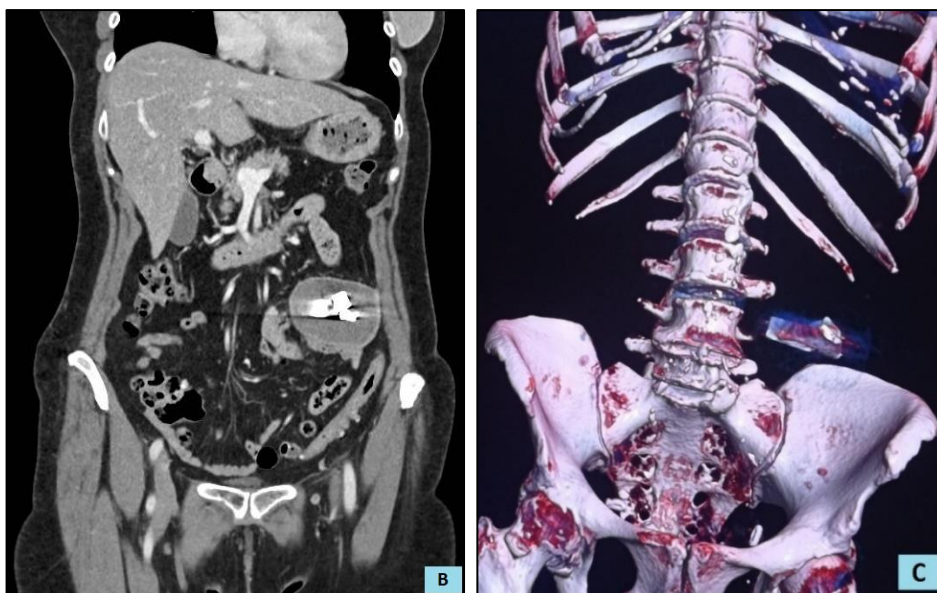
thus confirming the diagnosis of textiloma; the postoperative outcomes were simple, and the patient was discharged home on the 5th postoperative day. The follow-up sessions were unremarkable.

#### FIGURES

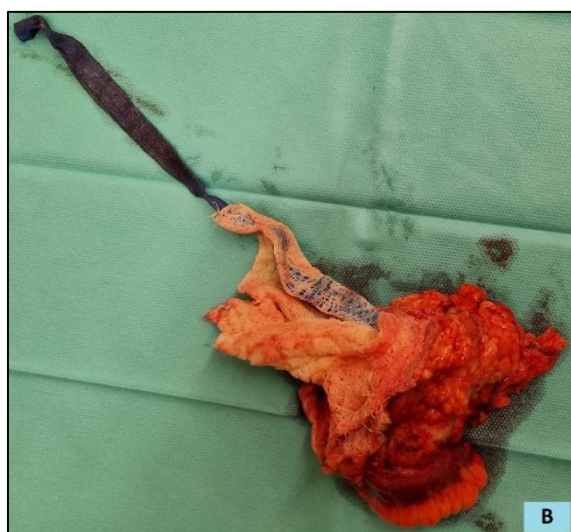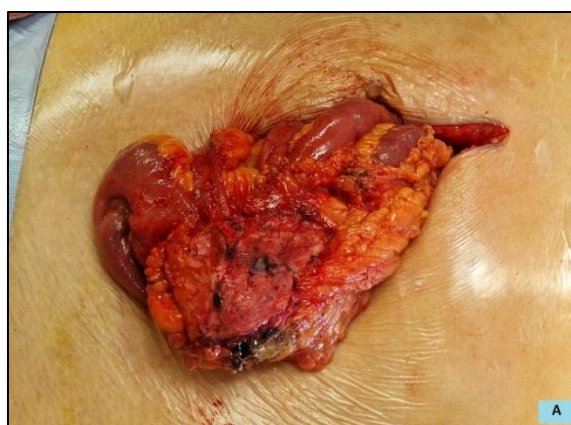


**Figure 1: MRI image in coronal section showing a tumor mass probably small bowel on the left flank.**





**Figure 2: A, B, C) CT images showing a cystic formation with a tissue contingent on the left flank, not enhancing after injection of the contrast product, also containing images of metallic density; C) 3D reconstruction showing the foreign body.**



**Figure 3: A) Operative image showing the mass of the flank after release of the anterior abdominal wall and the greater omentum with its adhesions to the small bowel loops; B) The opening of the surgical piece revealed the compress marked by a metal thread.**



## DISCUSSION

Although it is a rare incident, first reported by Wilson in 1884, and literature has no isolated cases and short series [1]. The textiloma remains an obsession for all surgeons which can lead to forensic pursuits, and it is responsible for multiple complications. Its incidence is estimated at 1/5500 surgery, of which the abdominal location is the most frequent (56%), followed by the pelvis (18%) and the thorax (11%), and especially during urgent interventions [2, 3].

The risk factors associated with the occurrence of textiloma are essentially presented by an emergency surgical procedure, obesity, an unexpected change in procedure, as well as the intervention of more than one surgical team, interventions during the second half of the night, important blood loss, and lack of textile and instrument counting [3, 4].

The presentation may be acute or relatively late depending on two pathological courses of the foreign body's reaction. One is an aseptic fibrinous response that creates adhesions and encapsulation, resulting in an inflammatory foreign body granuloma that can progress to calcification, and leading sometimes to very long tolerance. This event generally follows a rather silent clinical evolution, with - sometimes - a relatively late fortuitous discovery, months or even years after the initial surgery as it can simulate a tumour as in our observation. The other response is of the exudative type which leads to collection formation with or without secondary bacterial infection is symptomatic in the early postoperative period. The differential diagnosis in such cases includes postoperative collections and hematoma [5, 6].

The evolution can be towards the erosion of the surrounding tissues causing a migration of the foreign body, knowing that the retained textile can be partially or entirely in the intestinal lumen, then inducing an occlusion or even a spontaneous elimination, which can occur in about two weeks after the laparotomy, or it can be delayed up to several years. As it can fistulate in the skin or migrate through the diaphragm, vagina, bladder or liver [3- 8].

Hence, this disease progresses insidiously and is discovered years later by chance or as a "tumor syndrome" [6]. What makes the anamnesis and the notion of previous surgery an essential element for the diagnosis given the ineffectiveness of the physical examination, it associates chronic transit disorders with intermittent abdominal pain, with an inconstant palpable abdominal mass, as it is the case of our patient who presented atypical functional signs leading to additional useless examinations (FOGD and colonoscopy, abdominal ultrasound), which makes the CT scan, or even MRI for some teams, the examination of choice for pre-operative diagnosis of the textiloma, allowing also a complete exploration of the abdominal cavity in search

of complications (fistulas, pneumoperitoneum, abscess). The characteristic image is a spongiform appearance with the presence of small air bubbles [9], some calcifications or even an image of metallic density, as in our case. Textiloma can be confused with a digestive tumor (lymphoma, colonic adenocarcinoma... etc.) [10].

Surgery, no matter what the approach is (open or laparoscopic), remains the only way to confirm the presence of textiloma, as well as its treatment. The extraction of the foreign body can be easy in the early postoperative suites. However, the later the discovery, the more difficult the release of the mass may be, causing iatrogenic perforations as well as the association with intestinal resections as in our case [6- 11].

The establishment of standardized prevention means remains until now the only effective strategy to fight against this incident, and these means must be the subject of awareness raising and continuous training for all surgical teams, of which we can mainly cite:

- The counting of compresses and drapes by the surgeon, or one or even two members of the team at the beginning and the end of the intervention, which remains an effective but still insufficient measure;
- The use of marked radiopaque compresses proposed by CROSSEN *et al.*, in 1940 [6- 12], which allows an X-ray to be taken on the operating table in case of doubt.

## CONCLUSION

Textiloma is one of the most publicized medical errors, which presents the fear of any surgeon. Its clinico-radiological presentations are polymorphic and atypical, leading to confusion with other diagnoses. This makes it obligatory to think about it in during any doubtful situation with a surgical history, even an old one.

## REFERENCES

1. Chopra, S., Suri, V., Sikka, P., & Aggarwal, N. (2015). A case series on gossypiboma-varied clinical presentations and their management. *Journal of Clinical and Diagnostic Research: JCDR*, 9(12), QR01.
2. Cima, R. R., Kollengode, A., Garnatz, J., Storsveen, A., Weisbrod, C., & Deschamps, C. (2008). Incidence and characteristics of potential and actual retained foreign object events in surgical patients. *Journal of the American College of Surgeons*, 207(1), 80-87.
3. Sonarkar, R., Wilkinson, R., Nazar, Z., Gajendra, G., & Sonawane, S. (2020). Textiloma presenting as a lump in abdomen: A case report. *International Journal of Surgery Case Reports*, 77, 206-209.
4. Gawande, A. A., Studdert, D. M., Orav, E. J., Brennan, T. A., & Zinner, M. J. (2003). Risk factors for retained instruments and sponges after

- surgery. *New England Journal of Medicine*, 348(3), 229-235.
5. Atay, M., Ahmad, I. C., Bilgin, M., & Kocakoc, E. (2014). Gossypiboma/textiloma mimicking as tumour recurrence. *JPMA. The Journal of the Pakistan Medical Association*, 64(6), 708-710.
  6. Laytimi, F., Oubihi, A., Fdi,l M., Ousadden, A., Ait Taleb, K., El Bouhaddouti, H. (2021). Abdominal Textiloma, 10 Years after an Appendectomy: *Case Report. SAS J Surg*, 7(3), 146-149.
  7. Hajri, A., Touimi, K. B., El Berni, Y., Erguibi, D., Boufettal, R., Jai, S. R., & Chehab, F. (2021). Abdominal textiloma mimicking as gastrointestinal stromal tumor: a case report. *Annals of Medicine and Surgery*, 70, 102795. doi: 10.1016/j.amsu.2021.102795.
  8. Ahsaini, M., Aboubakry, S., El Ammari, J., Tazi, M. F., El Fassi, M. J., & Farih, M. H. (2019). Un textilome intra-vésicale mimant une tumeur vésicale (pseudotumeur vésicale): à propos d' un cas exceptionnel. *PAMJ-Clinical Medicine*, 1(49). doi: 10.11604/pamj-cm.2019.1.49.21013.
  9. O'Connor, A. R., Coakley, F. V., Meng, M. V., & Eberhardt, S. (2003). Imaging of retained surgical sponges in the abdomen and pelvis. *American journal of roentgenology*, 180(2), 481-489.
  10. Erguibi, D., Hassan, R., Ajbali, M., & Kadiri, B. (2015). Abdominal textiloma, about a case. *The Pan African medical journal*, 21, 244-244.
  11. Sarr, I., Ndong, A., Thiam, O., Sec,k M., & Touré, A. (2018). Intraluminal digestive textiloma under multiple clinical aspects. *J Afr Chir Digest*, 18(2), 2574-2578.
  12. Crossen, H. S., & Crossen, D. F. (1940). *Foreign bodies left in the abdomen*. CV Mosby Company.