

Primary Pulmonary Synovial Sarcoma; Abnormal Presentation of a Rare Lung Tumor

Rami A. Alomoor, MD^{1*}, Saad A. Alwraikat, MD¹, Laith M. Maqableh, MD¹, Hani M. Mostafa, MD¹, Amani A Almashaqbeh, RN¹, Ala M. Qayet, MD¹

¹Thoracic Surgery Division, General Surgery Department, King Hussein Medical Center, Amman, Jordan

DOI: [10.36347/sasjs.2023.v09i12.007](https://doi.org/10.36347/sasjs.2023.v09i12.007)

| Received: 10.11.2023 | Accepted: 17.12.2023 | Published: 28.12.2023

*Corresponding author: Rami A. Alomoor

Thoracic Surgery Division, General Surgery Department, King Hussein Medical Center, Amman, Jordan

Abstract

Case Report

Primary synovial sarcomas of the lung are a very rare entity in thoracic surgery. Unusual presentation make it hard to diagnose such disease and manage it probably even harder. We present two cases with same tumor but different appearance.

Keywords: Primary synovial sarcoma; lung mass; monophasic.

Copyright © 2023 The Author(s): This is an open-access article distributed under the terms of the Creative Commons Attribution 4.0 International License (CC BY-NC 4.0) which permits unrestricted use, distribution, and reproduction in any medium for non-commercial use provided the original author and source are credited.

INTRODUCTION

Primary lung synovial sarcomas are one of the rarest tumors of the lung (less than 1% of lung tumors), with only less than 20 cases in the whole literature. It affects mainly young patients and has a poor outcome. Its diagnosis is usually made post resection of the tumor which makes it difficult to have a preoperative management plan [1]. We present here two cases of young adults who were referred to thoracic surgery division at King Hussein Medical Center as case of cystic lesions mainly hydatid cysts and by doing proper evaluation and workup a malignant masses were the diagnosis.

Case 1:

A 35 year old Caucasian male, non smoker, with unremarkable past history, presented with shortness of breath and cough of 6 weeks prior to investigation. No abnormalities were detected on examination. Chest CT scans were done which showed an oval 4 by 5 cm left upper lobe cystic lesion with thick to solid content, primary diagnosis of hydatid cyst was made and the patient was referred to us for further management. By reviewing the CT scans, more solid component was realized and a PET scan was done which showed a hyperactive malignant mass with no other activity. CT guided FNA cytology was done and showed malignancy with no further information.

Left thoracotomy was done and frozen section showed round blue cell tumor, so completion lobectomy with negative margins was carried out. Histopathology

showed a monophasic malignant tumor composed of proliferation of spindle cells having hyperchromatic nuclei with moderate amount of eosinophilic-clear cytoplasm. The tumor was strongly positive for Bcl2 and Vimentin with focal positivity for CK and CD99. It was negative for SMA, Desmin and CD34 immunostains.

Patient recovery was uneventful and started chemotherapy after 6 weeks. 6 month follow up is encouraging.

Case 2:

A 23 year old Caucasian male, smoker (1pack/day), presented with sudden onset of hemoptysis and shortness of breath. Chest X ray showed bilateral lung oval lesions of variable sizes. Chest CT scans confirmed the lesions with thick contents and the patient was referred as case of multiple hydatid cysts. Review of the images showed more solid component and new CT scans showed dramatic change in size and number with pleural involvement within few weeks. Patient was admitted as his clinical condition deteriorated rapidly. PET scan showed hyper activity in all the lesions involving the chest (Figure 1). Minithoracotomy with lung and pleura biopsy was done.

Frozen showed round blue cell tumor, while definite histopathology expressed sarcomatous spindle cell monophasic tumor arranged in plump short fascicles with focal hemangiopericytoma-like area admixed with hemorrhagic fibrinoid martial. The cells were strongly Bcl2, Vimentin and CD99 (weak positivity) and negative for S-100, Calretinin, CD34, Desmin and CK.

Citation: Rami A. Alomoor, Saad A. Alwraikat, Laith M. Maqableh, Hani M. Mostafa, Amani A Almashaqbeh, Ala M. Qayet. Primary Pulmonary Synovial Sarcoma; Abnormal Presentation of a Rare Lung Tumor. SAS J Surg, 2023 Dec 9(12): 985-987.

The patient was started on chemotherapy within one week of diagnosis, now after six months he has dramatic response (Figure 2).

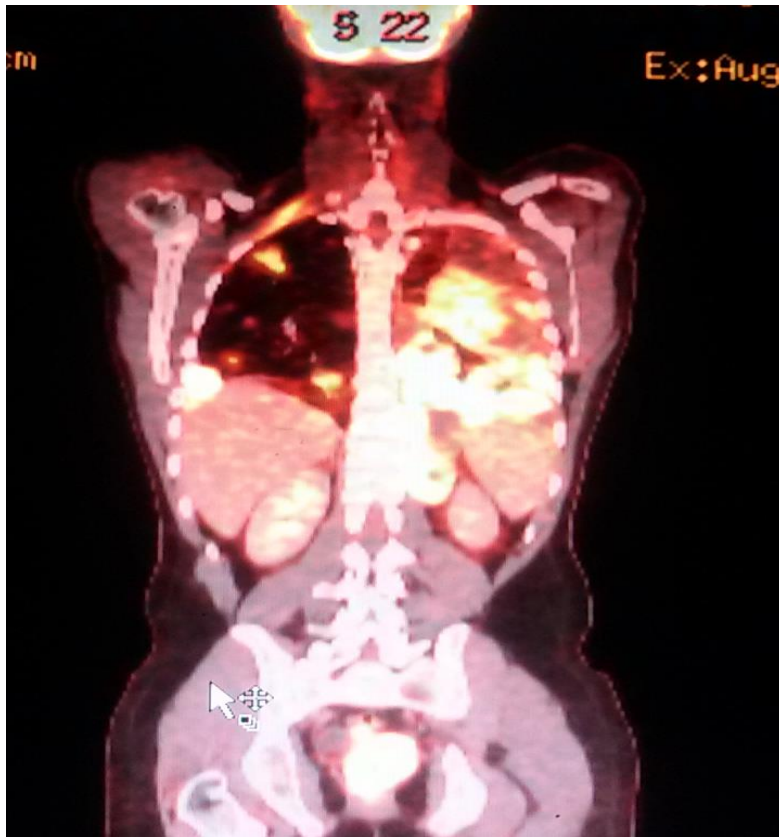


Figure 1: PET scan at time of presentation.

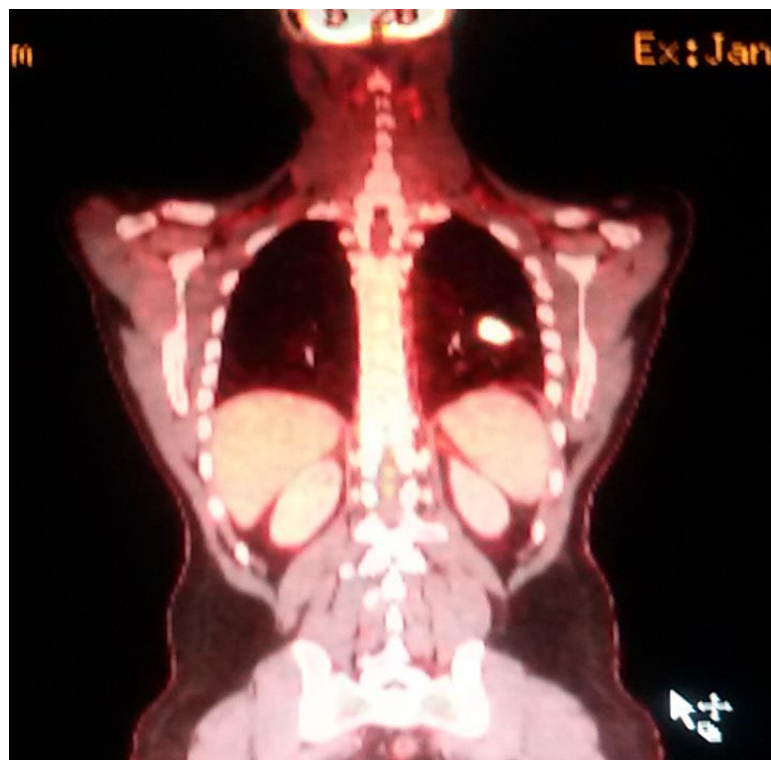


Figure 2: 6 month after chemotherapy with remarkable response

DISCUSSION

Synovial sarcomas are a rare entity of soft tissue sarcoma comprising less than 14% of sarcomas, usually affecting extremities. Primary pulmonary synovial sarcomas are even rarer with less than 0.5-1% of all lung tumors, it affects young population with median age of 20 years [2]. It has wide range of presentation from shortness of breath, chest pain and hemoptysis. Appearance on chest CT scans has also wide variety coming as single lung lesion, multiple lesions and even bilateral. Pleural involvement is not uncommon. PET imaging can add much information about the disease severity and activity [3].

Histopathologically it has four subtypes: biphasic, monophasic epithelial, monophasic fibrous and poorly differentiated. Immunohistological stains can differentiate it from other tumors, were Bcl2 and Vimentin are positive. CD99, Desmin and S-100 are negative [4].

Cytogenetic studies helps in differentiate monophasic from biphasic. And is characterized by a reciprocal chromosomal translocation (X;18) (p11.2; q11.2) which results from fusion of SYT gene on chromosome 18 to either of two genes; SSS1 and SSS2 on chromosome X [5].

Prognosis for these tumors is poor. Many factors associated with this are large size, multiplicity,

older age >25 years and pleural involvement. No definite treatment modality is proposed yet with complete resection when possible is the best, followed by chemotherapy [4].

REFERENCES

1. Galetta, D., Pelosi, G., Leo, F., Solli, P., Veronesi, G., Borri, A., ... & Spaggiari, L. (2007). Primary thoracic synovial sarcoma: factors affecting long-term survival. *The Journal of Thoracic and Cardiovascular Surgery*, 134(3), 808-809.
2. Ariel, I. M., & Pack, G. T. (1963). Synovial sarcoma: Review of 25 cases. *New England Journal of Medicine*, 268(23), 1272-1275.
3. Frazier, A. A., Franks, T. J., Pugatch, R. D., & Galvin, J. R. (2006). Pleuropulmonary synovial sarcoma. *Radiographics*, 26(3), 923-940.
4. Dennison, S., Wepler, E., & Giacoppe, G. (2004). Primary pulmonary synovial sarcoma: a case report and review of current diagnostic and therapeutic standards. *The Oncologist*, 9(3), 339-342.
5. Hosono, T., Hironaka, M., Kobayashi, A., Yamasawa, H., Bando, M., Ohno, S., ... & Sugiyama, Y. (2005). Primary pulmonary synovial sarcoma confirmed by molecular detection of SYT-SSX1 fusion gene transcripts: a case report and review of the literature. *Japanese journal of clinical oncology*, 35(5), 274-279.