

# Burkitt Lymphoma with Malignant Ovarian Manifestation: A Case Report and Literature Review

A. Benamar<sup>1\*</sup>, N. Mekkaoui<sup>1</sup>, M. B. Idrissi<sup>1</sup>, M. K. Saoud<sup>1</sup>, N. Mamouni<sup>1</sup>, S. Errarhay<sup>1</sup>, C. Bouchikhi<sup>1</sup>, A. Banani<sup>1</sup>

<sup>1</sup>Department of Gynecology and Obstetrics, Hassan II University Hospital, Faculty of Medicine and Pharmacy of Fez, Sidi Mohammed Ben Abdellah University, Fez, Morocco

DOI: [10.36347/sasjs.2023.v09i12.010](https://doi.org/10.36347/sasjs.2023.v09i12.010)

| Received: 20.11.2023 | Accepted: 26.12.2023 | Published: 30.12.2023

\*Corresponding author: A. Benamar

Department of Gynecology and Obstetrics, Hassan II University Hospital, Faculty of Medicine and Pharmacy of Fez, Sidi Mohammed Ben Abdellah University, Fez, Morocco

## Abstract

## Case Report

A lymphoma presenting as an ovarian mass with an initial manifestation is unusual and can cause confusion for the clinician, as its presentation may resemble that of other much more common tumors. Malignant lymphoid cells may appear in the ovary either as a primary neoplasm or as a secondary manifestation of an occult or known disseminated disease. The most common presenting signs or symptoms of malignant lymphomas involving the ovaries are abdominal or pelvic pain or a mass. We report a case of bilateral primary Burkitt lymphoma of the ovaries in a 14-year-old girl presenting with abdominal distension, abdominal pain, hematemesis, and melena. Ultrasound and CT imaging suggested a provisional diagnosis of ovarian tumor. The diagnosis of Burkitt lymphoma was established by histopathological examination of a biopsy from a digestive thickening. The tumor was classified as Burkitt lymphoma with pleural, intestinal, peritoneal, nodal (coelio-mesenteric), renal, ovarian, and bone involvement with medullary infiltration.

**Keywords:** Lymphoma, metastasis, MRI, histology.

Copyright © 2023 The Author(s): This is an open-access article distributed under the terms of the Creative Commons Attribution 4.0 International License (CC BY-NC 4.0) which permits unrestricted use, distribution, and reproduction in any medium for non-commercial use provided the original author and source are credited.

## INTRODUCTION

Involvement of the ovary in lymphomatous processes is rare, but the ovary is a common site in the female genital tract to be involved by hematologic malignancies. The occurrence of lymphomas primarily developing in the ovaries has long been a subject of debate as no lymphoid tissue is found in the ovaries. Involvement of the ovary by malignant lymphoma can be primary or secondary and is incidentally discovered during an evaluation for abdominal or pelvic complaints. We present a case of Burkitt lymphoma manifesting as an ovarian mass with gastrointestinal symptoms and occult extra-ovarian disease in this article.

## OBSERVATION

We report the case of a 14-year-old patient with no notable medical history. The current disease history dates back 2 years with the onset of chronic abdominal pelvic pain, associated with abdominal distension. The course was marked by an aggravation of symptoms with the occurrence of 2 episodes of moderate epistaxis and an episode of hematemesis, with a history of cessation of bowel movements without the cessation of gas for 3 days, evolving in a context of unspecified fever. The patient consulted in our facility.

General examination: Conscious child, stable on HD and respiratory plans, slightly pale and asthenic. Weight 80 kg, Height 174 cm (SD), HR 100, RR 22 cpm, Temperature 38.9, BP 110/70, SaO<sub>2</sub> at 99%. Abdominal examination: Distended abdomen, dullness of the flanks with a shifting dullness sign, abdomino-pelvic mass occupying the right and left hypogastric regions, about 12 cm in size, firm on palpation, and fixed in relation to the deep plane. No splenomegaly, no hepatomegaly. Gynecological examination: Not performed, patient claims to be a virgin. ENT examination: Clear throat, clear eardrums. Pleuro-pulmonary examination: Eupneic, no rales on auscultation. Cardiovascular examination: Audible B1 B2. Free hernial orifices. OGE: Well-differentiated female type, Tanner stage 3 pubertal stage. Neurological examination: Conscious child GCS 15, no motor or sensory deficit. Free lymph node areas. Free joints. Skin examination: No abnormalities.

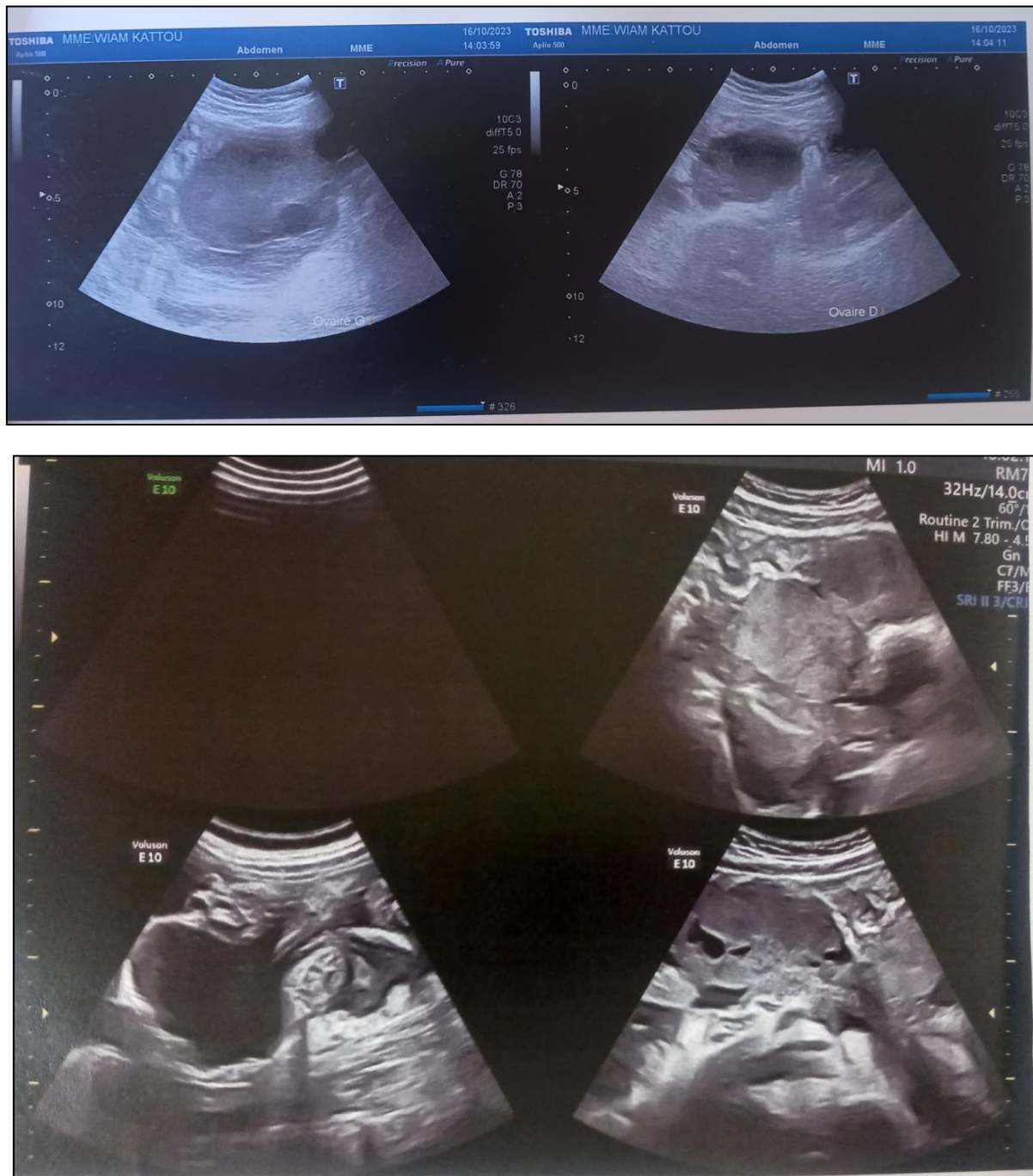### Biological Assessment:

Hb: 8.3, WBC: 7700, ANC: 4390, Lymph: 2540, PLT: 121,000. TP: 100% APTT: 11.3. Albumin: 33. Ca<sup>2+</sup>: 90, Creatinine: 7 Urea: 0.2. CRP = 156. Electrolytes: PT: 58, Na<sup>+</sup>: 158, K<sup>+</sup>: 3, Phosphorus: 26. AST: 16, ALT: 6. LDH: 577. ACE: 0.94 ng/ml, CA125: 80 U/ml, AFP: 1.6 ng/ml.

**Citation:** A. Benamar, N. Mekkaoui, M. B. Idrissi, M. K. Saoud, N. Mamouni, S. Errarhay, C. Bouchikhi<sup>1</sup>, A. Banani. Burkitt Lymphoma with Malignant Ovarian Manifestation: A Case Report and Literature Review. SAS J Surg, 2023 Dec 9(12): 997-1001.

**Abdomino-pelvic ultrasound:**

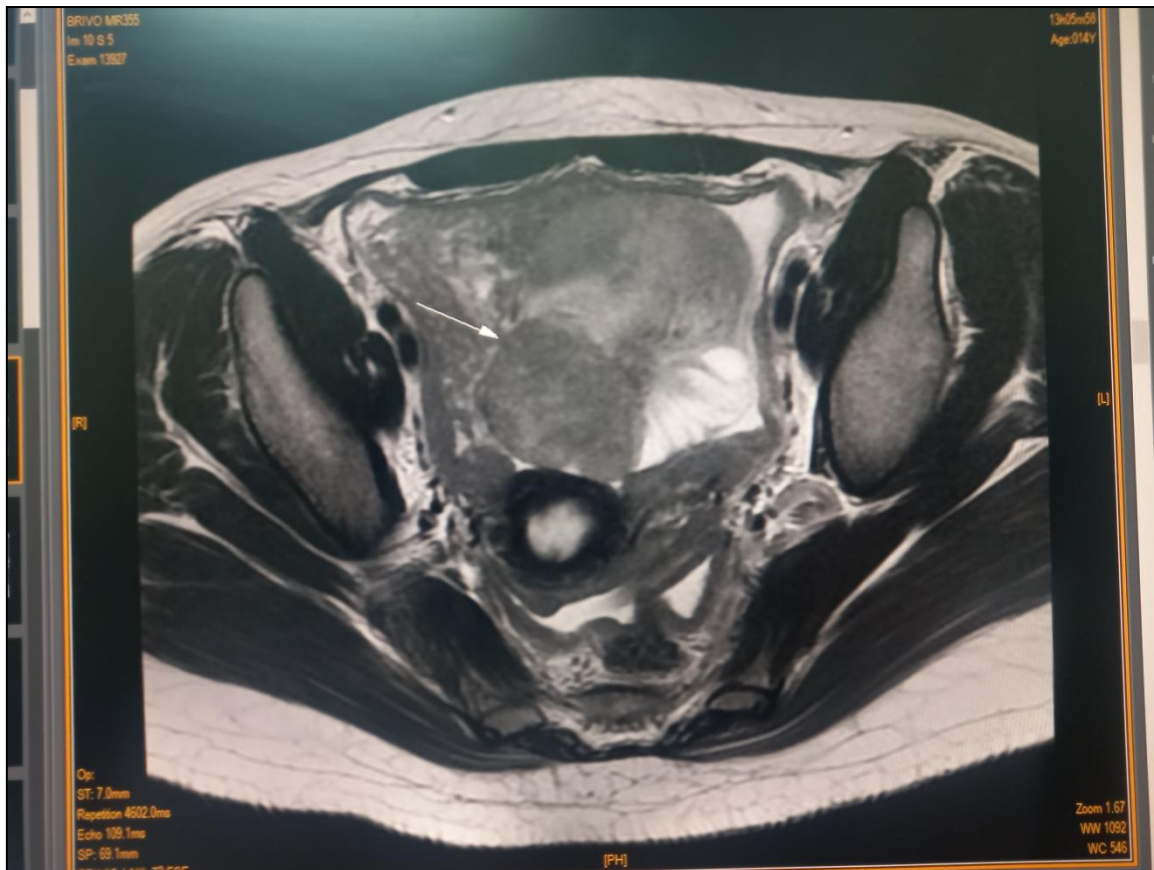
- Ovaries enlarged, with bilateral tissue masses measuring 67 mm on the right and 77 mm on the left, with moderate peritoneal effusion.
- Ultrasound appearance suggestive of ileocecal intussusception on lymphomatous-looking digestive thickening.
- Bilateral lymphomatous involvement of the ovaries and kidneys.
- Large effusion, compartmentalized in places.



**Figure 1: Ultrasound showing the two ovarian masses**

MRI pelvis revealing: voluminous, malignant, bilateral ovarian tumor masses, confluent and extensively infiltrating, measuring 524648mm and 615595mm on the left, suggestive of malignant tumors, with infiltration of mesenteric fat, agglutination, and

infiltration of intestinal loops, associated with a moderate to abundant peritoneal effusion, visualizing two peritoneal masses measuring 42\*33mm and 34\*25mm, overall consistent with peritoneal carcinomatosis.



**Figure 2: Pelvic MRI showing two bilateral ovarian masses**

CT scan of the chest, abdomen, and pelvis (TAP):

- Absence of contrast extravasation.
- Ileo-cecal intussusception over a parietal digestive tissue process at the ileo-cecal junction associated with lymphomatous coelio-mesenteric adenopathies.
- Voluminous bilateral tissue ovarian masses fitting into the same framework.
- Large amount of intra-peritoneal effusion associated with a moderate amount of bilateral pleural effusion.

The patient underwent a CT-guided biopsy of the digestive thickening with the following pathological results: Histologically, there is a tumor proliferation arranged in diffuse sheets. The tumor cells have a lymphoid appearance, round, small to medium in size, with fine chromatin and scant basophilic cytoplasm. Several images of apoptosis with tingible body macrophages are noted, suggesting Burkitt lymphoma. Bone marrow examination reveals a heterogeneous and hemodiluted hypocellular marrow with hypoplasia of granulocytic and erythroblastic lineages and the presence of 5% blasts.

The patient underwent COPADM chemotherapy with a significant regression in the size of ovarian masses and digestive thickening.

## DISCUSSION

Malignant lymphoid tumors of the female genital tract are uncommon, though the ovaries are the most commonly affected sites, with up to 25% of women dying from lymphomas having ovarian involvement. Ovarian involvement in malignant lymphoma can be primary or secondary. Secondary involvement may present as an initial clinical presentation of occult extra-ovarian disease or as a manifestation of widely disseminated disease. The majority of ovarian-involved lymphomas are of B-cell phenotype; among these, Burkitt lymphoma [4] is defined as a non-Hodgkin lymphoma (NHL) in which tumor cells primarily target B lymphocytes of the humoral immune system.

Patients with Burkitt lymphoma often present significantly elevated serum levels of lactate dehydrogenase (LDH) and cancer antigen 125 (CA-125), as observed in our patient. LDH levels can vary from moderate (2000 IU/mL) to high (14,500 IU/mL). Although biomarkers such as carcinoembryonic antigen 19-9 (CA19-9), carcinoembryonic antigen (CEA), alpha-fetoprotein (AFP), and human chorionic gonadotropin beta ( $\beta$ -HCG) generally remain normal in patients with ovarian Burkitt lymphoma, they can aid in the differential diagnosis of other ovarian tumors.

The diagnosis of intra-abdominal Burkitt lymphoma is often delayed as symptoms may be



nonspecific or even absent. Abdominal pain, distension, nausea, vomiting, amenorrhea, irregular menstruation, and osteoarticular pain are the most common findings. After the abdomen, the most frequent presentation site is the head and neck, with the majority of Burkitt lymphoma patients (70%) presenting with advanced stages. Some cases are characterized by extensive medullary infiltration with possible bone pain as an initial symptom. Although Burkitt lymphoma frequently affects the maxilla and mandible, other rarer bone sites such as the iliac wing, central skull base, and cranial vault may be involved.

On CT, ovarian lymphoma appears as hypodense lesions with moderate contrast enhancement, without significant necrosis, hemorrhage, or calcifications, and with relative structural homogeneity. Although CT remains the most important tool for staging and monitoring after chemotherapy, MRI offers better characterization than CT and is more useful in distinguishing solid components from complex cystic fluid components and assessing spatial relationships of pelvic masses.

Ferrozzi *et al.*, [8] described the MRI results of five patients with non-Hodgkin ovarian lymphoma. MRI showed that ovarian lesions were homogeneous masses, round or oval in shape, with low homogeneous signal intensity on T1-weighted images and intermediate to high signal intensity on T2-weighted images.

Mitsumori *et al.*, [9] and Crawshaw *et al.*, [10] presented two cases of Burkitt-type ovarian lymphoma. On MRI, the masses had low signal intensity on T1-weighted images and intermediate signal intensity on T2-weighted images with well-defined, round cysts of high signal intensity at the periphery, corresponding to follicles. In our case, the cysts were also located inside the lesion and not only at the periphery.

Bilateral ovarian lymphomas must also be differentiated from metastatic ovarian involvement. Ovarian metastases account for approximately 30% of all ovarian neoplasms and are usually bilateral with a mixed (solid and cystic) appearance. Finally, epithelial tumors are generally mainly cystic, although associated with variable proportions of solid tissue. As in our patient, Burkitt lymphoma associated with peritoneal carcinomatosis, ascitic effusion, and elevated CA125 levels has been detected in some cases, mimicking ovarian cancer and causing confusion for clinicians. However, bone involvement by ovarian malignancies is relatively rare, while it is more common in lymphoma cases. Bone lesions associated with a homogeneous and well-defined ovarian neoplasm that does not show an infiltrative growth pattern or regressive changes in a young woman may suggest lymphoma. MRI is the most useful and comprehensive tool for characterizing ovarian lesions and suggesting the diagnosis before histopathological results.

The primary treatment for ovarian lymphoma consists of multi-agent chemotherapy. Surgical procedures in ovarian lymphoma play a role in the diagnostic process, providing samples for diagnosis and staging. Extensive reduction or bilateral oophorectomy is not beneficial, and tumor resection should be avoided as recovery after surgery can delay the start of urgent systemic treatment required in this rapidly growing tumor.

Differentiating ovarian lymphoma from other ovarian neoplasms is essential since ovarian lymphoma is treated with systemic chemotherapy, whereas in germ cell tumors and epithelial neoplasms, surgical resection is indicated, followed by chemotherapy only in advanced-stage disease.

## CONCLUSION

Considering that Burkitt lymphoma is defined as an invasive malignant tumor with a high global mortality rate, it should be considered a differential diagnosis for solid ovarian tumors in women, especially those of childbearing age. Preoperative diagnosis is extremely challenging. Laboratory tests, including a complete blood count, comprehensive metabolic panels, and measurements of LDH and uric acid levels, may be helpful in the differential diagnosis."

## REFERENCES

1. Ja, F. (1991). Malignant lymphoma, pseudolymphoma, and hematopoietic disorders of the female genital tract. *Pathology annual*, 26, 227-263.
2. Nelson, G. A., Dockerty, M. B., Pratt, J. H., & ReMine, W. H. (1958). Malignant lymphoma involving the ovaries. *American Journal of Obstetrics and Gynecology*, 76(4), 861-871.
3. Monterroso, V., Jaffe, E. S., Merino, M. J., & Medeiros, L. J. (1993). Malignant lymphomas involving the ovary: a clinicopathologic analysis of 39 cases. *The American journal of surgical pathology*, 17(2), 154-170.
4. Kosari, F., Daneshbod, Y., Parwaresch, R., Krams, M., & Wacker, H. H. (2005). Lymphomas of the female genital tract: a study of 186 cases and review of the literature. *The American journal of surgical pathology*, 29(11), 1512-1520.
5. Tanimura, A., Adachi, Y., Tanda, M., Yuasa, H., Ishii, Y., & Katou, Y. (2005). Primary peripheral B cell lymphoma, Burkitt-like, of the cranial vault. *Acta haematologica*, 113(4), 258-261.
6. Ferrozzi, F., Catanese, C., Uccelli, M., & Bassi, P. (1998). Ovarian lymphoma. Findings with ultrasonography, computerized tomography and magnetic resonance. *La Radiologia medica*, 95(5), 493-497.
7. Eren, S., Kantarci, M., & Erdoğan, F. (2004). Ovarian Burkitt's lymphoma as a cause of 'omental cake' sign on computerised tomography. *Journal of Obstetrics and Gynaecology*, 24(4), 463-465.

8. Ferrozzi, F., Tognini, G., Bova, D., & Zuccoli, G. (2000). Non-Hodgkin lymphomas of the ovaries: MR findings. *Journal of computer assisted tomography*, 24(3), 416-420.
9. Mitsumori, A., Joja, I., & Hiraki, Y. (1999). MR appearance of non-Hodgkin's lymphoma of the ovary. *AJR. American journal of roentgenology*, 173(1), 245-245.
10. Crawshaw, J., Sohaib, S. A., Wotherspoon, A., & Shepherd, J. H. (2007). Primary non-Hodgkin's lymphoma of the ovaries: imaging findings. *The British Journal of Radiology*, 80(956), e155-e158.
11. Jung, S. E., Lee, J. M., Rha, S. E., Byun, J. Y., Jung, J. I., & Hahn, S. T. (2002). CT and MR imaging of ovarian tumors with emphasis on differential diagnosis. *Radiographics*, 22(6), 1305-1325.
12. Stepniak, A., Czuczwar, P., Szkodziak, P., Wozniakowska, E., Wozniak, S., & Paszkowski, T. (2017). Primary ovarian Burkitt's lymphoma: a rare oncological problem in gynaecology: a review of literature. *Archives of Gynecology and Obstetrics*, 296, 653-660. doi: 10.1007/s00404-017-4478-6
13. Cecchetto, G. (2014). Gonadal germ cell tumors in children and adolescents. *Journal of Indian Association of Pediatric Surgeons*, 19(4), 189-194. doi: 10.4103/0971-9261.141995
14. Virgone, C., Alaggio, R., Dall'Igna, P., Buffa, P., Tonegatti, L., Ferrari, A., ... & Cecchetto, G. (2015). Epithelial tumors of the ovary in children and teenagers: a prospective study from the Italian TREP Project. *Journal of Pediatric and Adolescent Gynecology*, 28(6), 441-446. doi: 10.1016/j.jpag.2014.12.010
15. Rosolen, A., Perkins, S. L., Pinkerton, C. R., Guillerman, R. P., Sandlund, J. T., Patte, C., ... & Cairo, M. S. (2015). Revised international pediatric non-Hodgkin lymphoma staging system. *Journal of clinical oncology*, 33(18), 2112-2118. doi: 10.1200/JCO.2014.59.7203
16. Pillon, M., Mussolin, L., Carraro, E., Conter, V., Aricò, M., Vinti, L., ... & Basso, G. (2016). Detection of prognostic factors in children and adolescents with Burkitt and Diffuse Large B-Cell Lymphoma treated with the AIEOP LNH-97 protocol. *British journal of haematology*, 175(3), 467-475. doi: 10.1111/bjh.14240
17. Shaikh, F., Murray, M. J., Amatruda, J. F., Coleman, N., Nicholson, J. C., Hale, J. P., ... & Frazier, A. L. (2016). Paediatric extracranial germ-cell tumours. *The Lancet Oncology*, 17(4), e149-e162. doi: 10.1016/S1470-2045(15)00545-8
18. Billmire, D. F. (2006). Malignant germ cell tumors in childhood. *Semin Pediatr Surg*, 15(1), 30-36. doi: 10.1053/j.sempedsurg.2005.11.006
19. Shacham-Abulafia, A., Nagar, R., Eitan, R., Levavi, H., Sabah, G., Vidal, L., ... & Raanani, P. (2013). Burkitt's lymphoma of the ovary: case report and review of the literature. *Acta Haematologica*, 129(3), 169-174. doi: 10.1159/000345248
20. Roschewski, M., Staudt, L. M., & Wilson, W. H. (2022). Burkitt's lymphoma. *New England Journal of Medicine*, 387(12), 1111-1122. doi: 10.1056/NEJMra2025746