

On-Lay Mesh Repair in Ventral Hernia – Our Experience

Dr. Chittaranjan Das^{1*}, Dr. Suzon Kumar Mazumder², Prof. Dr. Mohammed Mostafizur Rahman³, Prof. Dr. Md. Ibrahim Siddique³

¹Associate Professor, Department of General Surgery, Bangabandhu Sheikh Mujib Medical University, Dhaka, Bangladesh

²Junior Consultant (RS), Surgical Oncology, National Institute of Cancer Research & Hospital, Mohakhali, Dhaka, Bangladesh

³Professor, Department of General Surgery, Bangabandhu Sheikh Mujib Medical University, Dhaka, Bangladesh

DOI: [10.36347/sasjs.2023.v09i12.011](https://doi.org/10.36347/sasjs.2023.v09i12.011)

| Received: 05.11.2023 | Accepted: 21.12.2023 | Published: 30.12.2023

*Corresponding author: Dr. Chittaranjan Das

Associate Professor, Department of General Surgery, Bangabandhu Sheikh Mujib Medical University, Dhaka, Bangladesh

Abstract

Original Research Article

Background: Ventral hernias are common surgical conditions that can lead to serious complications if left untreated. The use of synthetic mesh in ventral hernia repair has become a widely accepted practice among general surgeons. **Objective:** This study was undertaken to assess the outcomes of onlay mesh repair for ventral hernias. **Methods:** A total of 52 patients with ventral hernias who underwent open onlay mesh repair were included in the study, focusing on the period from April 2020 to September 2022, with exclusion criteria applied to those with uncontrolled diabetes mellitus and recurrent ventral hernias. Patient demographics were analyzed, and complications were documented. The data were then statistically analyzed to determine the outcomes. **Results:** The study found that 7.6% of patients developed complications, with no reported mortality. The mean age of the patients was 46.38 ± 12.28 , and there was a female preponderance. The use of prosthetic non-absorbable onlay mesh resulted in a relatively low complication rate among the study participants. **Conclusions:** Onlay mesh repair using non-absorbable prosthetic mesh proves effective and presents a manageable complication rate in ventral hernia surgery, offering a promising option for improved patient outcomes.

Keywords: Ventral hernia, onlay mesh repair, complications, prosthetic mesh.

Copyright © 2023 The Author(s): This is an open-access article distributed under the terms of the Creative Commons Attribution 4.0 International License (CC BY-NC 4.0) which permits unrestricted use, distribution, and reproduction in any medium for non-commercial use provided the original author and source are credited.

INTRODUCTION

A ventral hernia is characterized by a defect in the fascia of the anterior abdominal wall, allowing intermittent or continuous protrusion of abdominal content [1]. This condition is commonly categorized as congenital, traumatic, or incisional, and further classified based on anatomical location, defect size, and the number of previous scars [2]. In adults, over 80% of ventral hernias result from prior surgeries, leading to the term "incisional hernia," with an incidence ranging from 0-20% after abdominal procedures. Although clinically evident 2 to 5 years post-surgery, the process initiates within the first post-operative month [3]. Incisional hernias stem from a biochemical failure in acute fascial wound healing, combined with hindrances to tissue repair and normal support function of the abdominal wall [4]. Apart from incisional hernias, ventral hernias can also arise spontaneously, such as umbilical, para-umbilical, epigastric, spigelian, or lumbar hernias [5].

Numerous methods have been devised for the repair of ventral hernias. Traditionally, primary repair involved suturing the robust fascial tissue on both sides

of the defect. However, long-term follow-up studies reveal recurrence rates ranging from 41-52% with this approach. The advent of tension-free hernioplasty, [6] introduced by Usher with polypropylene mesh repair, marked a significant advancement. Meshes are generally classified into two types: biologic and synthetic [7]. Biologic meshes, derived from collagen, often sourced from animals, and synthetic meshes, composed of polyester materials such as polytetrafluoroethylene, polypropylene, and polystar. Hernioplasty procedures involving the implantation of large prosthetic meshes seem to exhibit lower failure rates (12-24%). However, this method necessitates the dissection of a wide area of soft tissue, contributing to an elevated risk of wound infection and complications related to the wound (12% or higher) [8]. The outcomes of on-lay mesh reconstruction in the extensive hernia category were notably superior to those of sub-lay repair. A significantly lower recurrence rate was observed in on-lay repair 12% compared to 20%, $p < 0.05$ [9]. The purpose of this study was to assess the outcomes of on-lay mesh repair for ventral hernias in our population, aiming to determine its suitability as the preferred

surgical treatment for ventral hernia repair in Bangladesh.

MATERIALS AND METHODS

This retrospective study was conducted in Department of Surgery, Bangabandhu Sheikh Mujib Medical University, Dhaka and in a private hospital, from April 2019 to September 2022. Patients present with ventral hernia who underwent open hernia repair with on-lay mesh repair technique admitted in the department of surgery of the same hospital during study period was taken as study population. All hernias were operated by same technique which included closure of the hernia defect with non-absorbable suture (typically prolene 2/0) followed by an on-lay polypropylene mesh extending beyond the line of closure by at least 5 centimeter in all directions. Closed suction drain was kept in situ and removed when drainage was less than 20 ml/day. During operation hernia sacs were dissected out completely for defining the neck and after opening it adhesiolysis done, then the sac was excised. The mesh was placed superficial to external fascia and fixed by non-absorbable sutures. All patients were given an Inj. Ceftriaxone 1gram intravenously on induction and

continued for two days post-operatively and changed to oral cefixime 200 mg.12 hourly for the next 7 days. During discharge all the patients were advised to communicate, if they feel any kind of discomfort related to the operation. Information was collected about post-operative complications like, seroma, wound infection, haematoma and post-operative stay.

RESULTS

A total of 52 patients underwent open repair for ventral hernia during the study period. Obesity was a dominant feature. Most of them were obese. Mean age of the patients 46.38 ± 12.28 , Male 10 (19.23%), while 42 are female (80.77%). The male-female ratio 1:4.2. Demographic data are reported in table 1. It was elective clean surgery. In the peri-operative period complications occurred in 7.6%, Superficial wound infection 2(3.8%), Seroma 2(3.8%) patients. Post-operative complications were wound related SSI and did not require prolong hospital stay or intervention. We managed the cases by regular dressing and antibiotic. Seroma was treated conservatively. There was no chronic mesh infection or sinus tract. There was no post-operative mortality.

Table 1: Distribution of age and sex of the study population (n=52)

Variable	No. of Patients	Percentage (%)	Mean±SD
Age			
<30	3	5.8	46.38±12.28
30-40	19	36.5	
41-50	8	15.4	
51-60	13	25.0	
>60	9	17.3	
Gender			
Male	10	19.23	1:4.2
Female	42	80.77	

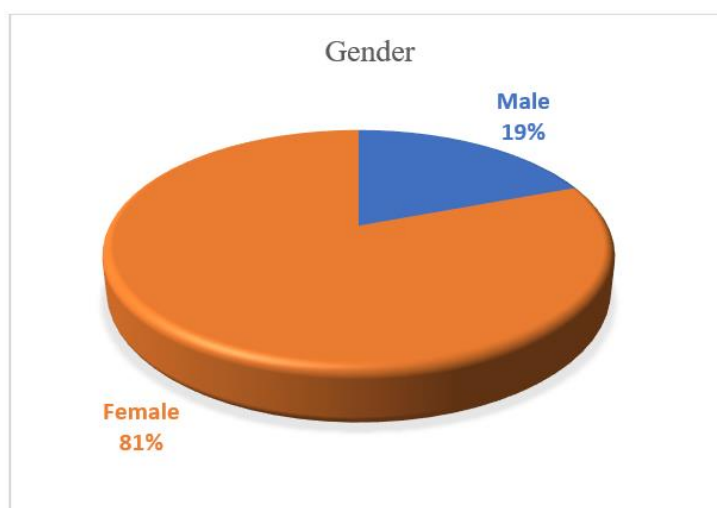


Figure 1: Gender Distribution among the Study Participants

Patient demographics reveal a total of 52 patients, with 10 males (19.23%) and 42 females (80.77%), resulting in a male-female ratio of 1:4.2. This

data highlights the gender distribution within the patient population.

Table 2: Types of hernia of the study subject (n=52)

Types of hernia	No. of Patients	Percentage (%)
Incisional hernia	34	63.38
Umbilical hernia	2	3.85
Epigastric	3	5.77
Para-umbilical hernia	13	25.00

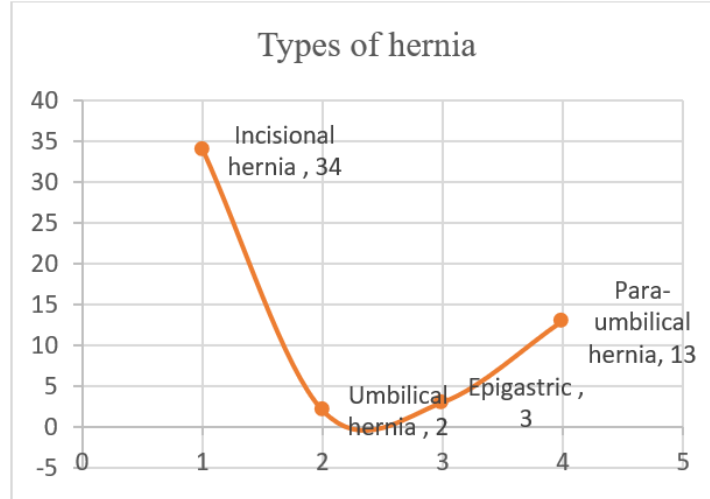


Figure 2: Hernia Classifications in the Study

The Distribution of different types of hernia shows that incisional hernia is the most prevalent (65.38%), followed by para-umbilical hernia (25.00%), while umbilical and epigastric hernias have lower

incidences (3.85% and 5.77%, respectively). The table provides a concise overview of hernia distribution among the patients.

Table-3: Post-operative parameters

Post-operative complications	No. of Patients	Percentage (%)
Superficial wound infection	2	3.8
Seroma	2	3.8
Total	4	7.6

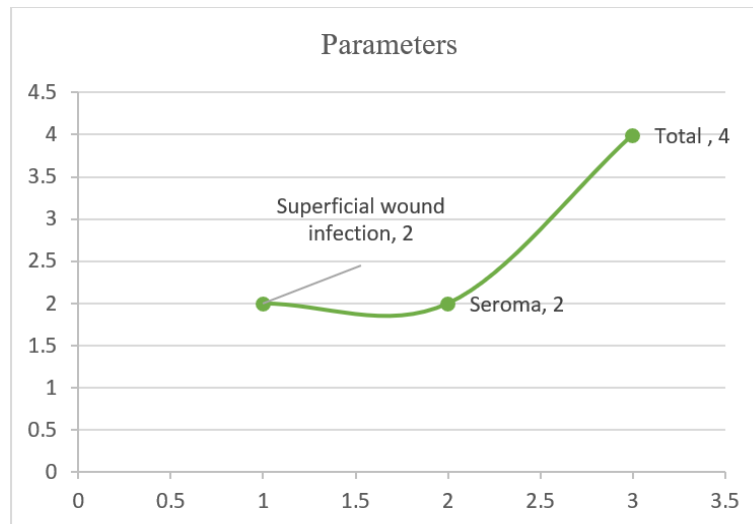


Figure 3: Evaluation of Post-operative Factors

This study outlines post-operative complications in the study. Superficial wound infections and seromas occurred in 3.8% of patients each,

contributing to a total post-operative complication rate of 7.6%, with a total of four patients experiencing these issues after surgery.

Table 4: Duration of Hospital Stay (n=52)

Duration of hospital stay	No. of Patients	Percentage (%)	Mean±SD
≤5 days	37	71.2	4.21±2.51
>5 days	15	28.8	

DISCUSSION

Ventral hernias encompass both spontaneous occurrences and, more commonly, incisional hernias following abdominal surgeries [10]. Approximately 2 to 10% of all abdominal operations result in an incisional hernia. While small hernias with a diameter less than 2.5 cm can often be effectively closed through primary tissue repair, larger ones (exceeding 2.5 cm) exhibit recurrence rates of up to 30-40% with tissue repair alone [11]. The recurrence of hernias can be distressing for patients and pose challenges for surgeons. Tension-free repairs utilizing prosthetic mesh have significantly reduced recurrence rates to negligible levels [12]. Despite the commendable outcomes, concerns about increased infection risk due to the introduction of foreign bodies and cost considerations persist. Nevertheless, this approach has led to shortened operating times and hospital stays. Primary tissue repair is associated with a higher recurrence rate, making tension-free mesh repair the preferred and ideal technique for hernia repair nowadays [13].

In addition to the risk of recurrence, post-operative complications such as seroma formation and wound infection are primarily linked to the extensive dissection and manipulation of tissues during hernia repair [14]. The effectiveness of hernia repair surgery is typically gauged by the occurrence of hernia recurrence, which can be distressing for patients and pose challenges for surgeons. The introduction of prosthetic mesh has brought about a transformative shift in hernia repair, offering a tension-free approach and contributing to improved outcomes in this field [15].

The study encompassed 52 patients, Males 10(19.23%), while 42 were females (80.77%). The male-female ratio is 1:4.2. Gynecological/obstetrical operations were the most commonly reported index surgeries. Ventral hernias predominantly occur in the lower abdomen of females. These findings align with previous studies by Shah *et al.*, [16]. In our study mean total time for operation was 78 minutes, In comparable studies by Carbaja *et al.*, [17]. (87 minutes), Rameshaw *et al.*, [18]. (56 minutes), and Badiger S *et al.*, [19]. (55 minutes) shows similar results. There was no intra-operative complications.

In our study, the occurrence of wound infection was 3.8%, a result which is much lower than the findings reported by Shah *et al.*, [16]. Given that open ventral hernia repair typically involves more extensive tissue dissection, the likelihood of complications related to wounds is increased. The wound infections were effectively managed through conservative measures,

including local wound care and antibiotic therapy. The range of wound-related complications for open mesh repair varies from 3.5% to 18%, as reported in various studies, with an average incidence of 8.1% [20]. In our investigation, the incidence of seroma was determined to be 3.8%, a figure notably lower than the prevalence documented in the study by Shah *et al.*, [16].

Our study revealed a mean length of post-operative hospital stay for open ventral hernia repair at 4.42 days, which aligns with the findings reported by Shah *et al.*, [16]. Another similar study indicated a similar duration of 4.33 days for the open hernia repair group [20]. In contrast, A similar study reported a longer stay of 6.5 days for open hernia repair [17], while Badiger S *et al.*, [19], documented 6.8 days for the open repair group.

CONCLUSION

Our study demonstrates that onlay mesh repair with non-absorbable prosthetic mesh is an effective and safe surgical approach for ventral hernia repair. It offers reduced post-operative complications, shorter hospital stays, making it a promising option for this surgical intervention.

Acknowledgments

We extend our heartfelt gratitude to all the patients who participated in this study. We would also like to acknowledge the support and cooperation of the medical staff at Bangabandhu Sheikh Mujib Medical University, Dhaka, during the research period.

Funding: No funding sources

Conflict of Interest: None declared

REFERENCES

- Williams, N. S., Bulstrode, C. J., & o'Connell, P. R. (2008). Short practice of surgery. *Bailey and Love*.
- Chevreil, J. P., & Rath, A. M. (2000). Classification of incisional hernias of the abdominal wall. *Hernia*, 4, 7-11.
- Dubay, D. A., Wang, X., Kuhn, M. A., Robson, M. C., & Franz, M. G. (2004). The prevention of incisional hernia formation using a delayed-release polymer of basic fibroblast growth factor. *Annals of surgery*, 240(1), 179.
- Burger, P., van't Riet, M., & Jeekel, H. (2004). Incisional hernia prevention. In *Meshes: benefits and risks* (pp. 399-405). Berlin, Heidelberg: Springer Berlin Heidelberg.

5. Pratt, B. L., & Greene, F. L. (2000). Role of laparoscopy in the staging of malignant disease. *Surgical Clinics*, 80(4), 1111-1126.
6. Sauerland, S., Walgenbach, M., Habermalz, B., Seiler, C. M., & Miserez, M. (2011). Laparoscopic versus open surgical techniques for ventral or incisional hernia repair. *Cochrane database of systematic reviews*, (3).
7. Scott, J. R., Deeken, C. R., Martindale, R. G., & Rosen, M. J. (2016). Evaluation of a fully absorbable poly-4-hydroxybutyrate/absorbable barrier composite mesh in a porcine model of ventral hernia repair. *Surgical endoscopy*, 30, 3691-3701.
8. Byrd, J. F., Agee, N., Nguyen, P. H., Heath, J. J., Lau, K. N., McKillop, I. H., ... & Iannitti, D. A. (2011). Evaluation of composite mesh for ventral hernia repair. *JSLs: Journal of the Society of Laparoendoscopic Surgeons*, 15(3), 298.
9. Wéber, G., Baracs, J., & Horváth, O. P. (2010). "Onlay" mesh provides significantly better results than "sublay" reconstruction. Prospective randomized multicenter study of abdominal wall reconstruction with sutures only, or with surgical mesh--results of a five-years follow-up. *Magyar sebeszet*, 63(5), 302-311.
10. Raghuvveer, M. N., Muralidhar, S., Shetty, H., & Veena, V. (2018). Onlay versus sublay mesh repair for ventral hernia. *International Surgery Journal*, 5(3), 823-826.
11. Aurangzeb, M. (2004). Tension Free mesh Hernioplasty; a Review of 96 cases. *Journal of Postgraduate Medical Institute*, 18(1).
12. de Vries Reilingh, T. S., van Geldere, D., Langenhorst, B. L., de Jong, D., van der Wilt, G. J., van Goor, H., & Bleichrodt, R. P. (2004). Repair of large midline incisional hernias with polypropylene mesh: comparison of three operative techniques. *Hernia*, 8, 56-59.
13. Gray, S. H., Hawn, M. T., & Itani, K. M. (2008). Surgical progress in inguinal and ventral incisional hernia repair. *Surgical Clinics of North America*, 88(1), 17-26.
14. Forbes, S. S., Eskicioglu, C., McLeod, R. S., & Okrainec, A. (2009). Meta-analysis of randomized controlled trials comparing open and laparoscopic ventral and incisional hernia repair with mesh. *Journal of British Surgery*, 96(8), 851-858.
15. Ramshaw, B. J., Esartia, P., Schwab, J., Mason, E. M., Wilson, R. A., Duncan, T. D., ... & Promes, J. (1999). Comparison of laparoscopic and open ventral herniorrhaphy. *The American Surgeon*, 65(9), 827-832.
16. Shah, K., Jain, A., Gurjar, V., & Shah, A. (2021). Method of Ventral Hernia Repair: Our Experience. *Prof.(Dr) RK Sharma*, 21(1), 422.
17. Carbajo, M. A., Martin del Olmo, J. C., Blanco, J. I., De la Cuesta, C., Toledano, M., Martin, F., ... & Inglada, L. (1999). Laparoscopic treatment vs open surgery in the solution of major incisional and abdominal wall hernias with mesh. *Surgical endoscopy*, 13, 250-252.
18. Ramshaw, B. J., Esartia, P., Schwab, J., Mason, E. M., Wilson, R. A., Duncan, T. D., ... & Promes, J. (1999). Comparison of laparoscopic and open ventral herniorrhaphy. *The American Surgeon*, 65(9), 827-832.
19. Badiger, S., Koppad, S. N., Kulkarni, A., & Kodliwadmth, H. (2016). Comparative analysis of open versus laparoscopic ventral hernia repair. *International Surgery Journal*, 3(3), 1167-1172.
20. Qadri, S. J. F., Khan, M., Wani, S. N., Nazir, S. S., & Rather, A. (2010). Laparoscopic and open incisional hernia repair using polypropylene mesh-A comparative single centre study. *International Journal of Surgery*, 8(6), 479-483.