

Haematoma Block for Distal Radius Fracture Pain Management

Dr Varun Thusoo^{1*}, Dr Shilaga Dhar²

¹MS Orthopedics, AMCH Adesh Medical College

²MD Anesthesia, AMCH Adesh Medical College

DOI: [10.36347/sjams.2024.v12i03.006](https://doi.org/10.36347/sjams.2024.v12i03.006)

| Received: 18.12.2023 | Accepted: 25.01.2024 | Published: 11.03.2024

*Corresponding author: Dr Varun Thusoo

MS Orthopedics, AMCH Adesh Medical College

Abstract

Original Research Article

Introduction: HB (Hematoma Block) is a commonly utilized technique all over the world to relieve discomfort during the management of DRF (Distal Radius Fractures). In this approach, 10ml to 15ml of 2 percent lignocaine, a topical anesthetic is utilized to reduce discomfort during the fracture reduction process. **Materials & Methods:** In this study, we recruited fifty individuals between January and December of 2023. Every patient had a distal radius extra-articular fracture that required percutaneous pinning or plaster casting. HB using 12 to 15 ml of 2% lignocaine was administered to the patients for hematomas at the fracture site. Using the Visual Analogue Scale method, the patient's pain distribution and severity were measured before, during, and after the decrease. **Findings:** Before the HB, the average VAS (Visual Analogue Scale) score was 9.5. Less than two hours after the surgery and during reduction, the average VAS score dropped to 2.5 (range between 0.5 to 3.5). A scale of 0 to 10 cm is used to define the VAS scoring system. **Conclusion:** We found that HB is a safe and efficient technique of anesthetic in DRF where manipulation or reduction is necessary for pinning or casting.

Keywords: Visual analogue scale (VAS), 2% lignocaine, hematoma block, distal radius fractures.

Copyright © 2024 The Author(s): This is an open-access article distributed under the terms of the Creative Commons Attribution 4.0 International License (CC BY-NC 4.0) which permits unrestricted use, distribution, and reproduction in any medium for non-commercial use provided the original author and source are credited.

BACKGROUND

Distal Radius manipulation is often done in the casualty room. Numerous anesthetic procedures, including HB, nerve block, general anesthesia, and Bier block (intravenous block) are utilized to execute this operation [1, 2]. Despite several studies demonstrating HB's comparatively poor analgesic effectiveness, its popularity has grown over time because of its simplicity and safety [3]. A small amount of lidocaine and only partial solution dispersion within the fracture site may be the cause of HB's poor effectiveness. Consequently, the analgesic effect of injecting a larger amount of lidocaine solution to the hematoma may be enhanced. A standard dose for HB is 10ml of 2 percent lidocaine [3,4].

In A&Es, transcutaneous injection of local anesthetic (also recognized as an HB) is generally utilized as a substitute for labor-intensive and time-consuming general anesthesia during closed reduction procedures. Although they are commonly utilized to lessen pain during closed reductions of DRF some emergency care experts are still reluctant to employ HBs. The internal fracture environment and the outside world are connected via the needle applied to inject the local anaesthetic, which theoretically increases the infection risk at the fracture site [6-8].

Seizures and osteomyelitis have been linked to HBs in certain studies [9-11], while other research has not been able to corroborate these side effects [5,12,13].

PATIENTS AND METHODS

Patients and Procedure

From January 2023 to December 2023, this prospective, randomized, controlled experiment was carried out at our medical center's casualty room.

Patients with displaced and undisplaced distal radial fractures needing manipulation who were 20 years of age or older met the *inclusion criteria*.

Patients who were ineligible for general anesthetic due to previous injuries had a documented allergy to lidocaine or were pregnant met the *exclusion criteria*. Adesh Medical College approved the study. For every patient, informed consent was acquired.

Procedure: Blood collects around fractured bones due to displacement fractures, resulting in the formation of hematomas. Using an HB to anesthetize the surrounding nerves of the injury facilitates painless manipulation of the bones during reduction. Using this to its advantage, HB turns out to be a painless method of numbing DRF.

To identify the injection site, we first recruited the patients in accordance with the inclusion criteria and examined their radiographs. Using a sterile 18 gz needle and a 20 ml syringe, we prepared and draped the limb in the operating room and extracted around 1ml of 2 percent lignocaine from the bulb. Angulating the syringe in accordance with the fracture pattern, we injected the lignocaine into portions of the dorsolateral and dorsomedial sides of the fracture site. Under fluoroscopic imaging, we were able to confirm the needle's location in every instance. We aspirated after injecting largely to see if we were inside the hematoma. This was verified by the syringe filling with brand-new, crimson blood. Subsequently, we began injecting the 2 percent lignocaine into the subcutaneous tissue and withdrew the needle gradually. In each instance, we collectively injected between 12 and 18 ml of lignocaine from the two locations indicated. Following about fifteen minutes of waiting, we used the VAS to measure the pain at the fracture site. If we discovered moderate to severe discomfort, we reinjected 5 ml of 2% lignocaine into the affected area. Following the waiting interval and enhancement in the VAS score, we started to progressively manage and minimize the fracture. It was decided to accept the decrease. Kirschner's wires were placed before casting to maintain the fracture in place or a "plaster of Paris" cast was used if the fracture was

determined to be stable after reduction. A technique for administering HB is shown in Figure 1.

Statistical Analysis

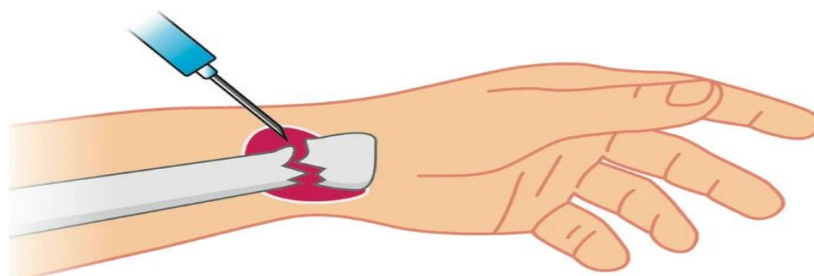
A 5% significance level was applied when comparing the 2 groups with "Mann-Whitney U" test. SAS 9.4 was applied to conduct the statistical analysis.

RESULTS

The VAS score was used to evaluate each patient before induction, throughout reduction, and one hour following the treatment. Before HB, patients' average VAS scores were 9.5. the mean VAS score dropped to 2.5 (range between 0.5-3.5) during reduction and less than two hours following the treatment. A scale of 0 to 10 cm is used to define the VAS scoring system. It has been suggested that the pain scale's cut-off points be as follows: no pain (0mm to 4mm), mild pain (0.5 cm to 4.4 cm), moderate pain (4.5 cm to 7.4cm), as well as severe pain (7.5 cm to 10.0 cm). These suggestions depend on the distribution of pain VAS ratings on the basis of patients who reported pain as none, mild, moderate, or severe. The VAS scores of the patients before, during, as well as following fracture reduction are displayed in Table 2.

Table 1: VAS score in our series

| VAS Score | Number of patients | | |
|-----------|-------------------------|------------------|-----------------|
| | 10 min before reduction | During Reduction | After Reduction |
| 0 | 0 | 6 | 29 |
| 1 | 0 | 20 | 9 |
| 2 | 0 | 7 | 4 |
| 3 | 0 | 5 | 0 |
| 4 | 0 | 4 | 0 |
| 5 | 6 | 0 | 0 |
| 6 | 5 | 0 | 1 |
| 7 | 13 | 0 | 0 |
| 8 | 12 | 0 | 0 |
| 9 | 4 | 0 | 0 |
| 10 | 0 | 0 | 0 |



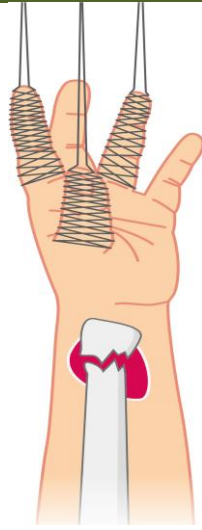


Figure:1 Haematoma Block Over Fracture Site

DISCUSSION

HB is a general anesthesia technique used to treat displaced DRF. In HB, the fracture site is punctured

with a needle, local anesthesia is given, and the hematoma is aspirated to verify the location. (Figure 2).

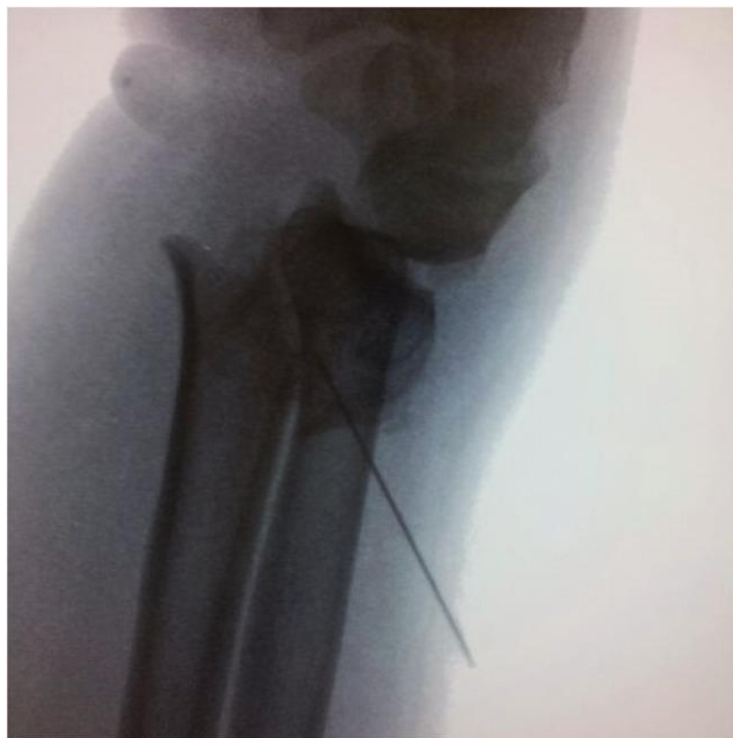

Figure 2: HB's X-ray indicates a fracture of the distal radius

Many analyses have demonstrated that HB has a poor analgesic impact in comparison to other techniques including Bier block (intravenous regional block), general anesthesia, as well as regional nerve block. Therefore, it is unclear, if HB has a less effective analgesic effect. A meta-analysis published in Handoll *et al.*, [17] comprised 20 trials involving 1500 patients about various anesthetic techniques for manipulating fractures of the displaced distal radius. They found that there was specific evidence suggesting HB had a less

effective analgesic impact as compared to other techniques. Nonetheless, HB has been recommended by several studies as the preferred course of therapy because of its ease of use and safety [4,8,15].

Because of its accessibility and ease of application, HB is the procedure of choice at our institute for managing displaced DRFs. Our patients unfortunately experience discomfort with this surgery. The optimal solution for HB was determined by a

literature review, using 10mL of either 1 or 2 percent lidocaine [1, 2]. We supposed that a larger volume of solution administered into the fracture hematoma would enable the analgesic material to be distributed more evenly throughout the fracture site. Additionally, because the dosage of lidocaine is the same, this increase may enhance the analgesic efficacy without increasing the risk of new problems. Younge⁸ documented that after receiving HB for the treatment of a displaced DRF, eight patients had forearm compartment syndrome. According to this source, adding more fluid for HB may cause compartment syndrome to worsen. Every patient in our research had follow-up care in the CD for about an hour, during which time the outcomes were recorded. It is important to take lidocaine's cardiotoxicity into account. In contrast, Meinig *et al.*, [18] demonstrated that plasma lidocaine concentrations remained well below the lethal threshold following HB for distal radius fracture manipulation at dosages ranging from 2.2 to 2.4 mg/kg. No problems were documented in any of the participants included in our research.

Once HB is administered, there is a noticeable decrease in the VAS score. In line with Gaur *et al.*, the score of VAS decreased from an average of 9.5 to 2.5. Thus, it is evident that the HB approach significantly reduces discomfort and makes it easier to treat DRF. Fanjalalaina *et al.*, [14], and Johnson *et al.*, [15] showed that HB is a protected approach with a very low risk of infection in their respective examinations of 40, 132, and 50 patients.

CONCLUSION

We found that the HB technique is a smooth, safe, and efficient way to provide anesthesia for DRF. It is less complicated and takes less time compared to regional brachial plexus block or "intravenous sedation" approaches. It may be completed quickly and with equivalent benefit with fewer professionals attending to the patient.

REFERENCES

1. Graham, C. A., Gibson, A. J., Goutcher, C. M., & Scollon, D. (1997). Anaesthesia for the management of distal radius fractures in adults in Scottish hospitals. *European Journal of Emergency Medicine*, 4(4), 210-212.
2. White, J. S. (2013). Fractures of the distal radius. *Advanced Emergency Nursing Journal*, 35(1), 8-15.
3. Ogunlade, S. O., Omololu, A. B., Alonge, T. O., Salawu, S. A., & Bamgboye, E. A. (2002). Haematoma block in reduction of distal radial fractures. *West African journal of medicine*, 21(4), 282-285.
4. Myderrizi, N., & Mema, B. (2011). The hematoma block an effective alternative for fracture reduction

- in distal radius fractures. *Medical Archives*, 65(4), 239.
5. Koren, L., Ginesin, E., Elias, S., Wollstein, R., & Israelit, S. (2018). The radiographic quality of distal radius fracture reduction using sedation versus hematoma block. *Plastic surgery*, 26(2), 99-103.
6. Kendall, J. M., Allen, P. E., & McCabe, S. E. (1995). A tide of change in the management of an old fracture?. *Journal of accident & emergency medicine*, 12(3), 187.
7. Case, R. D. (1985). Haematoma block—a safe method of reducing Colles' fractures. *Injury*, 16(7), 469-470.
8. Funk, L. (1997). A prospective trial to compare three anaesthetic techniques used for the reduction of fractures of the distal radius. *Injury*, 28(3), 209-212.
9. Basu, A., Bhalaiik, V., Stanislas, M., & Harvey, I. A. (2003). Osteomyelitis following a haematoma block. *Injury*, 34(1), 79-82.
10. Dezfuli, B., Edwards, C. J., & DeSilva, G. L. (2012). Distal radius fracture hematoma block with combined lidocaine and bupivacaine can induce seizures while within therapeutic window: a case report. *Journal of orthopaedic case reports*, 2(4), 10.
11. Dorf, E., Kuntz, A. F., Kelsey, J., & Holstege, C. P. (2006). Lidocaine-induced altered mental status and seizure after hematoma block. *The Journal of emergency medicine*, 31(3), 251-253.
12. Tabrizi, A., Tolouei, F. M., Hassani, E., Taleb, H., & Elmi, A. (2017). Hematoma block versus general anesthesia in distal radius fractures in patients over 60 years in trauma emergency. *Anesthesiology and pain medicine*, 7(1).
13. Gaur, T. N. S., & Kachhawah, V. (2017). Reduction of Distal Radius Fractures under Haematoma Block. *Biomedical Journal of Scientific & Technical Research*, 1(6), 1780-1782.
14. Fanjalalaina, R. M., Tiana, R., & Claude, R. H. J. (2016). Percutaneous Pinning of Distal Radius Fractures Using Hematoma Block: Outcomes in Our Center. *Open Journal of Orthopedics and Rheumatology*, 1(1), 001-003.
15. Johnson, P. Q., & Noffsinger, M. A. (1991). Hematoma block of distal forearm fractures. Is it safe?. *Orthopaedic review*, 20(11), 977-979.
16. Funk, L. (1997). A prospective trial to compare three anaesthetic techniques used for the reduction of fractures of the distal radius. *Injury*, 28(3), 209-212.
17. Handoll, H. H., Madhok, R., Dodds, C., & Cochrane Bone, Joint and Muscle Trauma Group. (1996). Anaesthesia for treating distal radial fracture in adults. *Cochrane Database of Systematic Reviews*, 2010(1).
18. Meinig, R. P., & Lobmeyer, A. Q. L. (1989). Plasma lidocaine levels following hematoma block for distal radius fractures. *Journal of orthopaedic trauma*, 3(3), 187-191.