

Imaging Patterns of Breast Cancer in Women of Reproductive Age

Dr. Ziaul Haq Bhuiyan^{1*}, Dr. Farhan Matin², Prof. Dr. Salma Sultana³, Prof. Dr. Shamima Haque Chowdhury⁴, Dr. Mir Afsary Wahed⁵

¹Associate Professor, Department of Radiology and Imaging, Uttara Adhunik Medical College, Dhaka, Bangladesh

²Assistant Professor, Department of Radiology and Imaging, Uttara Adhunik Medical College, Dhaka, Bangladesh

³Professor and Head, Department of Surgery, Dhaka Medical College, Dhaka, Bangladesh

⁴Professor and Head, Department of Gynecology and Obstetrics, Uttara Adhunik Medical College, Dhaka, Bangladesh

⁵Assistant Professor, Department of Dental Anatomy, Dhaka Dental College, Dhaka, Bangladesh

DOI: [10.36347/sjams.2024.v12i04.024](https://doi.org/10.36347/sjams.2024.v12i04.024)

| Received: 09.03.2024 | Accepted: 08.04.2024 | Published: 26.04.2024

*Corresponding author: Dr. Ziaul Haq Bhuiyan

Associate Professor, Department of Radiology and Imaging, Uttara Adhunik Medical College, Dhaka, Bangladesh

Email: drzia_rad@yahoo.com

Abstract

Original Research Article

Background: While breast cancer is less common in younger women compared to older age groups, it can still occur, necessitating careful evaluation of imaging findings. Imaging patterns of breast cancer in women of reproductive age can vary, presenting unique challenges in diagnosis and management. This study aimed to assess the imaging patterns of breast cancer in women of reproductive age. **Methods:** This prospective observational study was conducted in the Department of Radiology and Imaging Uttara Adhunik Medical College Dhaka, Bangladesh from January 2019 to December 2023. In this study, 67 women of reproductive age who had been diagnosed with breast carcinoma and had undergone preoperative breast imaging were enrolled purposively. Data analysis was conducted using MS Office tools. **Results:** Mammographic findings: 42% had heterogeneously dense breasts, 30% scattered composition; and 87% had high mass density. Irregular mass shape: 43% (mammography), 69% (ultrasonography). In total 85% of cases were pleomorphic. Ultrasonography evaluation: 69% had a single US background. Echogenicity distribution: 61% hypoechoic among patients. MRI findings: 37% mild, 31% moderate, 22% minimal. Besides, 87% showed heterogeneous mass enhancement; 63% had segmental non-mass distribution. **Conclusion:** In breast cancer cases, imaging findings often include masses exhibiting suspicious features such as irregular shape and spiculated margins on mammograms, and irregular shape with angular margins on ultrasound. MRI features commonly involve masses with irregular shapes and heterogeneous enhancement.

Keywords: Imaging patterns, Breast cancer, Reproductive age, Ultrasonography, Mammographic features.

Copyright © 2024 The Author(s): This is an open-access article distributed under the terms of the Creative Commons Attribution 4.0 International License (CC BY-NC 4.0) which permits unrestricted use, distribution, and reproduction in any medium for non-commercial use provided the original author and source are credited.

INTRODUCTION

Globally, breast cancer is the most prevalent cancer and the primary cause of cancer-related mortality among women, representing 23% of all new cancer cases and 14% of all cancer deaths. It is noteworthy that approximately 7% to 9% of all breast cancer cases occur in women under 40 years of age, with less than 4% diagnosed in women under 35 [1]. Moreover, breast cancer in young females constitutes more than 10% of cancers diagnosed in Asian countries [2]. Breast cancer in young females typically exhibits biological characteristics suggesting a more aggressive tumor profile, such as advanced tumor stage, aggressive subtypes, and higher histological grades compared to older women. These features are associated with an elevated risk of mortality [2,3]. Additionally, breast cancer in young women is more frequently linked to family history and genetic mutations, including BRCA

mutations, compared to older breast cancer patients [4]. Furthermore, young women diagnosed with breast cancer experience higher rates of local recurrence following either breast-conserving surgery or mastectomy when compared to older women [5]. Several studies have highlighted that breast cancer patients under 40 years of age often face delayed diagnoses, potentially linked to the more advanced stage presentations observed in this age group [6,7]. Additionally, there is speculation that limited access to cancer surveillance programs may contribute to delayed diagnosis, although this viewpoint remains debated [8]. Furthermore, numerous studies have documented a rise in the proportion of breast tumors exhibiting hormone receptor (HR) negativity and overexpression of human epidermal growth factor receptor 2 (HER2) in young women [9]. In general, young women are most commonly diagnosed with HR-positive/HER2-negative breast cancer, followed by triple-negative (TN) tumors, which lack

expression of estrogen receptor (ER), progesterone receptor (PR), and HER2. This is then followed by HR-positive/HER2-enriched tumors, and lastly, HR-negative/HER2-enriched subtypes [10]. Poorer treatment outcomes in breast cancer among young Korean patients may be attributed to the increased frequency of TN/HER2-enriched subtypes, as well as the more aggressive clinical behavior of HR-positive tumors compared to those observed in older patients [10]. Mammography faces limitations in detecting lesions in young women due to the presence of dense breast tissue, which is commonly associated with younger age and premenopausal status [11]. Consequently, relying solely on mammography for screening purposes has shown limited benefits in the young age population [12]. The objective of this study was to assess the imaging patterns of breast cancer in women of reproductive age.

METHODOLOGY

This was a prospective observational study that was conducted in the Department of Radiology and Imaging Uttara Adhunik Medical College Dhaka, Bangladesh from January 2019 to December 2023. In this study, 67 women of reproductive age who had been diagnosed with breast carcinoma and had undergone preoperative breast imaging were enrolled. A convenient purposive sampling technique was used in sample selection. Properly written consent was obtained from all participants before data collection. The inclusion criteria for this study included female patients under the age of 40 with biopsy-confirmed invasive lobular or ductal carcinoma of primary epithelial tumors. Conversely, individuals with incomplete pathological and radiological data, as well as those who underwent treatment outside the designated facility, were excluded based on the study's exclusion criteria. All participants underwent mammographic, ultrasonographic, and MRI evaluations, with the respective data systematically recorded and assessed. Additionally, all demographic and clinical information of the participants was meticulously documented. Data analysis was conducted using MS Office tools.

RESULT

Among our total participants, nearly half (48%) were from the 35-40 years' age group, followed by 36% from the 30-34 years' age group. The most common clinical symptom was lumps, reported by 80% of patients. Regarding histology, more than half (67%) had invasive ductal carcinoma and ductal carcinoma in situ (IDC and DCIS). Nearly half of the patients (50%) had grade II histological grade. The luminal A subtype was predominant, with 43% of patients having this subtype. A positive family history of breast cancer was reported in 18% of cases. Distant metastasis was observed in only 3% of cases. In the evaluation of mammographic features, the highest number of patients (42%) had heterogeneously dense breast composition, followed by 30% with scattered composition. Mass density was high in the majority of cases (87%). The irregular shape was the most common mass shape, observed in 43% of patients. Speculated mass margin was predominant, reported in 36% of cases. Pleomorphic microcalcifications were observed in the majority of patients (85%). In the evaluation of ultrasonography features, it was observed that more than two-thirds of the patients (69%) had a single US background. The irregular mass shape was predominant, observed in nearly two-thirds of the patients (69%). Regarding mass margin, 36% had micro-lobulated margins, followed by 33% with angulated margins, 22% with speculated margins, 9% with indistinct margins, and 9% with circumscribed margins. Based on echogenicity distribution, more than half of the patients (61%) were hypoechoic. In the current study, in the evaluation of magnetic resonance imaging (MRI) features, mild findings were observed in more than one-third of patients (37%), while 31% and 22% of cases showed moderate and minimal findings, respectively. Heterogeneous MRI mass enhancement was observed in the majority of patients (87%). Regarding T2 signal intensity, it was hypointense, isointense, and hyperintense in 25%, 53%, and 22% of the participants, respectively. Based on the non-mass distribution, the majority of patients (63%) showed segmental distribution. Regarding non-mass enhancement, the highest number of patients (42%) exhibited clumped enhancement, while 33%, 19%, and 6% of cases showed heterogeneous, clustered ring, and homogeneous enhancement, respectively.

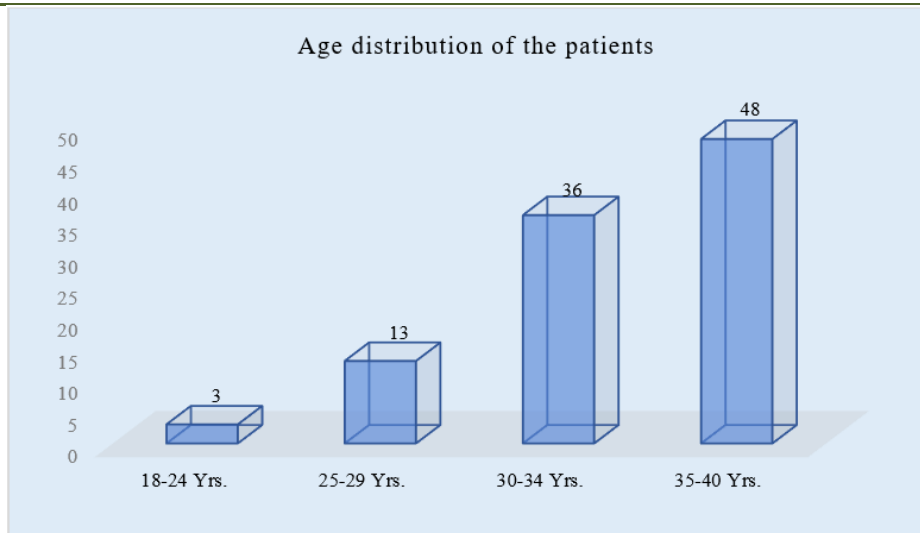


Figure I: column chart showed age wise patients distribution (N=67)

Table 1: Clinical status distribution (N=67)

Clinical findings	n	%
Clinical symptom		
Negative	10	15%
Lump	53	80%
Discharge	3	4%
Lump with discharge	1	1%
Histology		
IDC	8	12%
IDC+DCIS	45	68%
DCIS	9	13%
ILC	1	1%
Others	4	6%
Histological grade		
I	8	12%
II	31	46%
III	28	42%
Molecular subtype		
Luminal A	29	44%
Luminal B	15	22%
HER2+	7	10%
Triple-negative	16	24%
Family history of breast cancer		
No	55	82%
Yes	12	18%
Distant metastasis		
No	65	97%
Yes	2	3%

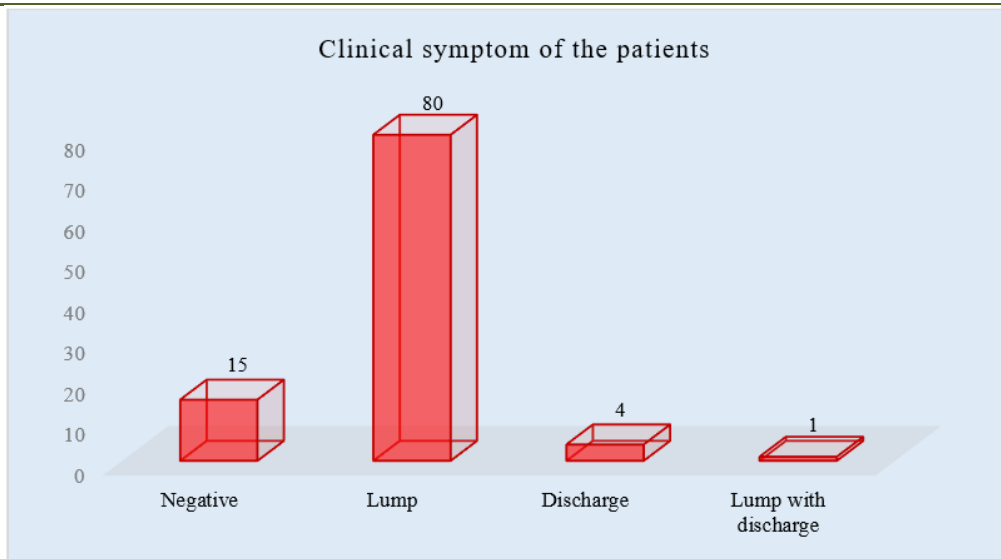


Figure II: column chart showed clinical symptom wise patients (N=67)

Table 2: Mammographic features (N=67)

Features	n	%
Breast composition		
Fatty	6	9%
Scattered	20	30%
Heterogeneous dense	29	43%
Extremely dense	12	18%
Mass density		
Equal	9	13%
High	58	87%
Mass shape		
Oval	9	13%
Round	12	18%
Irregular	29	44%
Normal	17	25%
Mass margin		
Circumscribed	6	8%
Obscured	5	7%
Micro-lobulated	4	5%
Indistinct	9	12%
Speculated	27	36%
Undefined	16	21%
Micro-calcifications		
Amorphous	2	3%
Punctate	1	1%
Pleomorphic	57	86%
Coarse heterogeneous	5	7%
Linear branching	2	3%

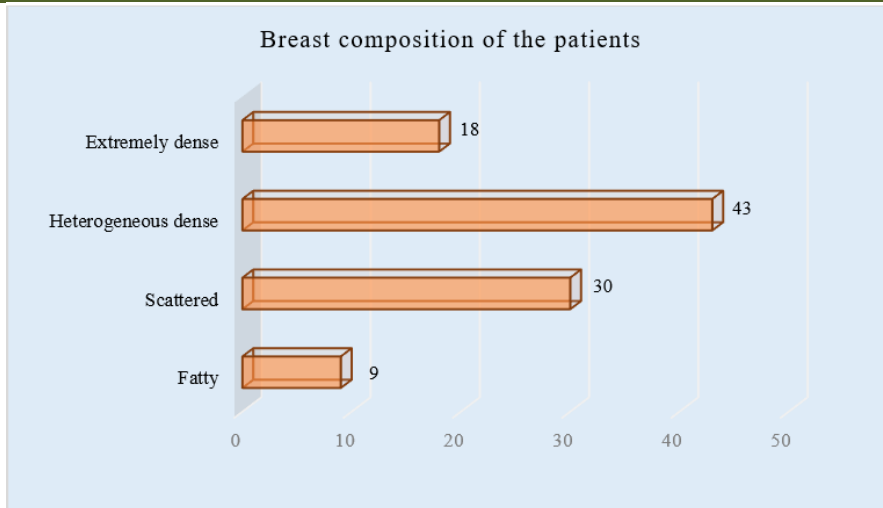


Figure III: Bar chart showed breast composition wise patients (N=67)

Table 3: Ultrasonographic features (N=67)

Features	n	%
US Background		
Multi-centric	12	18%
Multifocal	9	13%
Single	46	69%
Mass shape		
Oval	20	30%
Round	1	1%
Irregular	46	69%
Mass margin		
Circumscribed	6	9%
Micro-lobulated and angulated	24	36%
Indistinct	15	22%
Speculated	22	33%
Echogenicity		
Isoechoic	1	1%
Hypo echoic	41	62%
Complex	5	7%
Heterogeneous	20	30%

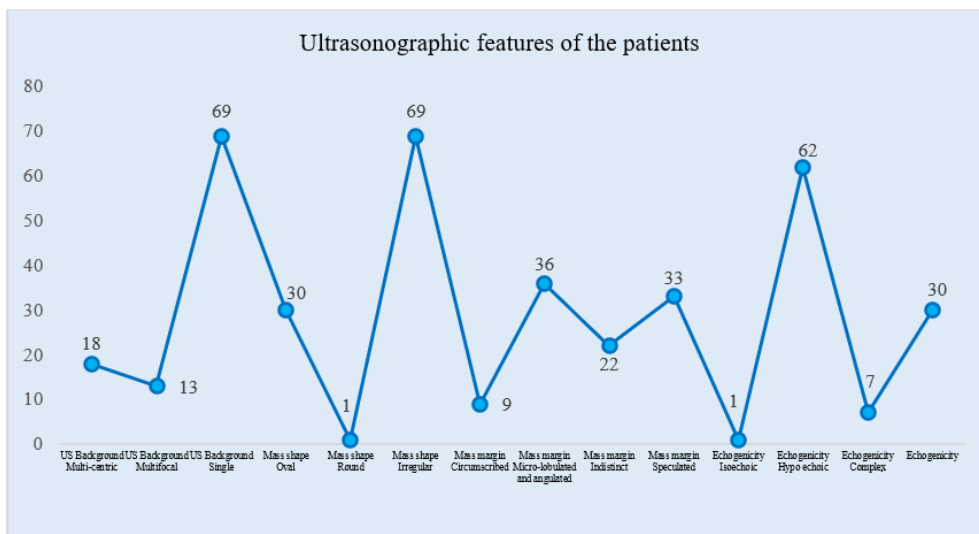


Figure IV: Line chart showed ultrasonographic features wise patients (N=67)

Table 4: MRI features (N=67)

MRI features	n	%
MRI findings		
Minimal	15	22%
Mild	25	37%
Moderate	21	31%
Marked	5	7%
MRI mass enhancement		
Homogenous	2	3%
Heterogeneous	58	87%
Rim	7	10%
T2 signal intensity		
Hypointense	17	25%
Isointense	35	53%
Hyperintense	15	22%
Kinetic curve		
Type I	2	3%
Type II	19	28%
Type I	46	69%
Non-mass distribution		
Linear	4	6%
Segmental	42	63%
Regional	10	15%
Diffuse	11	16%
Non-mass enhancement		
Homogenous	4	6%
Heterogenous	22	33%
Clumped	28	42%
Clustered rings	13	19%

DISCUSSION

This study aimed to assess the imaging patterns of breast cancer in women of reproductive age. In this study, approximately half of the participants (48%) belonged to the 35-40 years' age group, followed by 36% from the 30-34 years' age group. These findings are consistent with those of another study [13]. Histologically, nearly half of the patients had grade II tumors. In terms of molecular subtype, 44% of the patients were classified as having the luminal A subtype. Regarding family history of breast cancer, 18% of cases reported a positive family history. Only 3% of cases were positive for distant metastasis. Several studies have indicated that variations in molecular and biological subtypes of breast cancer may differ by race across different age groups. Collins *et al.*, [14] reported in their study that the luminal B subtype is the most prevalent (35%) among young breast cancer patients compared to the general population. Conversely, another study found that the luminal A subtype was the most common in young breast cancer patients [15]. According to our mammographic evaluation, 42% of participants exhibited heterogeneously dense breasts, while 30% had scattered composition, and 87% showed high mass density. Regarding irregular mass shape, 44% of cases were observed to have this characteristic in mammography. Notably, 86% of cases were pleomorphic. A study by [16] suggested that a high

amount of fibro-glandular tissue leading to dense mammographic composition may impact disease detection. Our mammographic findings were consistent with those of other recent studies [17,18]. Our evaluation of ultrasonography features revealed that more than two-thirds of the patients (69%) exhibited a single US background. Concerning mass shape, nearly two-thirds of the patients (69%) displayed irregular shapes. Regarding mass margin, the distribution was as follows: 36% had micro-lobulated margins, 33% had angulated margins, 22% had speculated margins, 9% had indistinct margins, and only 9% had circumscribed margins. Based on echogenicity distribution, more than half of the patients (62%) were found to be hypoechoic. An *et al.*, emphasized the importance of carefully examining margins, particularly in oval-shaped masses, as this can reduce the likelihood of misinterpreting masses as benign lesions [17]. Our MRI findings revealed that 37% of cases exhibited mild enhancement, 31% had moderate enhancement, and 22% had minimal enhancement. Furthermore, 87% of cases showed heterogeneous mass enhancement, while 63% exhibited segmental non-mass distribution. These MRI findings were largely consistent with those of other studies [19,20]. The findings of this current study may provide valuable insights for future research in similar contexts.

LIMITATION OF THE STUDY

This study was conducted at a single center with a relatively small sample size and within a short timeframe. Therefore, the findings may not accurately represent the entire country's scenario. It's important to interpret the results within the context of these limitations and exercise caution when generalizing the findings to broader populations.

CONCLUSION

In breast cancer cases, imaging findings frequently reveal masses with suspicious features across various modalities. Mammograms often depict masses with irregular shapes and spiculated margins, raising concerns for malignancy. Similarly, ultrasound imaging may reveal masses with irregular shapes and angular margins, further indicating potential malignancy. Additionally, MRI findings commonly include masses exhibiting irregular shapes and heterogeneous enhancement patterns, adding to the suspicion of breast cancer. These imaging characteristics play a crucial role in the early detection and diagnosis of breast cancer, guiding subsequent management decisions and facilitating timely interventions to improve patient outcomes.

REFERENCES

- Jemal, A., Clegg, L. X., Ward, E., Ries, L. A., Wu, X., Jamison, P. M., ... & Edwards, B. K. (2004). Annual report to the nation on the status of cancer, 1975–2001, with a special feature regarding survival. *Cancer: Interdisciplinary International Journal of the American Cancer Society*, 101(1), 3-27.
- Ahn, S. H., Son, B. H., Kim, S. W., Kim, S. I., Jeong, J., Ko, S. S., & Han, W. (2007). Poor outcome of hormone receptor-positive breast cancer at very young age is due to tamoxifen resistance: nationwide survival data in Korea—a report from the Korean Breast Cancer Society. *Journal of Clinical Oncology*, 25(17), 2360-2368.
- Fredholm, H., Eaker, S., Frisell, J., Holmberg, L., Fredriksson, I., & Lindman, H. (2009). Breast cancer in young women: poor survival despite intensive treatment. *PloS one*, 4(11), e7695.
- Group, A. B. C. S. (2000). Prevalence and penetrance of BRCA1 and BRCA2 mutations in a population-based series of breast cancer cases. *British Journal of Cancer*, 83(10), 1301.
- Zhou, P., & Recht, A. (2004). Young age and outcome for women with early-stage invasive breast carcinoma. *Cancer: Interdisciplinary International Journal of the American Cancer Society*, 101(6), 1264-1274.
- Neal, R. D., & Allgar, V. L. (2005). Sociodemographic factors and delays in the diagnosis of six cancers: analysis of data from the 'National Survey of NHS Patients: Cancer'. *British journal of cancer*, 92(11), 1971-1975.
- Partridge, A. H., Hughes, M. E., Ottesen, R. A., Wong, Y. N., Edge, S. B., Theriault, R. L., ... & Tamimi, R. M. (2012). The effect of age on delay in diagnosis and stage of breast cancer. *The Oncologist*, 17(6), 775-782.
- Ruddy, K. J., Gelber, S., Tamimi, R. M., Schapira, L., Come, S. E., Meyer, M. E., ... & Partridge, A. H. (2014). Breast cancer presentation and diagnostic delays in young women. *Cancer*, 120(1), 20-25.
- Keegan, T. H., DeRouen, M. C., Press, D. J., Kurian, A. W., & Clarke, C. A. (2012). Occurrence of breast cancer subtypes in adolescent and young adult women. *Breast Cancer Research*, 14, 1-9.
- Park, Y. H., Lee, S. J., Jung, H. A., Kim, S. M., Kim, M. J., Kil, W. H., ... & Im, Y. H. (2015). Prevalence and clinical outcomes of young breast cancer (YBC) patients according to intrinsic breast cancer subtypes: Single institutional experience in Korea. *The Breast*, 24(3), 213-217.
- Destounis, S., & Santacroce, A. (2018). Age to begin and intervals for breast cancer screening: balancing benefits and harms. *American Journal of Roentgenology*, 210(2), 279-284.
- Gabriel, C. A., & Domchek, S. M. (2010). Breast cancer in young women. *Breast cancer research*, 12(5), 212.
- Alhaidary, A. A., Al-Qudimat, A. R., Arabi, H., & Al-Zoubi, R. M. (2024). Imaging Patterns in Breast Cancer for Women Under 40 Years: A Descriptive Cohort Study. *Journal of Epidemiology and Global Health*, 1-9.
- Collins, L. C., Marotti, J. D., Gelber, S., Cole, K., Ruddy, K., Kereakoglow, S., ... & Partridge, A. H. (2012). Pathologic features and molecular phenotype by patient age in a large cohort of young women with breast cancer. *Breast cancer research and treatment*, 131, 1061-1066.
- Tang, J., Wu, C. C., Xie, Z. M., Luo, R. Z., & Yang, M. T. (2011). Comparison of clinical features and treatment outcome of breast cancers in young and elderly Chinese patients. *Breast care*, 6(6), 435-440.
- Destounis, S., & Santacroce, A. (2018). Age to begin and intervals for breast cancer screening: balancing benefits and harms. *American Journal of Roentgenology*, 210(2), 279-284.
- An, Y. Y., Kim, S. H., Kang, B. J., Park, C. S., Jung, N. Y., & Kim, J. Y. (2015). Breast cancer in very young women (< 30 years): Correlation of imaging features with clinicopathological features and immunohistochemical subtypes. *European journal of radiology*, 84(10), 1894-1902.
- Fredholm, H., Magnusson, K., Lindström, L. S., Garmo, H., Fält, S. E., Lindman, H., ... & Fredriksson, I. (2016). Long-term outcome in young women with breast cancer: a population-based study. *Breast cancer research and treatment*, 160, 131-143.

19. Kheirelseid, E. A., Boggs, J. M., Curran, C., Glynn, R. W., Dooley, C., Sweeney, K. J., & Kerin, M. J. (2011). Younger age as a prognostic indicator in breast cancer: a cohort study. *BMC cancer*, *11*, 1-7.
20. Durando, M., Mariscotti, G., Bosco, D., Caramia, E., Ruggieri, C., Regini, E., ... & Gandini, G. (2013, March). Breast cancer in women under 35 years old: clinical, radiological, ultrasound and MRI findings correlated to pathological-biological factors. European Congress of Radiology-ECR 2013.