

## Sphenoid Sinus Brown Tumor of Secondary Hyperparathyroidism: Case Report

Sofia Faiz<sup>1\*</sup>, S. Naimi<sup>1</sup>, Y. Bouktib<sup>1</sup>, A. Elhajjami<sup>1</sup>, B. Boutakioute<sup>1</sup>, M. Ouali<sup>1</sup>, N. Idrissi<sup>1</sup><sup>1</sup>Service of Radiology, Hospital Arrazi, University Hospital Med VI of MarrakechDOI: [10.36347/sajp.2024.v13i04.003](https://doi.org/10.36347/sajp.2024.v13i04.003)

| Received: 07.02.2024 | Accepted: 11.03.2024 | Published: 27.04.2024

\*Corresponding author: Sofia Faiz

Service of Radiology, Hospital Arrazi, University Hospital Med VI of Marrakech

### Abstract

### Case Report

We present a case of brown tumor of the sphenoid sinus in a patient with secondary hyperparathyroidism. CT showed an expansile soft-tissue attenuation mass centered in the sphenoid sinus. CT at bone window setting demonstrated expansile, lytic change and remodeling of the surrounding bone. On MR imaging, the lesion showed iso-intensity to gray matter on T1-weighted images and heterogeneous hyperintensity on T2-weighted images, and showed intense enhancement. The extent of the lesion and its relationship to the surrounding structures were best evaluated by CT and MR imaging.

**Keywords:** brown tumor, sphenoid sinus, hyperparathyroidism, heterogeneous hyperintensity.

Copyright © 2024 The Author(s): This is an open-access article distributed under the terms of the Creative Commons Attribution 4.0 International License (CC BY-NC 4.0) which permits unrestricted use, distribution, and reproduction in any medium for non-commercial use provided the original author and source are credited.

## INTRODUCTION

The brown tumor is a rare benign osteolytic lesion resulting from an abnormality of bone metabolism associated with hyperparathyroidism (HPT), which may affect the bones of the face and base of the skull.

HPT is a frequent endocrine disorder (3rd most common endocrine pathology), characterized by hypersecretion of parathyroid hormone (PH).

A distinction is made between primary HPT due to a disorder of the parathyroid glands, and secondary HPT due to non-parathyroid disorders, inducing chronic hypersecretion of PH and tertiary due to autonomous parathyroid hormone secretion in patients with long-standing secondary HPT.

The brown tumor is one of the clinical manifestations of this hyperparathyroidism and presents specific radiological and histological features, enabling the diagnosis diagnosis and management.

## CASE REPORT

A 42-year-old woman consulted for assessment and management of a 3-month history of bitemporal hemianopsia and diplopia, associated with fatigue, generalized weakness, and somnolence. She had a past medical history of hypertension, nephrolithiasis, and chronic constipation. As an initial method of evaluation an enhanced computed tomography of skull was performed and it revealed an expansive mass lesion (51x35x33mm) in the sphenoid sinus with erosion of the sellar floor and posterior medial wall of the orbit causing compression of the optic (Figure 1).

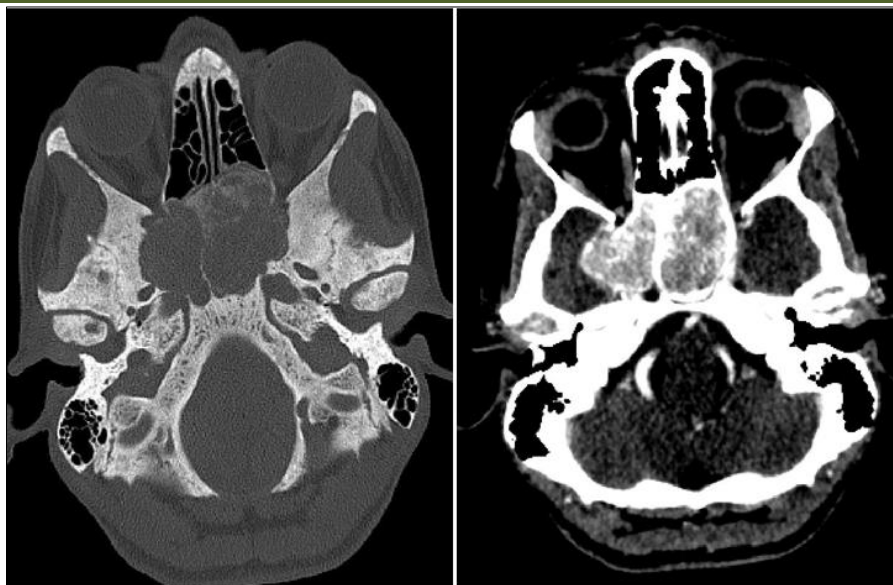

Fig 1

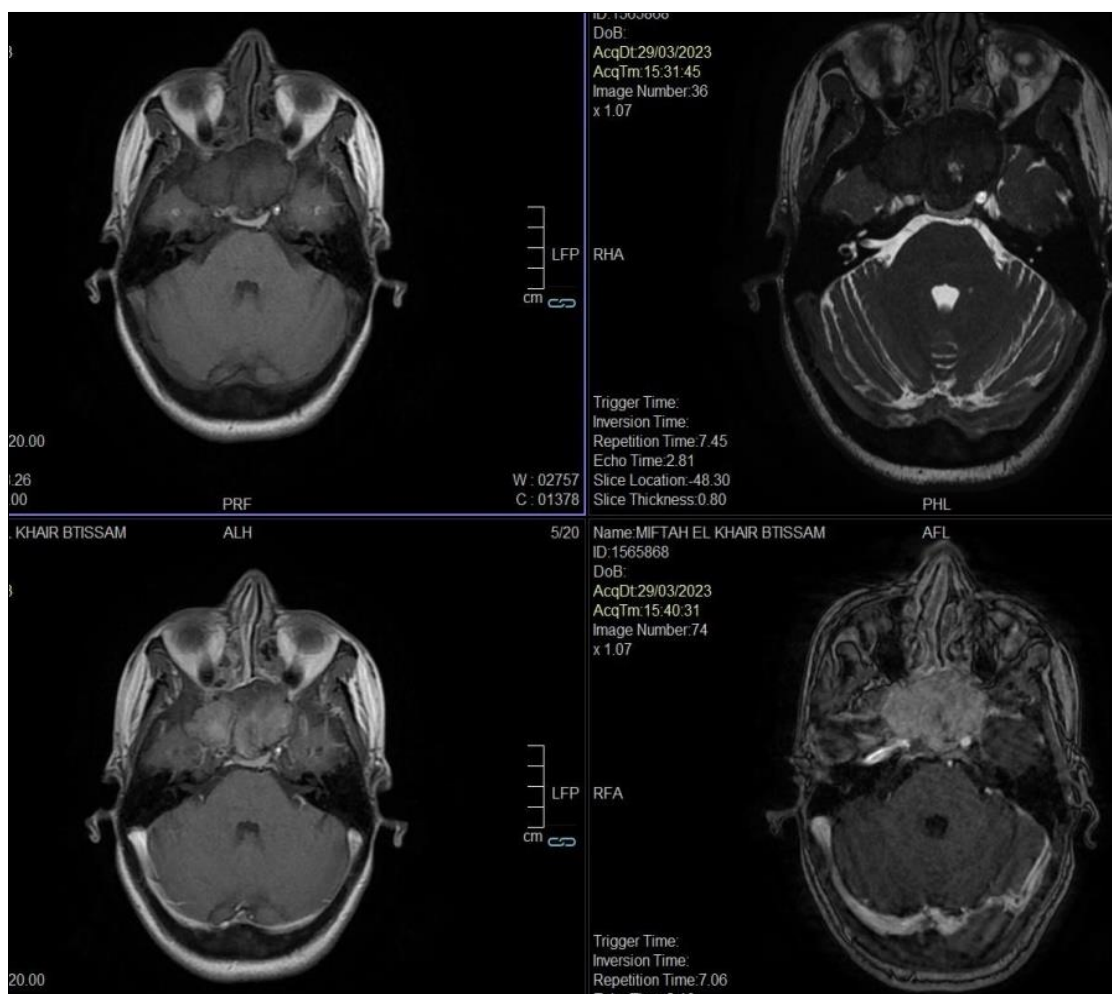


Fig 2

On MR imaging, the lesion showed iso-intensity to gray matter on T1-weighted images and heterogeneous hyperintensity on T2-weighted images,

and showed intense enhancement. The extent of the lesion and its relationship to the surrounding structures were best evaluated by CT and MR imaging. (Figure 2)

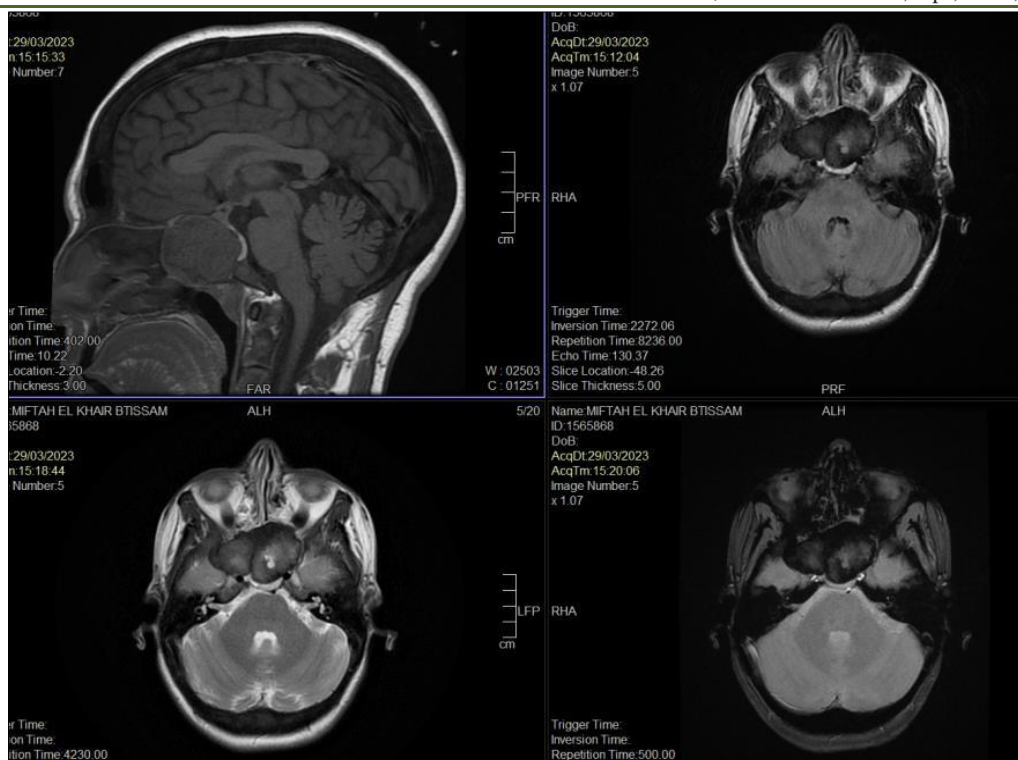


Fig 3

## DISCUSSION

Currently, hyperparathyroidism is discovered by chance in 75-80% of cases, on the occasion of a blood test showing asymptomatic hypercalcemia. It may also be revealed by renal lithiasis or cardiovascular disorders [8].

The bone manifestations of hyperparathyroidism: bone cysts, osteoporosis, subperiosteal resorption and brown tumours, represent the late expression of the disease, and have become rare, occurring in 5 to 15% of cases.

Moreover, it is exceptional for a brown tumor to be the first and only sign of parathyroid hyperfunction. The incidence of these lesions reported some twenty years ago was 1.5 to 1.7% in secondary hyperparathyroidism and 3% in primary hyperparathyroidism.

In the majority of cases, hyperparathyroidism is linked to primary hyperparathyroidism. In over 80% of cases, primary hyperparathyroidism results from a parathyroid adenoma, more rarely from hyperplasia (15%).

Primary hyperparathyroidism frequently affects patients over the age of 50, particularly postmenopausal women. Our patient was 32 years old and had normal genital activity. Since the introduction of routine calcium assays and the development of 1<sup>st</sup> 84 parathyroid hormone assay techniques, the diagnosis has been made

incidentally in asymptomatic patients or during osteoporosis work-up.

Benign hyperparathyroidism has a predilection for the female sex. Brown tumors can affect the entire skeleton, with the most frequent sites being the pelvis, ribs, femurs, mandible and hands. Sphenoidal localization is extremely rare [16]. Clinically, the symptoms caused by these lesions depend on the size of the process and its location.

Radiologically, the brown tumor manifests itself as nonspecific osteolysis that can take on several appearances. The most common appearance is that of monogeneoid or multilocular bone lysis with imprecise margins, leading to cortical blowing or even rupture, which may suggest malignancy, particularly in destructive lesions. The CT scan reveals a tissue-dense mass that takes up contrast, but does not invade the soft tissues, and no periosteal reaction is noted.

## CONCLUSION

Brown tumor, although rare, should be listed in the differential diagnosis of expansive mass lesions in the area of the sphenoid sinus and cranial base. The management is multidisciplinary, and therapeutic options should target the underlying cause.

## REFERENCES

- Khan, A., & Bilezikian, J. (2000). Primary hyperparathyroidism: pathophysiology and impact on bone. *Cmaj*, 163(2), 184-187.

- Lee, P. K., Jarosek, S. L., Virnig, B. A., Evasovich, M., & Tuttle, T. M. (2007). Trends in the incidence and treatment of parathyroid cancer in the United States. *Cancer*, 109(9), 1736-1741.
- Marcocci, C., & Cetani, F. (2011). Primary hyperparathyroidism. *New England Journal of Medicine*, 365(25), 2389-2397.
- Pallan, S., Rahman, M. O., & Khan, A. A. (2012). Diagnosis and management of primary hyperparathyroidism. *Bmj*, 344.
- Proimos, E., Chimona, T. S., Tamiolakis, D., Tzanakakis, M. G., & Papadakis, C. E. (2009). Brown tumor of the maxillary sinus in a patient with primary hyperparathyroidism: a case report. *Journal of Medical Case Reports*, 3, 1-5.
- Vera, L., Dolcino, M., Mora, M., Oddo, S., Gualco, M., Minuto, F., & Giusti, M. (2011). Primary hyperparathyroidism diagnosed after surgical ablation of a costal mass mistaken for giant-cell bone tumor: a case report. *Journal of Medical Case Reports*, 5, 1-6.