

# Aseptic Diaphyseal Pseudarthrosis of the Forearm Initially Treated with Target Plate: Risk Factors and Management

M. Habbab<sup>1\*</sup>, A. Naell<sup>1</sup>, M. Nassiri<sup>1</sup>, M. Madhar<sup>1</sup>, R. Chafik<sup>1</sup>, H. Elhaoury<sup>1</sup>, A. Achkoun<sup>1</sup>

<sup>1</sup>Traumatology Orthopedic Department, Ibn Tofail Hospital Marrakech, Morocco

DOI: [10.36347/sasjs.2024.v10i04.023](https://doi.org/10.36347/sasjs.2024.v10i04.023)

| Received: 16.03.2024 | Accepted: 22.04.2024 | Published: 27.04.2024

\*Corresponding author: M. Habbab

Traumatology Orthopedic Department, Ibn Tofail Hospital Marrakech, Morocco

## Abstract

## Original Research Article

Aseptic diaphyseal pseudarthrosis of the forearm is a major complication. There are patient-related and treatment-related risk factors. The aim of our work is to evaluate the functional and radiological results of aseptic diaphyseal pseudarthrosis of the forearm initially treated with a screw plate. A series of 12 patients were collected in the Orthopedic and Traumatological Surgery Department A of IBN TOFAIL Hospital, retrospectively over a 5-year period. The most frequent site of these pseudarthroses was the ulna (5 cases), followed by both bones (4 cases) and finally the radius (3 cases). 50% of pseudarthroses were atrophic (12 cases). The use of a screw-plate stabilization technique combined with bone grafting and osteo-muscular decortication yielded satisfactory results in terms of bone consolidation and clinical outcome. Smoking is a major risk factor. Solid restraint is necessary to immobilize the fracture site and protect it from forces detrimental to consolidation. De-periostealization and muscular deinsertion are iatrogenic factors that favour the occurrence of pseudarthrosis. Solid DCP plate osteosynthesis combined with autograft after decortication of the fracture site is an important therapeutic weapon with good results.

**Keywords:** pseudarthrosis– aseptic - risk factors.

**Copyright © 2024 The Author(s):** This is an open-access article distributed under the terms of the Creative Commons Attribution **4.0 International License (CC BY-NC 4.0)** which permits unrestricted use, distribution, and reproduction in any medium for non-commercial use provided the original author and source are credited.

## INTRODUCTION

Aseptic diaphyseal pseudarthrosis of the forearm is a late and rare complication. It is defined as a definitive absence of radiological signs of consolidation.

Certain risk factors may favour the occurrence of this complication, smoking being by far the most incriminating factor in pseudarthrosis.

The aim of surgical treatment is to achieve total consolidation of the fracture site.

## MATERIALS AND METHODS

This is a single-center retrospective study, spread over a five-year period from 2015 to 2020, encompassing 12 patients with diaphyseal pseudarthrosis initially treated with screw plates.

### Inclusion criteria:

- Age greater than 15 years
- Complete medical record and patients initially operated on with screw plates.
- Exclusion criteria:
- Age less than 15 years

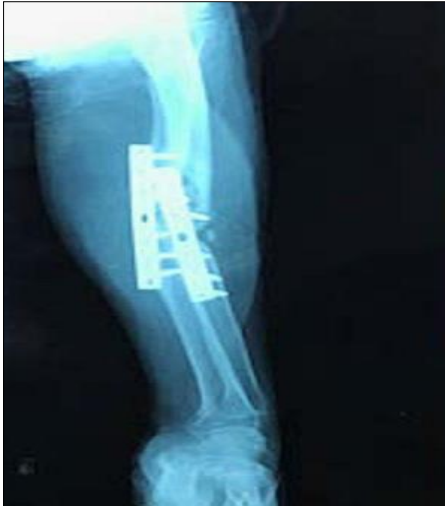- Incomplete medical records
- Septic pseudarthrosis
- Pseudarthrosis treated by other therapeutic modalities

## RESULTS

The mean age was 36 years, with a peak between 26 and 35 years, and a male predominance of 66.6%. Among the antecedents, smoking was present in 83.3%, and 58.3% were manual workers. There was a notion of early active mobilization of the operated limb before 3 months in 33.3%. Socioeconomic status was low in 75%.

In our series, 58.3% of patients underwent initial surgery in our department. The type of plate used for the first osteosynthesis was DCP for the radius in 100% of cases. DCP and Tiers tube plates were used for the ulna in 66.6% and 33.4% respectively.

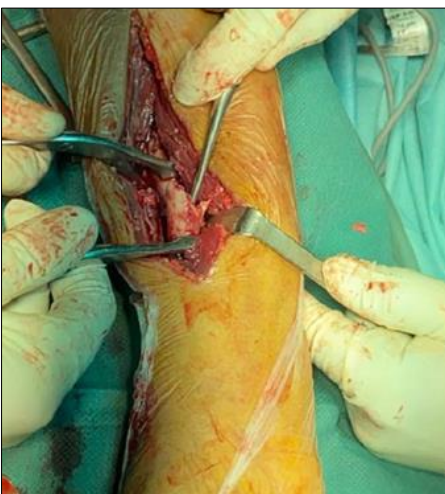
The type of pseudarthrosis was atrophic pseudarthrosis in 50% of cases. All our patients underwent internal osteosynthesis with a screwed plate + autograft.



**AP X-ray of the forearm showing eutrophic pseudarthrosis**



**AP X-ray of the forearm showing eutrophic pseudarthrosis**



**Intraoperative view of a HENRY approach**

## DISCUSSION

We note that all published studies agree on the young age of patients, given that this is the most active population and therefore the most exposed to MVAs (Motor Vehicle Accidents) [1].

Smoking is a risk factor frequently described in various series, with KLOEN *et al.*, finding a smoking rate of 80% [2, 3].

The low socio-economic status of manual workers may lead them to use and mobilize the affected limb at an early stage, thus jeopardizing the stability of the osteosynthesis material and the risk of disassembly. This brings us back to the use of solid restraint for the first 6 weeks, using a palmar brachio-antebrachial cast. In the SAKA series, immobilization lasted 2 weeks [4].

Deperiostealization, evacuation of the fracture hematoma and wide muscular deinsertion compromise bone vascularization, exposing the patient to an increased risk of pseudarthrosis, most often atrophic. Diaphyseal pseudarthrosis of the upper limb, including the forearm, must be differentiated from diaphyseal pseudarthrosis of the lower limb, as the principles of stress are rotation and distraction, not compression. This fundamental feature is the basis for the treatment of diaphyseal fractures of the forearm, which focuses on rigidly blocking shearing and rotational forces [5]. The success of surgical treatment for forearm pseudarthrosis depends on a number of parameters, such as the length of time since the initial injury, the number of previous surgical interventions, the presence of infection, the length of the bone defect and the type of fixation method used. The aim of surgical treatment is to restore the proper length of both forearm bones, restore anatomy and rapidly regain function of the upper limb and hand. In our series, osteosynthesis using a DCP-type compression screw plate (3.5mm) was performed after manual compression of the pseudarthrosis site in 91.6% of cases, with the optimal set-up comprising a minimum of three screws on either side of the site. This is in line with the series by REIS and KLOEN, whose osteosynthesis technique was the compression screw plate [6, 7].

A new technique for treating post-traumatic forearm pseudarthrosis in young patients with nailing and platelet-rich plasma remains a subject of scientific debate and discussion [8].

## CONCLUSION

Pseudarthrosis is a relatively rare complication, but its therapeutic consequences are serious. Pseudarthrosis of both forearm bones is treated primarily by compression screw-plate fixation, following debridement, osteo-muscular decortication, bone autografting from the iliac bone, and rehabilitation. This technique has produced satisfactory functional results.

New techniques are currently the subject of debate, notably nailing and platelet-rich plasma.

## BIBLIOGRAPHIE

1. Obert, L., Lepage, D., & Garbuio, P. (2009). Fractures récents et anciennes des deux os de l'avant bras chez l'adulte. *EMC, Techniques Chirurgicales-Orthopédie-Traumatologie*, 44-342.
2. Kloen, P., Buijze, G. A., & Ring, D. (2012). Management of forearm nonunions: current concepts. *Strategies in trauma and limb reconstruction*, 7, 1-11.
3. Kloen, P., Wiggers, J. K., & Buijze, G. A. (2010). Treatment of diaphyseal non-unions of the ulna and radius. *Archives of orthopaedic and trauma surgery*, 130, 1439-1445.
4. Saka, G., Saglam, N., Kurtulmus, T., Avci, C. C., & Akpinar, F. (2014). Treatment of diaphyseal forearm atrophic nonunions with intramedullary nails and modified Nicoll's technique in adults. *Acta Orthopaedica et Traumatologica Turcica*, 48(3), 262-270.
5. Cruess, R. L. (1973). The management of forearm injuries. *Orthop Clin North Am*, 4(4), 969-82.
6. dos Reis, F. B., Faloppa, F., Fernandes, H. J. A., Albertoni, W. M., & Stahel, P. F. (2009). Outcome of diaphyseal forearm fracture-nonunions treated by autologous bone grafting and compression plating. *Annals of surgical innovation and research*, 3, 1-4.
7. Kloen, P., Wiggers, J. K., & Buijze, G. A. (2010). Treatment of diaphyseal non-unions of the ulna and radius. *Archives of orthopaedic and trauma surgery*, 130, 1439-1445.
8. La Récupération Améliorée Après Chirurgie Prothétique R. PRP-concentrés plaquetaires.