

Axenfeld-Rieger Syndrome (ARS): A Case Report

Houda Brarou^{1*}, Samah Sadiki¹, Zakaria Chaibi¹, Manal Bouggar¹, Badr Oubaaz¹, ZinebSaif¹, Yasmine Bensaoud¹, Taoufik Abdellaoui², Yassine Mouzari¹, Abdelbare Oubaaz¹

¹Mohammed V Military Hospital, Rabat, Morocco

²Sidi Mohammed Ben Abdellah University, Fes, Morocco

DOI: [10.36347/sjams.2024.v12i05.006](https://doi.org/10.36347/sjams.2024.v12i05.006)

| Received: 15.03.2024 | Accepted: 27.04.2024 | Published: 09.05.2024

*Corresponding author: Houda Brarou

Ophthalmology Department, Mohammed V Military Hospital, Mohammed V University, Rabat, Morocco

Abstract

Case Report

Axenfeld-Rieger syndrome (ARS) is a rare autosomal dominant condition manifesting as a heterogeneous group of features. Of particular note are the ocular and craniofacial anomalies and dental features such as hypodontia, microdontia, taurodontism, enamel hypoplasia, conical-shaped teeth, shortened roots and delayed eruption. We report the case of a 23 years old female patient, who presented to the ophthalmology department for a routine eye check-up. The ophthalmological examination showed vertical cup-to-disc ratio of 0,6 in the right eye and 0,7 in the left eye with normal intra ocular pressure. On general examination, she had maxillary hypoplasia, broad nasal bridge, oligodontia and microdontia.

Keywords: Axenfeld reiger syndrome, corectopia, IOP, glaucoma.

Copyright © 2024 The Author(s): This is an open-access article distributed under the terms of the Creative Commons Attribution 4.0 International License (CC BY-NC 4.0) which permits unrestricted use, distribution, and reproduction in any medium for non-commercial use provided the original author and source are credited.

INTRODUCTION

Axenfeld-Rieger syndrome (ARS) is a rare genetic disease affecting around 1 in 200,000 of the population. The syndrome is characterized by anterior segment abnormalities of the eye and can also affect extraocular structures such as the craniofacial bones and dentition [1]. The disorder is inherited as an autosomal dominant trait [2]. Patients with ARS are at approximately a 50% risk for the development of glaucoma [1].

We report the case of a 23 years old female patient who came for a routine eye check-up. The ophthalmological examination showed a minor corectopia in the left eye (Figure 1). Gonioscopic images of both eyes revealed posterior embryotoxon with attached iris strands and peripheral anterior synechiae (Figure 2, 3). Intraocular pressure measurements were 19 mmHg in the right eye and 20 mmHg in the left eye measured with Goldmann tonometry. Optic nerve head evaluation revealed round, distinct, well-perfused nerve with a vertical cup-to-disc ratio of 0,6 in the right eye and 0,7 in the left eye. Systemic evaluation revealed maxillary hypoplasia, broad nasal bridge, oligodontia and microdontia. Considering the ocular and systemic features, a diagnosis of Axenfeld-Rieger syndrome (ARS) was made. The patient was advised 6 months IOP monitoring and regular systemic evaluation.

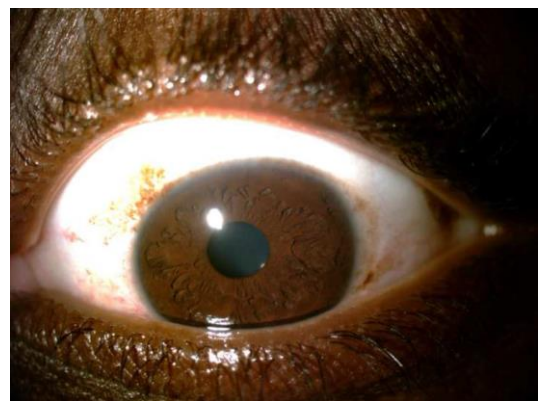


Figure 1: Image of the Left eye showing a slight corectopia



Figure 2: Gonioscopic images showing posterior embryotoxon with attached iris strands and peripheral anterior synechiae



Figure 3: Gonioscopic images showing posterior embryotoxon with attached iris strands and peripheral anterior synechiae

DISCUSSION

ARS occurs secondary to genetic mutations vital for ocular development, with majority having mutations in transcription factors PITX2 and FOXC1. It is a fully penetrant, multigenic syndrome with variable expressivity. Inheritance is autosomal dominant in 70% and sporadic in 30%. It has both ocular and systemic manifestations. Ocular findings in ARS can affect the cornea (megalocornea and posterior embryotoxon), iris (mild to severe degenerative changes like hole formation, corectopia and ectropion uveae) and anterior chamber angle (anterior insertion of the iris, tissue strands from the peripheral iris to the prominent Schwalbe's line). Systemic features include craniofacial dysmorphism (hypertelorism, telecanthus, flat nasal bridge, mid-facial hypoplasia), dental malformations (hypodontia, anodontia or peg-shaped teeth), umbilical defects (redundant periumbilical skin) and cardiac defects [3-5].

The most severe ocular phenotype associated with ARS is early-onset glaucoma, which affects more

than 50% of patients with ARS [3]. Treating glaucoma is the primary aim in patients with ARS. Medical management can be tried but is usually unrewarding, necessitating surgical interventions.

CONCLUSION

Axenfeld Rieger Syndrome is a rare autosomal dominant multisystem disorder. Monitoring and control of intraocular pressure in patients with ARS are of utmost importance as delay in treatment can lead to irreversible damage. All patients with such ocular features should be thoroughly examined systemically to look for any coexistent systemic abnormalities.

Conflict of Interest: The authors declare that they have no competing interests.

REFERENCES

1. Shields, M. B., Buckley, E., Klintworth, G. K., & Thresher, R. (1985). Axenfeld-Rieger syndrome. A spectrum of developmental disorders. *Survey of ophthalmology*, 29(6), 387-409.
2. Dunbar, A. C., McIntyre, G. T., Laverick, S., & Stevenson, B. (2015). Axenfeld-Rieger syndrome: a case report. *Journal of orthodontics*, 42(4), 324-330.
3. Shields, M. B., Buckley, E., Klintworth, G. K., & Thresher, R. (1985). Axenfeld-Rieger syndrome. A spectrum of developmental disorders. *Survey of ophthalmology*, 29(6), 387-409.
4. Song, W., & Hu, X. (2017). The rare Axenfeld-Rieger syndrome with systemic anomalies: A case report and brief review of literature. *Medicine*, 96(33), e7791.
5. Smith, J., & Elder, J. (2017). Glaucoma spectrum and age-related prevalence of individuals with FOXC1 and PITX2 variants.