

Calciphylaxis of the Penis in a 70-Year-Old Man: A Case Report

Hamza Dergamoun¹, Aadil Taoufiq^{1*}, Ossama Jalal¹, Imad Ziouziou¹

¹Faculty of Medicine and Pharmacy of Agadir, Ibn Zohr University, Morocco

DOI: [10.36347/sasjs.2024.v10i05.009](https://doi.org/10.36347/sasjs.2024.v10i05.009)

| Received: 25.02.2024 | Accepted: 02.04.2024 | Published: 13.05.2024

*Corresponding author: Aadil Taoufiq

Faculty of Medicine and Pharmacy of Agadir, Ibn Zohr University, Morocco

Abstract

Case Report

Penile calciphylaxis is a severe form of calcifying uremic arteriopathy, with only a few cases reported in the literature. It is uncommon, characterized by calcification within the walls of small vessels, resulting in ischemic changes to the skin, and is most commonly seen in patients with end-stage renal failure (ESRF). We reported a 70-year-old patient case of chronic ESRF on hemodialysis and type 2 diabetes who presented with painful blackish necrotic discoloration of the peri-meatal area and dry gangrene at the big toe of the right foot. The patient was treated with penile debridement, penile stump necrosectomy, and broad-spectrum antibiotics. The patient was diagnosed with penile calciphylaxis based on histopathological findings. This episode occurred again in postoperative follow-up and required regularization of the penile stump. In conclusion, the management of this rare situation is controversial, and its diagnosis is still difficult due to the scarcity of reported cases.

Keywords: Case Report, Penile Calciphylaxis, Calcific Uremic Arteriopathy, Kidney Failure.

Copyright © 2024 The Author(s): This is an open-access article distributed under the terms of the Creative Commons Attribution 4.0 International License (CC BY-NC 4.0) which permits unrestricted use, distribution, and reproduction in any medium for non-commercial use provided the original author and source are credited.

INTRODUCTION

Calcific uremic arteriopathy is distinguished by obstructive vasculopathy, with calcification of small arteries and arterioles leading to luminal occlusion and, eventually, cutaneous necrosis [1]. The incidence of penile calciphylaxis is estimated to be around 1% in patients with chronic kidney disease and 4% in dialysis patients. The diseases have a poor prognosis, with a median death time of 2.5 months [2].

Calcific uremic arteriopathy typically affects the thighs and buttocks, but it can also affect the distal phalanges of the hands and feet. Ischemia and infarction of the bowel, myocardium, brain, optic nerve and muscles are rare systemic manifestations [3, 4].

Penile calciphylaxis presented in an unusual manner, with various management options based on the literature being used. The most common presenting symptom is a painful ischemic penile lesion. End-stage renal failure (ESRF), dialysis, obesity, and diabetes are all risk factors [3]. It is frequently associated with high mortality, particularly when a secondary infection is present.

Penile calciphylaxis is a rare phenomenon with cases reported in the literature [2-4]. We present a case of penile calciphylaxis in a 70-year-old patient case of chronic ESRF on hemodialysis and type 2 diabetes.

PATIENT AND OBSERVATION

Patient Information:

A 70-year-old male patient case of chronic ESRF on hemodialysis and type 2 diabetes who presented with painful blackish necrotic discoloration of the peri-meatal area and dry gangrene at the big toe of the right foot in the last two days.

The patient had no history of penile trauma to or similar episode and he not smoker. Notably, his glans penis lesion was recently treated with a one-week course of oral antibiotic without improvement.

Clinical Findings:

The patient was afebrile (temperature of 36.3°C) and had a blood pressure of 120/70 mmHg. Physical examination revealed dry gangrene at the big toe of the right foot associated with several small, exquisitely tender, necrotic ulcers and painful blackish necrotic discoloration of the peri-meatal area. The digital lesions were cool to the touch and without surrounding edema or erythema (Figure 1). The examination was otherwise unremarkable.

Diagnostic Assessment:

The blood tests found hypercalcemia of 110mg/L and hyperphosphatemia of 50mg/L, hemoglobin was 15 g/dl, white blood cells 13,300/mm³, platelets 153,000/mm³, creatinemia 14mg/l, urea 1

Citation: Hamza Dergamoun, Aadil Taoufiq, Ossama Jalal, Imad Ziouziou. Calciphylaxis of the Penis in a 70-Year-Old Man: A Case Report. SAS J Surg, 2024 May 10(5): 567-570.

mmol/l, blood glucose 1.46 g/l. No radiological examination is done.

Therapeutic Interventions:

The patient is operated on under general anesthesia, The Procedure consisted in placing a Foley catheter, with a trimming of the lesions at the level of the glans penis, a gland biopsy was performed. Post-operatively the patient was put on a double antibiotic therapy: 3rd generation cephalosporin and gentamycin.

Follow-Up and Outcome:

During the operation, bacteriological study resulting in a polymorphic culture. The biopsy performed

for the pathology examination concluded with calciphylaxis (mixed inflammatory infiltrate associated with areas of calcification and fibrosis). The evolution in hospital was marked by a recurrence of gangrene on the distal end of the penis which required a second excision of the necrosis of the penile stump. The evolution afterwards was favorable with satisfactory healing of the penis (Figures 2 (a) and 2 (b)).

Patient Perspective: During treatment, the patient was satisfied with the level of care provided to him.

Informed Consent: written informed consent was obtained from the patient for participation in our study.

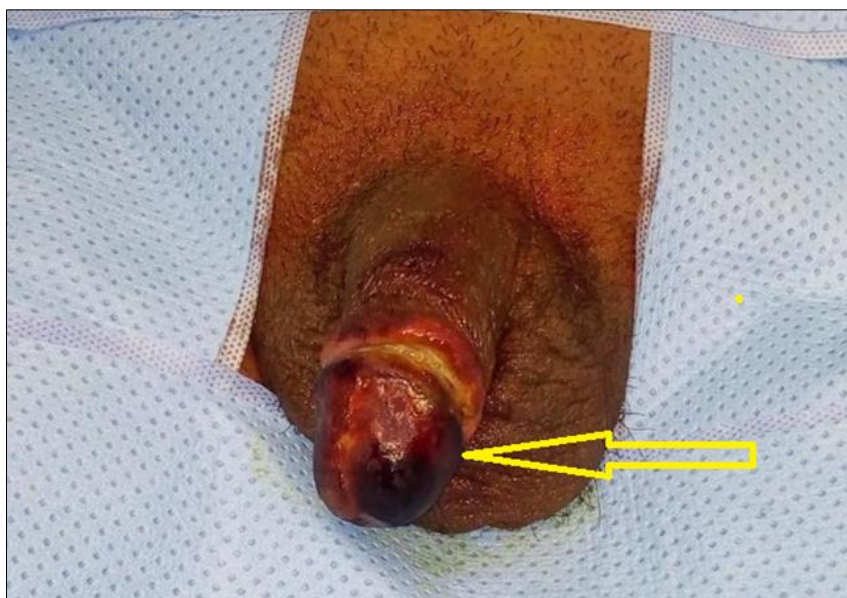

Figure 1: The digital lesions of calciphylaxis

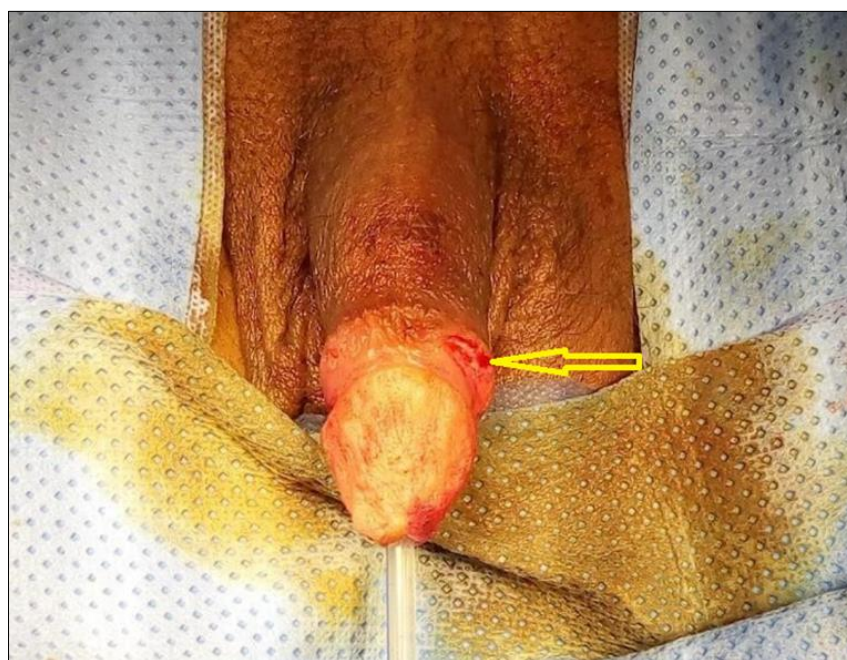


Figure 2 (a): The evolution was favorable with satisfactory healing of the penis.

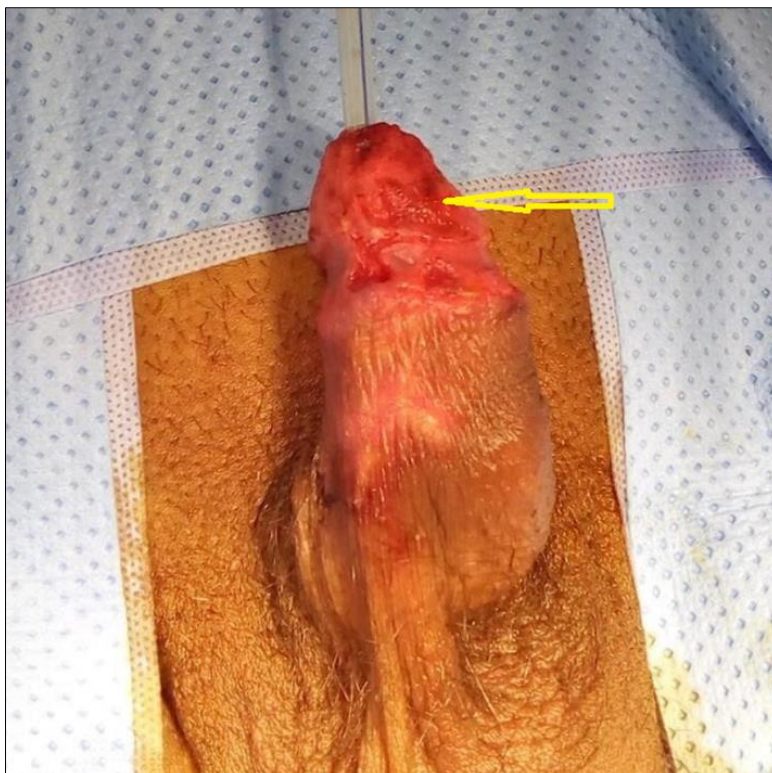

Figure 2 (b): The evolution was favorable with satisfactory healing of the penis.

DISCUSSION

Diabetes is the cause of ischemic complications; this is secondary to the micro and macro-angiopathy that it causes. Dialysis also causes vascular damage by means of thromboses caused by the extracorporeal circulation [8]. It is also responsible for phosphocalcic disorders which are at the origin of intravascular calcifications [9]. The association of comorbidities such as diabetes and chronic renal failure at the dialysis stage thus multiplies the ischemic vascular complications which preferentially affect the medium and small vessels (calciphylaxis). Calciphylaxis, the diagnosis of which is essentially clinical, is characterized by the acute appearance of painful skin lesions, generally symmetrical, which may be responsible for ulcers and bedsores, these lesions are distal in 90% of the cases and proximal in 44 to 68% of the cases. Affecting the trunk, buttocks [6]. Due to its rich vascular network, calciphylaxis of the penis is even less common: a 2018 review estimates that no more than 50 cases have been reported in the literature [17].

In our context, the macroscopic aspect of the necrotic penis had evoked a tumor of the penis. This hypothesis justified the biopsy and the anatomopathological examination. The pathological study can help with the diagnosis but it is not always possible because the involvement is segmental and the biopsy must be deep and wide [7-10]. In typical forms, there are calcifications consisting of phosphocalcic deposits in the wall of the arterioles of the skin and muscles associated with necrosis of fat and infiltration by

inflammatory cells [11]. These calcifications are visualized on CT, considered as the adequate examination to assess atherosclerosis [11, 15]. However, in the event of damage to the penis, MRI constitutes the most efficient examination for the exploration of the corpora cavernosa [16] making it possible to better appreciate the limit between necrotic tissue and healthy tissue [11]. In addition, this examination has the advantage of being able to be carried out without risk in renal insufficiency but it remains inaccessible in our context.

In the literature a very limited number of penile necrosis due to calciphylaxis have been reported. Recent studies have shown that elevated levels of PTHs are not the root and the phospho-calcium balance is not the only important factor involved in pathogenesis [16].

Obesity and diabetes are described as enabling factors, our patient had type 2 diabetes. In the literature, the glycemic balance is insufficient to prevent this vascular complication. Adequate treatment remains surgical, which is based on excision of necrotic tissue, amputations if necessary and skin grafting [12, 13]. For some, in the case of penile calciphylaxis, a partial penectomy could be recommended [9, 14] while the STEIN team [15], recommends an expectation until stabilization of the ischemia. Mortality is 63 to 72% in the case of proximal involvement and 23 to 47% in the case of distal involvement [15]. In our case the patient survived.

CONCLUSION

The interest of this case lies in the rarity of ischemic gangrene of the penis in diabetic and dialysis patients. Several hypotheses are raised. There is no consensus in care. Knowledge and treatment of risk factors for calciphylaxis is essential to decrease mortality in this type of patient.

Competing Interests: The authors declare no competing interest.

REFERENCES

- Bhatty, T. A. N., & Riaz, K. (2009). Calciphylaxis mimicking penile gangrene: a case report. *The Scientific World Journal*, 9, 1355-1359.
- Jean, G., Terrat, J. C., Vanel, T., Hurot, J. M., Lorriaux, C., Mayor, B., & Chazot, C. (2010). Calciphylaxis in dialysis patients: to recognize and treat it as soon as possible. *Néphrologie & Thérapeutique*, 6(6), 499-504.
- JHAVERI, F. M., WOOSLEY, J. T., & FRIED, F. A. (1998). Penile calciphylaxis: rare necrotic lesions in chronic renal failure patients. *The Journal of urology*, 160(3 Part 1), 764-767.
- Agaajani, S., Becker, D., & Loute, G. (2004). Calciphylaxis lesions in a patient with end-stage renal failure. *Leuven Medical*, 123 (7), 210-216.
- Cook, S., Hugli, O., & Lemoine, R. (2001). Calciphylaxie proximale sans insuffisance rénale. *Forum med suisse*, 5, 122.
- Trost, O., Kadlub, N., Trouilloud, P., Malka, G., & Danino, A. (2005, October). Calciphylaxis: a severe but unrecognized complication in end-stage renal disease patients. A review of 2 cases. In *Annales de Chirurgie Plastique et Esthétique* (Vol. 50, No. 6, pp. 746-750).
- Kaaroud, H., Béji, S., Souissi, I., Zouaghi, K., El Younsi, F., Abderrahim, E., ... & Kheder, A. (2010). Calciphylaxis in chronic renal failure: 3 cases. *La Tunisie Médicale*, 88(4), 261-264.
- HATAMA, S., NAKAMOTO, M., IMAMURA, A., KANAI, H., ABE, T., & GOYA, T. (1991). Penile gangrene in a patient with diabetic nephropathy on continuous ambulatory peritoneal dialysis. *The Japanese Journal of Nephrology*, 33(9), 863-866.
- Sorensen, M. D., Long, L. O., Wessells, H., & Kuan, J. K. (2007). Monckeberg's calciphylaxis with necrosis of the glans penis: A case presentation. *Hemodialysis International*, 11(3), 300-302.
- Younis, N., Sells, R. A., Desmond, A., Helliwell, T., Guerin, D., Jibani, M., & Vora, J. (2002). Painful cutaneous lesions, renal failure and urgent parathyroidectomy. *Journal of Nephrology*, 15(3), 324-329.
- Bouzouita, A., Kerkeni, W., Cellier, L., Gobet, F., & Sibert, L. (2014). Penile gangrene: a rare complication of systemic calciphylaxis, to be screened. *Prog Urol*, 24, 142-4.
- Descotes, J. L., & Hubert, J. (2003). Urology imaging: contribution of imaging in bladder injuries. *Progres en Urologie: Journal de L'association Francaise D'urologie et de la Societe Francaise D'urologie*, 13(5), 1145-1148.
- Stein, M., Anderson, C., Ricciardi, R., Chamberlin, J. W., Lerner, S. E., & Glicklich, D. (1994). Penile gangrene associated with chronic renal failure: report of 7 cases and review of the literature. *The Journal of urology*, 152(6), 2014-2016.
- Ohta, A., Ohomori, S., Mizukami, T., Obi, R., & Tanaka, Y. (2007). Penile necrosis by calciphylaxis in a diabetic patient with chronic renal failure. *Internal Medicine*, 46(13), 985-990.
- Arch-Ferrer, J. E., Beenken, S. W., Rue, L. W., Bland, K. I., & Diethelm, A. G. (2003). Therapy for calciphylaxis: an outcome analysis. *Surgery*, 134(6), 941-944.
- Jaluka, T. (2005). *La calciphylaxie – concepts en evolution*. Nephrologie conférences scientifiques, 6(5).
- Smilnak, G., Jiang, M., & Jain, B. (2022). Calciphylaxis of the penis and distal digits: a case report. *Journal of Medical Case Reports*, 16(1), 18. <https://doi.org/10.1186/s13256-021-03231-4>.