

Primary Hepatic Diffuse Large B cell Lymphoma: A Case Report and Review of the Literature

Regragui S*, Harif M

Department Of Hematology, University Hospital Of Tangiers, Morocco

DOI: 10.36347/SASJM.2019.v05i09.005

| Received: 04.09.2019 | Accepted: 22.09.2019 | Published: 26.09.2019

*Corresponding author: Regragui S

Abstract

Case Report

Primary hepatic lymphoma (PHL) is a rare extranodal non-Hodgkin's lymphoma which can be missed easily. We present a case of extranodal high grade lymphoma of the liver in a 57-year-old lady with no particular pathological history. Lymphoma manifested with sharp significant pain in the right hypochondrium, weakness, and profuse night sweats. Contrast enhanced computed tomography scan (CT-scan) of the abdomen revealed heterogeneous segment VI tumor process measuring 8 cm long axis. Histological and immunohistochemical features of the tumors allowed diagnosis of diffuse large B-cell lymphoma (DLBCL). To exclude secondary liver lesion by non-Hodgkin lymphoma, chest and small pelvis CT-scan and study of bone marrow were performed. The patient was refractory to R-CHOP, R-DAOX and R-GEMOX. She was placed in palliative care and she died three weeks after the cessation of treatment. Primary hepatic lymphoma is extremely rare, and its management is debatable in the absence of international recommendations.

Key words: Primary hepatic lymphoma, Diffuse Large B Cell Lymphoma, hypochondrium, liver.

Copyright © 2019: This is an open-access article distributed under the terms of the Creative Commons Attribution license which permits unrestricted use, distribution, and reproduction in any medium for non-commercial use (NonCommercial, or CC-BY-NC) provided the original author and source are credited.

INTRODUCTION

Diffuse large B cell lymphoma (DLBCL) is a fairly common highly malignant type of non-Hodgkin's lymphoma that develops in the lymph nodes. Primary hepatic lymphoma (PHL) is rare, and accounts for 0.016% of all non-Hodgkin's lymphomas and 0.4% of extranodal non-Hodgkin's lymphoma [1]. Because the clinical features are not very specific, PHL can easily be misdiagnosed as liver inflammatory disease, benign tumor, or liver cancer.

We report a case of refractory primary hepatic diffuse large B cell lymphoma (PHDLBCL) in an old lady, presented to us with abdominal pain and hepatic mass, which was diagnosed as PHL in echo-guided biopsy.

CASE REPORT

This is a 57-years-old patient with no particular pathological history. She consults for non-radiating right hypochondrial pains of progressive worsening, evolving in a context of fever and night sweats without weight loss. At admission, there is a patient with performans status (PS) at 2, the abdominal examination objective pain on palpation of the right hypochondrium; her liver was enlarged, firm and

tender; nevertheless, there is neither jaundice nor peripheral tumor syndrome. Abdominal CT scan shows hepatomegaly on an heterogeneous tumor in segment VI measuring 8 cm long axis with heterogeneous necrotic center, polylobed contours occupying almost the entire right liver (*fig 1*). Echo-guided mass biopsy found liver tissue largely infiltrated by large lymphoid-looking cells with ovoid nuclei, one or more fine-chromatin nucleoli and abundant cytoplasm. Mitoses are numerous and atypicals. Some polymorphous inflammatory cells are involved. These cells are in diffuse ranges (*fig 2A*). Immunohistochemistry found CD20 +, D10 +, anti-Bcl2 +, anti-Bcl6-, anti-MUM1-, and Ki67 is positive at more than 90% of tumor cells, concluding to diffuse large B-cell lymphoma (*fig 2B, 2C*). The positron emission tomography (PET) scan found a very large hypermetabolic tumor of the liver (SUVmax = 18.6) occupying almost the entire right liver and measuring 109x153x150 mm (*fig 3A et B*) with hypermetabolic hepatic hilar lymph nodes (SUVmax = 13.8) and without any extra-hepatic localization. Biological assessment is normal, especially alkaline phosphatase and serologies of Human Immunodeficiency Virus (VIH), Hepatitis B Virus (HBV) and Hepatitis C Virus (HCV); however, lactate dehydrogenase (LDH) are greater than twice the upper limit of the normal. Therapeutically, the patient

received four courses of R-CHOP (Rituximab, Cyclophosphamide, Doxorubicin, Vincristine and Prednisone) without a metabolic response; she progressed on two lines of salvage therapy which are R-DAOX (Rituximab, Dexamethasone, Cytarabine,

Oxaliplatin) and R-GEMOX (Rituximab, Gemcitabine and Oxaliplatin). The patient was placed in palliative care and she died three weeks after the cessation of treatment.

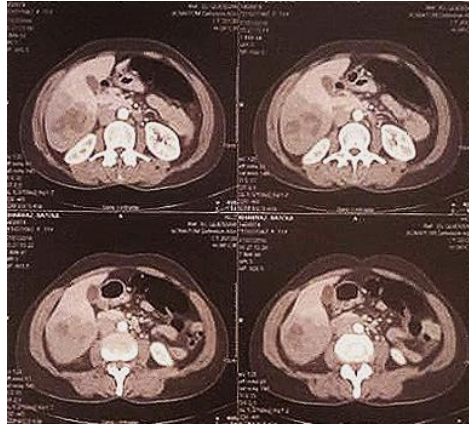


Fig-1: heterogeneous tumor of the right liver with heterogeneous necrotic center and polylobed contours

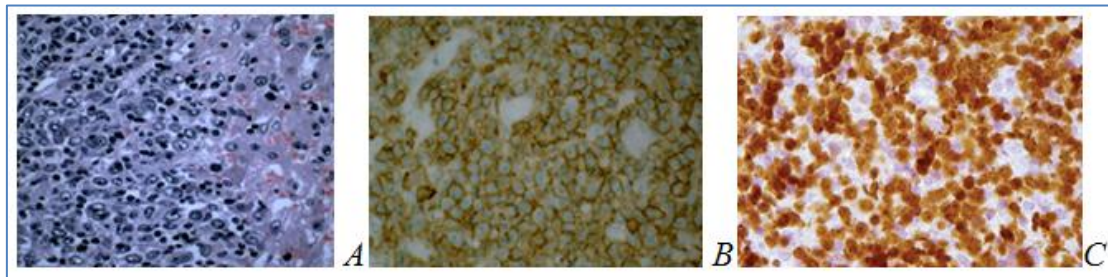


Fig-2: Histology of the hepatic diffuse large B-cell lymphoma

A: liver tissue largely infiltrated by large lymphoid-looking cells with ovoid nuclei (×400). B: CD20-positive tumor cells (×400). C: The Ki67 index is >90% (×400).

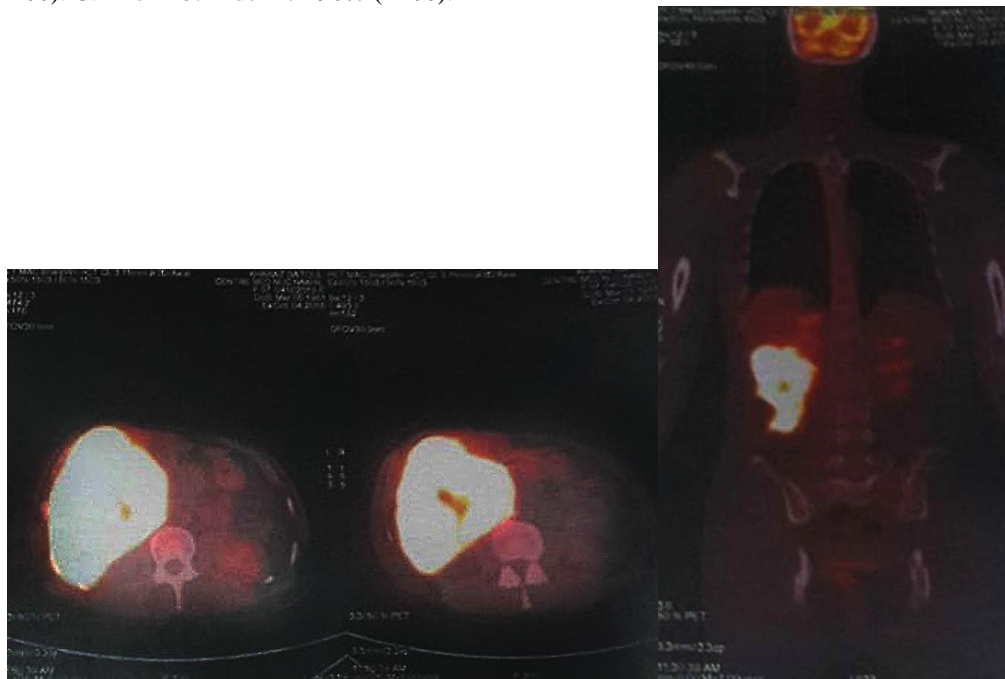


Fig-3A et B: large hypermetabolic tumor of the liver (SUVmax = 18.6) occupying almost the entire right liver measuring 109x153x150 mm with hypermetabolic hepatic hilar lymph nodes (SUVmax = 13.8)

DISCUSSION

The liver is the largest and most important reticuloendothelial organ of our body and is commonly involved in 40% of NHL patients at presentation, but PHL is an unusual disease and a rare form of extranodal lymphomas, accounting for less than 1% of all extranodal lymphomas [2, 3]. It is defined as lymphoma confined only to the liver without the involvement of any other organ, such as spleen, bone marrow, lymph nodes, peripheral blood, or other tissues [2-4].

It can occur at any age but the vast majority of patients with PHL are elderly men [5], in the fifth or sixth decade of life, with male/female ratio of 2 to 3/1 [6, 7].

The pathogenesis of PHL is still unclear, and it has been associated with Epstein Barr Virus (EBV), HCV, HIV or human T cell lymphotropic virus (HTLV) infections; liver cirrhosis; systemic lupus erythematosus; and immunosuppressive therapy [4, 8-12]. Among all these, hepatitis C infection is strongly associated with PHL [8, 13, 14]. However, our patient did not have any of the above conditions.

PHL has non-specific clinical manifestations, and the rate of clinical misdiagnosis is high. The vast majority of PHL patients present with signs and symptoms mimicking acute hepatitis and constitutional symptoms [4] which may delay the diagnosis. Hepatomegaly is found in most patients (75–100%), B symptoms (fever, drenching sweats and weight loss) in 37–86%, weight loss in 57% and jaundice in 4% [6,7]. It is important to recognize that in rare circumstances, PHL can present with fulminant hepatic failure, and because of the ambiguous features and rapid progression, most cases are diagnosed on autopsy with an average survival of 10.7 days from diagnosis [15]. Radiological features of PHL are usually nonspecific, and the most common presentation on CT scan is a solitary hypoattenuating lesion, which may have a central area of low intensity indicating necrosis [16]. It may present also as multiple lesions; even so, diffuse infiltration of the liver is rare in Caucasians [6].

Liver function tests are usually normal, except elevation of alkaline phosphatases. On analysis of laboratory data, LDH is elevated most of the time, while tumor markers such as alpha-feto-protein (AFP) and carcinoembryonic antigen (CEA) remain within normal ranges, and they help in the differential diagnosis of hepatocellular carcinoma or metastatic disease [8, 16]. In our case as well, all the investigations were normal except elevated LDH.

Optimal treatment is not yet defined, but chemotherapy with CHOP-based regimens is the gold standard. The role of surgery is not fully clarified, but there are reports that liver resection followed by adjuvant chemotherapy and/or radiation results in better

prognosis [4, 9, 17]. Yang *et al.* performed a retrospective study to assess the benefits and limits of surgery for PHL and the probability of survival after postoperative chemotherapy. They found that patients with PHL treated with liver resection followed by chemotherapy had a better outcome, and so, postoperative chemotherapy was the only prognostic factor for survival [8]. However, the patients included in this study benefited from the surgical procedure before determining the histology of the tumor, which leads us to question the real place of surgery in the management of this malignant hemopathy.

Emile *et al.* reported that the prognosis of nodular lymphoma cells in PHL is better than that of diffuse infiltrates [17]. The 1-year and 3-year survival rates of nodular infiltrates of PHL were 70% and 38% respectively, and the rates of diffuse infiltration were 57% and 18% respectively. The prognosis of PHDLBCL is poor (median survival of 6 months) for patients treated with chemotherapy alone, but better for patients treated with a combination of modalities (8–16 months) in pre-rituximab era [13,18]. Massive liver infiltration, a high index of proliferation, and elevated LDH levels, as well as advanced age, cirrhosis and elevated levels of beta-2 microglobulin, are worse prognostic factors [19, 20].

CONCLUSION

In conclusion, PHL is a very rare disease that lacks specific imaging and clinical manifestations and biochemical indicators. Its diagnosis is difficult, as lymphoma in other organs or tissues outside of the liver needs to be excluded. When multiple space-occupying lesions are found in the liver but invasion into other organs or tissues is not observed, PHL should be considered as a possible diagnosis and liver biopsy should be performed. If PHL is diagnosed, chemotherapy should be started immediately, and the patient should be closely monitored for adverse reactions and complications.

REFERENCES

1. Noronha V, Shafi NQ, Obando JA, Kummar S. Primary non-Hodgkin's lymphoma of the liver. Critical reviews in oncology/hematology. 2005 Mar 1;53(3):199-207.
2. Freeman C, Berg JW, Cutler SJ: Occurrence and prognosis of extranodal lymphomas. *Cancer*. 1972;29:252-60.
3. Gatselis NK, Dalekos GN. Hepatobiliary and pancreatic: primary hepatic lymphoma. *Journal of gastroenterology and hepatology*. 2011 Jan;26(1):210-.
4. Lei KI. Primary non-Hodgkin's lymphoma of the liver. *Leuk. Lymphoma*. 1998; 29: 293–9.
5. Ma YJ, Chen EQ, Wang J, Tang H. Progress in research of primary hepatic lymphoma. *World Chinese Journal of Digestology*. 2010; 18: 2790-293

6. Lei KI, Chow JH, Johnson PJ. Aggressive primary hepatic lymphoma in Chinese patients. Presentation, pathologic features, and outcome. *Cancer*. 1995; 76: 1336–43
7. Page RD, Romaguera JE, Osborne B. Primary hepatic lymphoma: favorable outcome after combination chemotherapy. *Cancer*. 2001; 92: 2023–9
8. Yang X-W, Tan W-F, Yu W-L. Diagnosis and surgical treatment of primary hepatic lymphoma. *World J. Gastroenterol*. 2010; 16: 6016–9
9. Eom D-W, Huh JR, Kang YK, Lee YS, Yu E. Clinicopathological features of eight Korean cases of primary hepatic lymphoma. *Pathol. Int*. 2004; 54: 830–6.
10. Anthony PP, Sarsfield P, Clarke T. Primary lymphoma of the liver: clinical and pathological features of 10 patients. *J. Clin. Pathol*. 1990; 43: 1007–13
11. Bronowicki JP, Bineau C, Feugier P, Hermine O, Brousse N, Oberti F, Rousselet MC, Dharancy S, Gaulard P, Flejou JF, Cazals-Hatem D, Labouyrie E. Primary lymphoma of the liver: clinical-pathological features and relationship with HCV infection in French patients. *Hepatology*. 2003; 37: 781-787
12. De Renzo A, Perna F, Persico M, Notaro R, Mainolfi C, de Sio I, Ciancia G, Picardi M, Del Vecchio L, Pane F, Rotoli B. Excellent prognosis and prevalence of HCV infection of primary hepatic and splenic non-Hodgkin's lymphoma. *Eur J Haematol*. 2008; 81: 51-57
13. Ryan J, Lange C, Shiu MH, Fortner JG, Straus DJ, Filippa DA, Botet JF, Sanders LM. Primary lymphoma of the liver. *Cancer*. 1988 Jan 15;61(2):370-5.
14. Osborne BM, Butler JJ, Guarda LA. Primary lymphoma of the liver ten cases and a review of the literature. *Cancer*. 1985 Dec 15;56(12):2902-10.
15. Lettieri CJ, Berg BW. Clinical features of non-Hodgkins lymphoma presenting with acute liver failure: a report of five cases and review of published experience. *The American journal of gastroenterology*. 2003 Jul;98(7):1641.
16. Mehta N, Jayapal L, Goneppanavar M, Nelamangala Ramakrishnaiah VP. Primary hepatic lymphoma: A rare case report. *JGH Open*. 2019.
17. Daniel SJ, Attiyeh FF, Dire JJ, Pyun HJ, Carroll DS, Attia A. Primary lymphoma of the liver treated with extended left hepatic lobectomy. *Cancer*. 1985 Jan 1;55(1):206-9.
18. Cabanillas F, Pavon JR, Hagemester FB, McLaughlin P, Rodriguez MA, Romaguera JE, Dong K, Moon T. Alternating triple therapy for the treatment of intermediate grade and immunoblastic lymphoma. *Annals of oncology*. 1998 May 1;9(5):511-8.
19. Avlonitis VS, Linos D. Primary hepatic lymphoma: a review. *The European journal of surgery*. 1999 Sep 17;165(8):725-9.
20. Zheng J, Hou Y, Zhou R, Zhong D. Clinicopathological features of primary hepatic diffuse large B-cell lymphoma: a report of seven cases and a literature review. *International journal of clinical and experimental pathology*. 2015;8(10):12955.