

## Foreign Body Aspiration in Children Clinical, Radiological, and Bronchoscopic Findings

Nagia M. Bushaala<sup>1\*</sup>, Fatma M. Eltagori<sup>1</sup>, Najat ALghazal<sup>1</sup>, Munira A. Radwan<sup>1</sup><sup>1</sup>Department of Pediatrics, Faculty of Medicine, University of Benghazi, LibyaDOI: [10.36347/sjams.2024.v12i05.014](https://doi.org/10.36347/sjams.2024.v12i05.014)

| Received: 28.03.2024 | Accepted: 04.05.2024 | Published: 16.05.2024

\*Corresponding author: Nagia M. Bushaala

Department of Pediatrics, Faculty of Medicine, University of Benghazi, Libya

## Abstract

## Original Research Article

**Background:** Inhalation of foreign bodies (FBs) is a frequent and adverse condition in the pediatric population. Foreign body aspiration (FBA) is a serious health problem that is sometimes fatal. According to the 2019 data of the National Safety Council (NSC), deaths associated with FBA are the fourth most common preventable accident between the ages of 0–4 years. **Aim:** The study aimed to retrospectively inspect foreign body aspiration (FBA) among children by focusing on symptoms, physical and radiological examination and complications. **Method:** This was a retrospective study (case series) conducted at Benghazi Children's Hospital in a period from 1st. October 2020 to 1st. October 2022 that included all children under 15 years old who underwent rigid bronchoscopy for suspected foreign body aspiration. **Results:** A total of 131 patients who underwent bronchoscopy were included in this study. The mean age of the studied group was (3.5±3.4 years) ranged from 2 months to 15 years. The FBA was most common (50, 38.17%) in the age group (1-3 years), followed by children aged <1 year (38, 29.01%), and less common in patients aged >10 years (8, 6.11%). The FBA was slightly higher in females (73, 55.73 %) than males (58, 44.27%). The history of FBA and the presence of FB in bronchoscopy were witnessed in the majority of cases: (108, 82.44%) and (117, 89.31%) respectively. The majority of removed FB were organic in nature (83, 70.94 %) with the predominance of peanuts (33, 39.76%), and seeds (21, 25.30%). Most of FB is located in the right main bronchus (46, 51.69%) followed by the left main bronchus (16, 17). A large number of cases (83, 72.82%) took more than two days (48 hours) between aspiration and the removal of a foreign body. Cough was the most common symptom (100, 77.5%), followed by choking (88, 68.2%), then breathlessness (61, 47.3%), and the other cases presented the following symptoms in decreasing order: wheezing, cyanosis, fever, grunting, seizure, dysphagia, hoarseness, and drooling. The physical examination of admitted cases showed that diminished air entry was found in nearly three-quarters of cases (86, 71.7%), followed by unilateral wheeze. Crepitation was only found in seventeen cases (14.2%). Finally, twenty-eight cases had no sign during physical examination, and only nine cases (7.5%) had stridor. The chest X-ray was normal in more than half of the cases (58, 45.7%), then followed by hyperinflation, scattered opacity and radio-opaque foreign bodies in descending order: (31, 24.4%), (28, 22%) and (19, 15.0%) respectively. Finally, in the association correlation, there was statistically significant association between the presence of foreign bodies and stridor and history of FBA. There were statistically significant association between gender and cough, breathlessness, diminished air entry and hyperinflation. Also, there was a statistically significant association between age under three and cough, fever, choking, diminished air entry, stridor, cyanosis, scattered opacity shift, and radio opaque f.b. A P-value was less than 0.05. **Conclusion:** The morbidity and mortality in FBA can be significantly reduced by early diagnosis and intervention. The education of parents, family members, and babysitters can prevent foreign body aspirations.

**Keywords:** Bronchoscopy, foreign bodies, aspiration, organic, inorganic.

Copyright © 2024 The Author(s): This is an open-access article distributed under the terms of the Creative Commons Attribution 4.0 International License (CC BY-NC 4.0) which permits unrestricted use, distribution, and reproduction in any medium for non-commercial use provided the original author and source are credited.

### 1. INTRODUCTION

Foreign body aspiration in children is a common condition, which may lead to serious complications; it is estimated that it may contribute to 7% of deaths related to trauma in children aged between 1 to 3 years old, reaching almost 40% in infants posing as the most frequent cause of death in this age range (Pietras et al., 2021). Moreover, FBA is the most

common cause of accidental deaths in children less than one year old (Karaaslan & Yildiz, 2019). This problem has not ceased to be a cause of major complications, as severe as death, in low and high-income countries (Mohammad et al., 2015). As very young children cannot express themselves, this causes various problems in the early noticing of FBA (Cui et al., 2020). FBA results in either complete or partial occlusion of the

conducting airways, causing serious clinical events such as pneumonia, bronchiectasis, lung abscess, atelectasis, or even death. The severity of these complications is presumably related to missed or delayed diagnosis and management. Lack of a history of penetration syndrome corresponding to respiratory defense reflexes (expulsive cough and laryngeal spasm) in response to penetration by a foreign body (FB) may veil the physician's suspicion (Fasseeh *et al.*, 2021). The management of FBA in children is dependent on the health care center; there is no universal standard of care. Because the clinical presentation is subtle and the plain chest X-ray has a poor diagnostic value, bronchoscopy is the best diagnostic method, even if invasive (Korlacki *et al.*, 2011). Indeed, there are no radiologic signs that are both highly sensitive and specific for FBA. Rigid bronchoscopy is traditionally considered the procedure of choice because it allows safe ventilation and has a variety of instruments available for extraction. The level of positive bronchoscopic findings is very variable (Haller *et al.*, 2018). Rigid bronchoscopy is a more invasive procedure that requires deeper anesthesia and careful monitoring. The complications associated with rigid bronchoscopy for aspirated FBs are rare but life-threatening; they include pneumothorax, pneumomediastinum, tracheal laceration, subglottic edema or bronchospasm, and hypoxic arrest (Hitter *et al.*, 2010). Flexible bronchoscopy is sometimes used to localize the FB prior to removal by rigid bronchoscopy and to remove FB located peripherally (Goh *et al.*, 2022). A rigid bronchoscope is mostly used for the removal of solid FBs. Undiagnosed and retained FBs may lead to serious complications such as pneumonia, lung abscess, and bronchiectasis (Zhao *et al.*, 2015). Physical examination findings vary according to the foreign body localisation and degree of obstruction. Foreign bodies causing obstruction in the trachea can cause wheezing. Foreign bodies forming an obstruction in the right or left main bronchus prevent ipsilateral respiratory sounds from being heard. If air is trapped on the side where the foreign body is, unilateral hyperinflation is seen on X-ray. A very small proportion of foreign bodies aspirated in early childhood are radio-opaque and therefore it is not possible to visualize the foreign body on an X-ray in most cases (Salih *et al.*, 2016).

## 2. OBJECTIVES OF THE STUDY

This study aimed to know:

- The prevalence of FBA in child aged 0-15 years.
- The common sign and symptoms at presentation.
- The results of physical and radiological examinations.
- The bronchoscopy findings.
- The types and sites of FBA.
- The complications.

## 3. METHODOLOGY

### Study Design

This was a retrospective study (case series) conducted at Benghazi Children's Hospital in a period from 1st. October 2020 to 1st. October 2022.

### Subjects and Sampling

All children under 15 years old who underwent rigid bronchoscopy for suspected foreign body aspiration were included in this study.

### Data Collection

The Benghazi Children Hospital medical records of recruited children were retrospectively reviewed in a period of two years. A total of 168 cases were admitted for foreign body aspiration in this period, of which seven cases transferred to other departments, and 30 cases were kept for observation and discharged without bronchoscopy. The rest 131 who underwent bronchoscopy were included in this study. The data collected using a questionnaire included the following variables: age, gender, history of foreign body aspiration, bronchoscopy result, type of foreign body, organic foreign body, inorganic foreign body, site of foreign body, time taken between aspiration and the removal of foreign body. The rest of data included the clinical symptoms, physical examination findings (sign), radiological features, the complications of foreign body aspiration and bronchoscopy outcome.

### Statistical Analysis

The collected data, taken history, conditions on admission, physical examination findings, radiological features and bronchoscopic findings, nature and location of the FB, and management outcomes were coded, entered, double-checked, analyzed, and statistically presented using the software statistical package (SPSS), version 22 (SPSS, Chicago, IL, USA). The numerical data were presented as mean±standard deviation (SD). The categorical data were presented as numbers and percentages. The chi-square test was applied to investigate the association between categorical variables. Alternatively, the Fisher's exact test was applied when the expected cell counts were less than 5. A p value < 0.05 was considered statistically significant.

## 4. RESULTS

### The Demographic and Bronchoscopy Findings of the Cases

All the demographic and bronchoscopy findings of the cases were presented in Table.

**Age:** In our study, the mean age of the studied group was (3.5±3.4 years) (2 months-15 years). The median age of studied group was 2 years and the interquartile range (IQR) was (1-5). Foreign body aspiration was most common (50, 38.17%) in age group (1-3 years), followed by children aged less than one year (38, 29.01%). Foreign body aspiration was less common in patients

aged more than ten years (8, 6.11%). The number of children who witnessed FBA in age groups (4-6 years)

and (7-10 years) was (22, 16.79%) and (13, 9.92%) respectively (Figure 1).

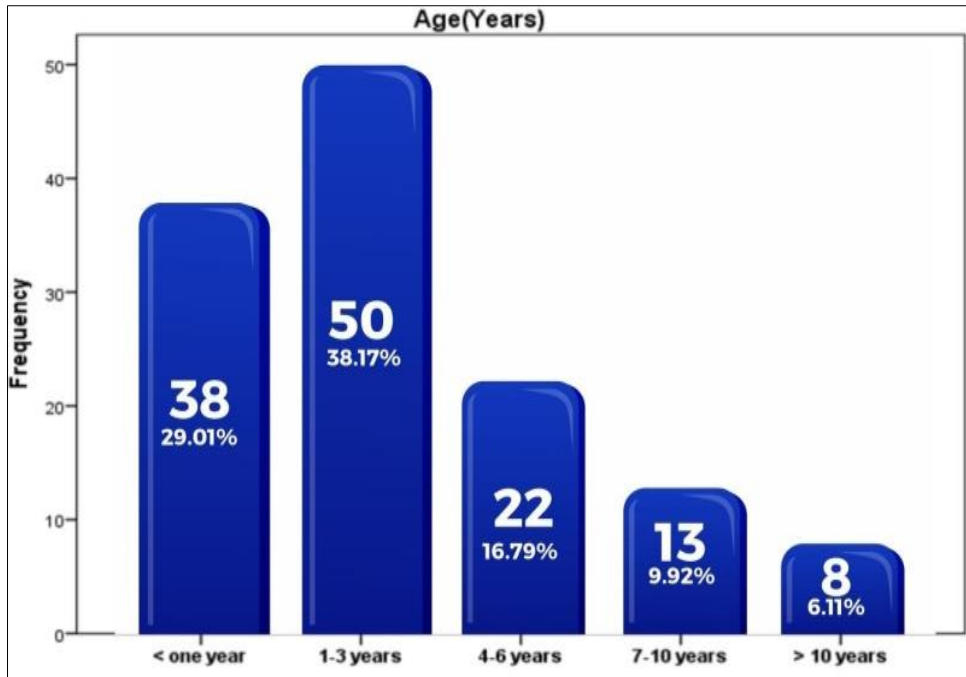


Figure 1: The age distribution of cases

**Gender:** The distribution of gender between the children witnessed FBA was slightly higher in females (73, 55.73%) than males (58, 44.27%) (Figure 2).

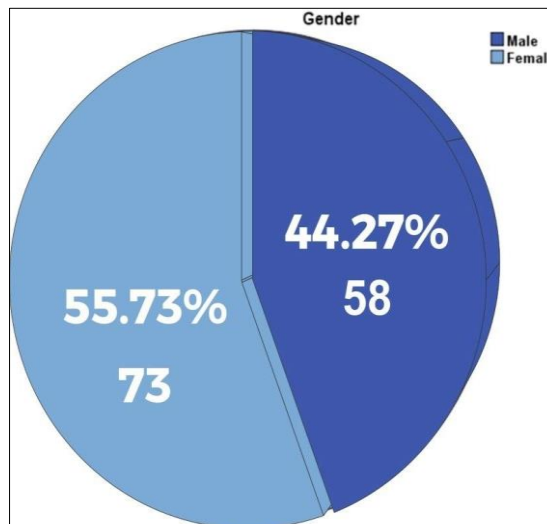


Figure 2: The gender distribution of cases

**History of Foreign Body Aspiration**

The previous history of foreign body aspiration was witnessed in the majority of cases (108, 82.44%) as

compared to only twenty-three of cases (17.56%) with no history of foreign body aspiration (Figure 3).

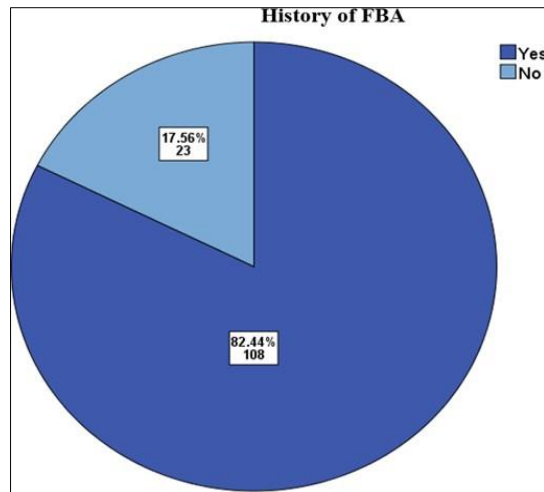


Figure 3: The history of FBA among cases

**Bronchoscopy Result**

The presence of foreign body in the majority of cases (foreign body present) (117, 89.31%). There were

no foreign bodies in the rest of cases (foreign bodies absent) (14, 10.69%) (Figure 4).

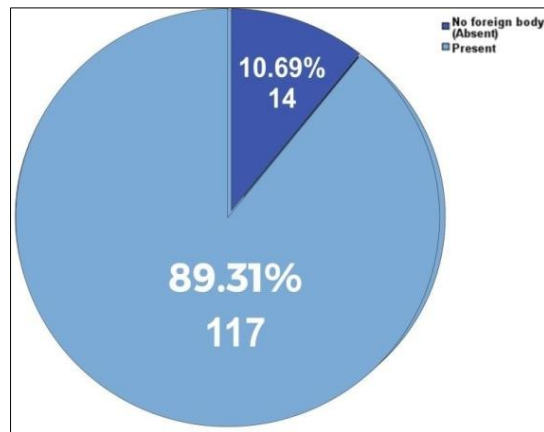


Figure 4: The result of bronchoscopy among cases (presence or absence of foreign body)

**Type of Foreign Body**

In 117 cases where the foreign bodies were found, the aspirated foreign bodies were broadly classified according to their nature into organic and inorganic

types. The majority of removed foreign bodies were organic in nature (83, 70.94%) while the inorganic removed only in thirty four cases (29.06%) (figure 5).

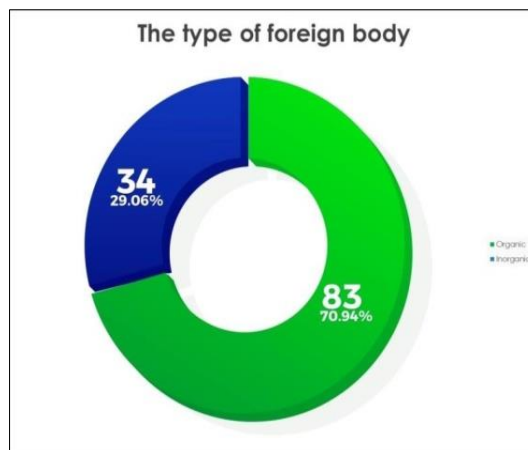


Figure 5: The type of foreign body as per origin among cases

### Organic Foreign Body

In cases where foreign body was found (117), the removed organic foreign bodies include the following substances in decreasing order: peanut (33, 39.76%),

seeds (21, 25.30%), nuts (13, 15.66%), corn (5, 6.02%), almond (4, 4.82%), meat (2, 2.41%), fish bone (2, 2.41%), Chicken bone (1, 1.20%), gum (1, 1.20%) and olive (1, 1.20%) (Figure 6).

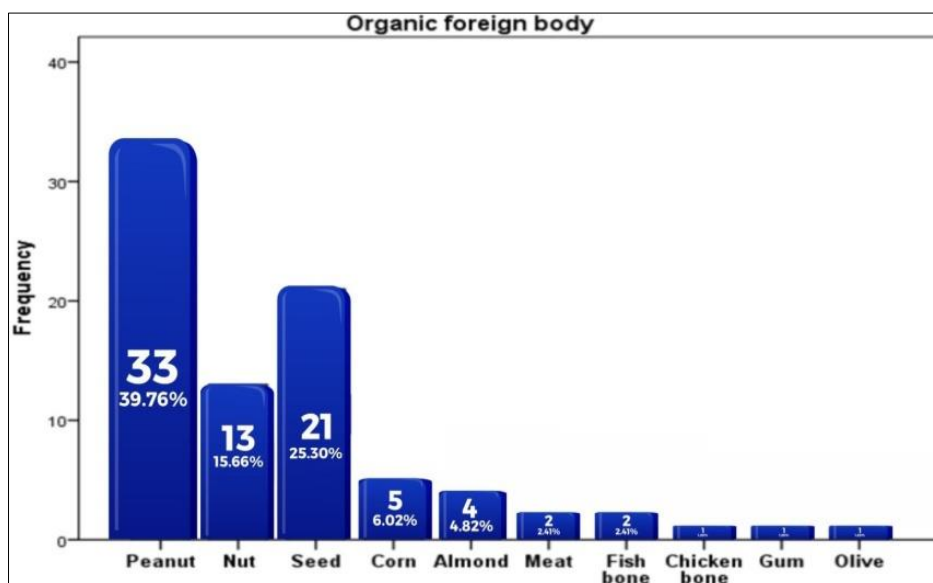


Figure 6: The organic foreign body as per specific sources among case

### Inorganic Foreign Body

In cases where foreign body was found (117), the removed inorganic foreign bodies include the following substances in decreasing order: coins (8, 23.53%), battery (4, 11.76%), plastic pen cap (4, 11.76%), needles

(3, 8.82%), ear rings (2, 2.88%), stones (2, 2.88%), paper (2, 2.88%), metal ball (2, 2.88%), pin (2, 2.88%), wood stick (1, 2.94%), electrical wire (1, 2.94%), screw (1, 2.94%), and button (1, 2.94%) (Figure 7).

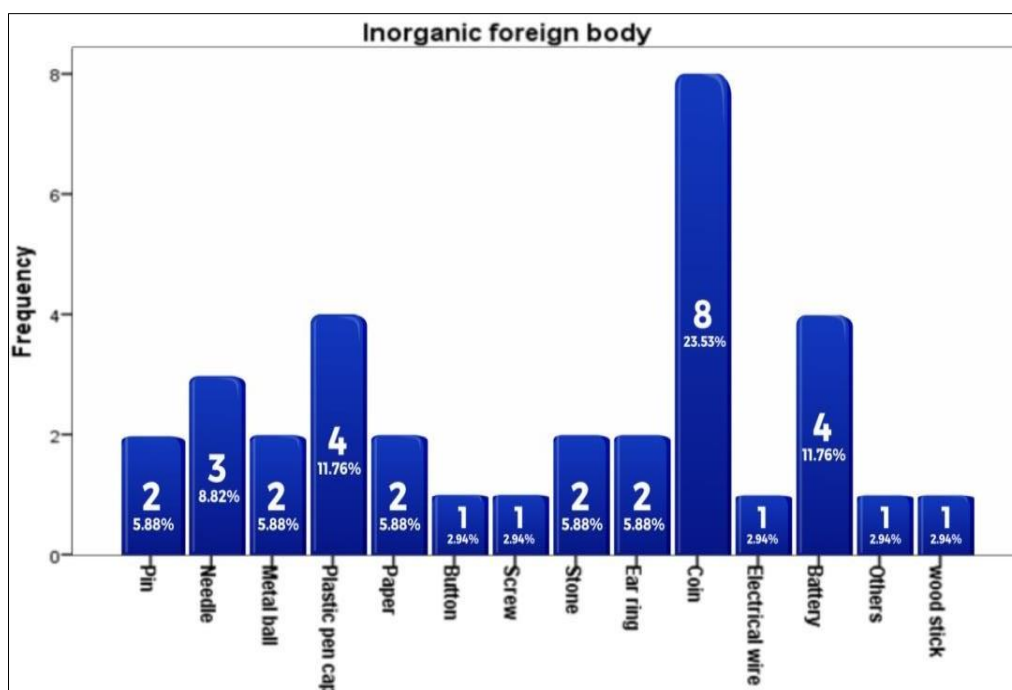


Figure 7: The inorganic foreign body as per specific sources among cases

### Site of Foreign Body

Most of the foreign bodies present in the 117 cases were found in the right main bronchus (46,

51.69%) followed by the left main bronchus (16, 17.98%) and esophagus (13, 14.61%). An equal number of cases reported the removal of foreign bodies from both

the main bronchus and trachea accounting (5, 5.62%) each. The rest of the four cases had foreign body in the following locations: Glottics (2, 2.25%), sub glottic (1, 1.12%) and level of cervical pharynx (1, 1.12%) (Figure

12). Chest X-ray findings of foreign body aspiration cases are presented. In twenty eight cases, insufficient information were mentioned in their files (Figure 8).

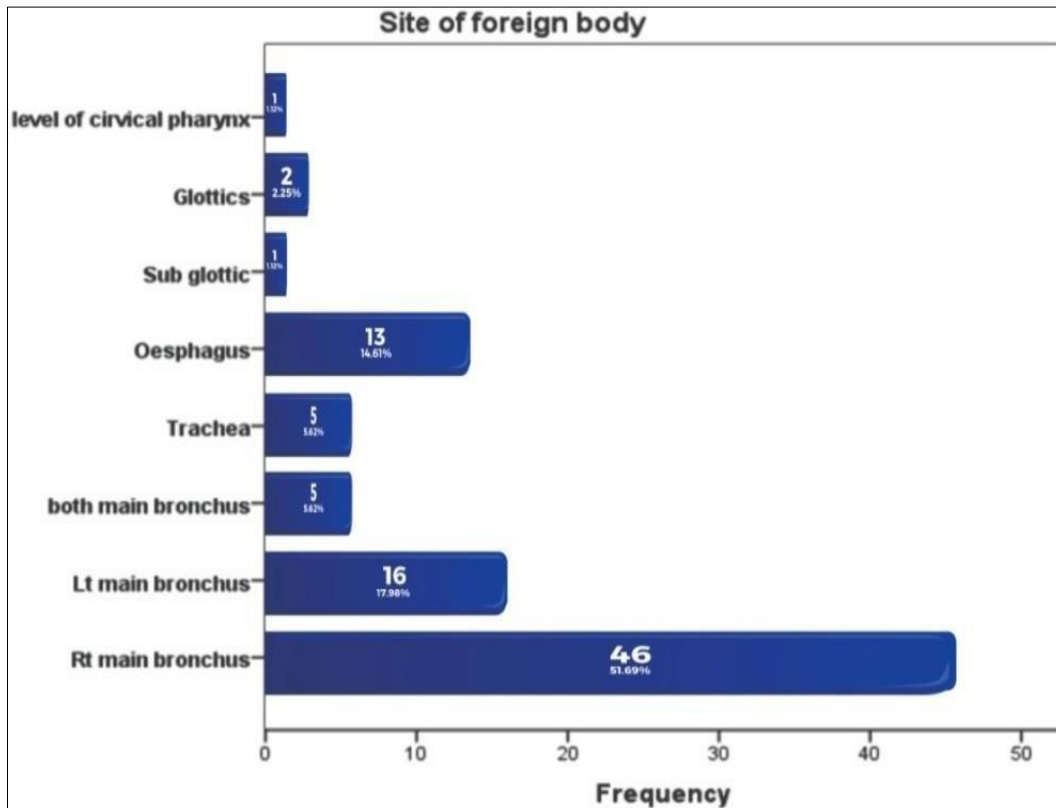


Figure 8: The site of foreign body among study population

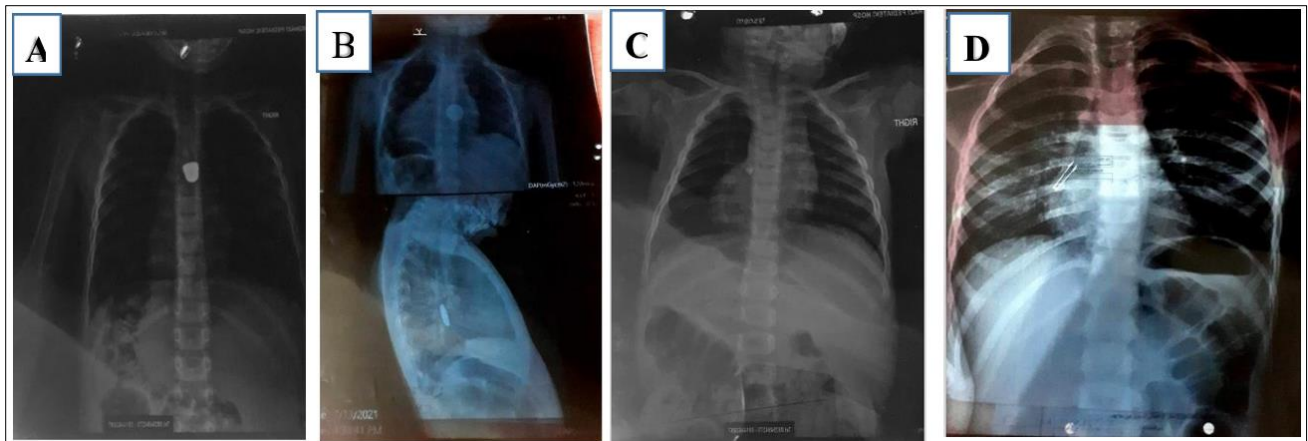


Figure 9: Chest X-ray of foreign body aspiration cases; (A) Coin (B) Battery and; (C) Stone in both main bronchus; (D) Metal piece in left main bronchus

**Time Taken between Aspiration and the Removal of Foreign Body**

In 131 cases were bronchoscopy done, two-thirds (83, 72.81%) of cases, took more than two days (48hr-72hr) between aspiration and the removal of the foreign body. The number of cases who took from one

day (24hr) to two days (48hr) between aspiration and the removal of a foreign body was (19, 16.67%). Finally, the cases that took less than one day (<24hr) were only twelve cases (10.53%). In seventeen cases the time was not mentioned in the files (Figure 10).

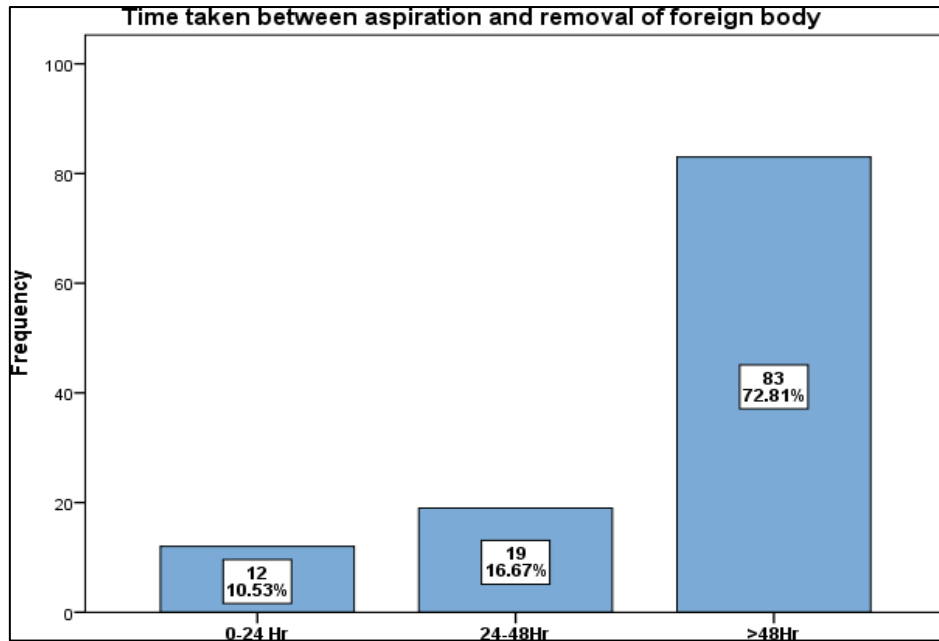


Figure 10: The time taken between aspiration and the removal of foreign body among the studied group

Table 1: The demographic and bronchoscopy findings of cases

Characteristics	Number of cases		
	Frequency (N)	Percent (%)	
<b>Age Median (IQR)</b>	2(1-5)		
<b>Age (years) n= (131)</b>	< one year	38	29.0
	1-3 years	50	38.2
	4-6 years	22	16.8
	7-10 years	13	9.9
	> 10 years	8	6.1
	<b>Total</b>	<b>131</b>	<b>100</b>
<b>Gender n= (131)</b>	Male	58	44.3
	Female	73	55.7
	<b>Total</b>	<b>131</b>	<b>100</b>
<b>History of F.B aspiration n= (131)</b>	Yes	108	82.4
	No	23	17.6
	<b>Total</b>	<b>131</b>	<b>100</b>
<b>The result of bronchoscopy (present or absent) n= (131)</b>	No foreign body (Absent)	14	10.7
	Present	117	89.3
	<b>Total</b>	<b>131</b>	<b>100</b>
<b>The type of foreign body n= (117)</b>	Organic	83	70.94
	Inorganic	34	29.06
	<b>Total</b>	<b>117</b>	<b>100</b>
<b>Organic foreign body n= (117)</b>	Peanut	33	39.8
	Nut	13	15.7
	Seed	21	25.3
	Corn	5	6.0
	Almond	4	4.8
	Meat	2	2.4
	Fish bone	2	2.4
	Chicken bone	1	1.2
	Gum	1	1.2
	Olive	1	1.2
	<b>Total</b>	<b>83</b>	<b>100</b>
<b>Inorganic foreign body n= (117)</b>	Pin	2	5.9
	Needle	3	8.8
	Metal ball	2	5.9

Characteristics	Number of cases		
	Frequency (N)	Percent (%)	
	Plastic pen cap	4	11.8
	Paper	2	5.9
	Button	1	2.9
	Screw	1	2.9
	Stone	2	5.9
	Ear ring	2	5.9
	Coin	8	23.5
	Electrical wire	1	2.9
	Battery	4	11.8
	Others	1	2.9
	Wood stick	1	2.9
	<b>Total</b>	<b>34</b>	<b>100</b>
<b>Site of foreign body n= (117)</b>	Right main bronchus	46	51.7
	Left main bronchus	16	18.0
	both main bronchus	5	5.6
	Trachea	5	5.6
	Esophagus	13	14.6
	Sub glottis	1	1.1
	Glottis	2	2.2
	Level of cervical pharynx	1	1.1
	<b>Total</b>	<b>89*</b>	<b>100</b>
<b>Time taken between aspiration and the removal of foreign body n= (131)</b>	0-24 Hrs	12	10.5
	24-48 Hrs	19	16.7
	>48 Hrs	83	72.8
	<b>Total</b>	<b>114**</b>	<b>100</b>

\*= 28 cases were with insufficient information, \*\*= seventeen cases were with missing data.

### Clinical Symptoms

**Table 2: Clinical symptoms among the studied population**

Symptoms	Number of cases	
	Frequency (N)	Percent (%)
Cough	100	77.5*
Chocking	88	68.2
Breathlessness	61	47.3
Vomiting	36	27.9
Fever	26	20.2
No symptoms	8	6.2
Seizure	4	3.1
Dysphagia	4	3.1
Hoarseness	2	1.6
Drooling	2	1.6
Other	2	1.6

\*Multiple response question and answer.

### Physical Examination Findings (sign)

**Table 3: Physical examination (sign) among the studied population**

Physical examination	Number of cases	
	Frequency (N)	Percent (%)
Unilateral Diminished air entry	86	69.9
Unilateral wheeze	53	43.1
Wheeze	35	28.5
Cyanosis	30	24.4
None	28	22.8
Grunting	26	21.1



Physical examination	Number of cases	
	Frequency (N)	Percent (%)
Crepitation	17	13.8
Stridor	9	7.3
Others	3	2.4

**Radiologic Findings**

**Table 4: Radiological findings among the studied population**

Radiologic findings	Number of cases	
	Frequency (N)	Percent (%)
Normal	58	45.7
Unilateral Hyper inflation	31	24.4
Scattered opacity	28	22
Radio opaque F.B	19	15
Consolidation	3	2.4
Collapse	2	1.6
Mediastinal shift	1	0.8

**Table 5: Complications and outcomes among the studied population**

Complications and outcomes	Number of cases	
	Frequency (N)	Percent (%)
Pass without complication	130	99.2
Pass with complication	1	0.8
<b>Total</b>	<b>131</b>	<b>100</b>

**The Association**

**Table 6: Association between demographic, clinical, radiologic findings and the presence of foreign body**

Variables		Foreign body (N, %)		p-value
		Absent N=(14, 10.7%)	Present N=(117, 89.3%)	
<b>Age Median (IQR)</b>		1.5 (1-4)	2 (1-5)	0.288
<b>Gender</b>	Male	7 (50)	51 (43.6)	0.648
	Female	7 (50)	66 (56.4)	
<b>History of aspiration</b>	No(23)	8 (57.1)	15 (12.8)	0.000*
	Yes(108)	6 (42.9)	102 (87.2)	
<b>Symptoms</b>				
<b>Cough</b>	No	3 (21.4)	28 (23.9)	0.835
	Yes	11 (78.6)	89 (76.1)	
<b>Breathlessness</b>	No	9 (64.3)	61 (52.1)	0.389
	Yes	5 (35.7)	56 (47.9)	
<b>Fever</b>	No	9 (64.3)	94 (80.3)	0.124
	Yes	5 (35.7)	21 (17.9)	
<b>Chocking</b>	No	6 (42.9)	37 (31.6)	0.389
	Yes	8 (57.1)	80 (68.4)	
<b>Vomiting</b>	No	9 (64.3)	86 (73.5)	0.465
	Yes	5 (35.7)	31 (26.5)	
<b>Seizure</b>	No	14 (100)	113 (96.6)	0.482
	Yes	NC	4 (3.4)	
<b>Hoarseness</b>	No	14 (100)	113 (96.6)	0.619
	Yes	NC	2 (1.7)	
<b>Dysphagia</b>	No	13 (92.9)	112 (95.7)	0.355
	Yes	1 (7.1)	3 (2.6)	
<b>Drooling</b>	No	13 (92.9)	114 (97.4)	0.073
	Yes	1 (7.1)	1 (0.9)	
<b>Other</b>	No	14 (100)	113 (96.6)	0.619
	Yes	NC	2 (1.7)	

Variables	Foreign body (N, %)			p-value
		Absent N=(14, 10.7%)	Present N=(117, 89.3%)	
<b>Physical examination</b>				
Diminished air entry	No	4 (28.6)	34 (29.1)	0.858
	Yes	10 (71.4)	76 (65)	
Unilateral wheeze	No	10 (71.4)	61 (52.1)	0.255
	Yes	4 (28.6)	49 (41.9)	
Stridor	No	11 (78.6)	104 (88.9)	0.03*
	Yes	3 (21.4)	6 (5.1)	
Crepitation	No	11 (78.6)	96 (82.1)	0.373
	Yes	3 (31.4)	14 (12)	
Grunting	No	10 (71.4)	93 (79.5)	0.406
	Yes	4 (28.6)	22 (18.8)	
Wheeze	No	11 (78.6)	83 (70.9)	0.845
	Yes	3 (21.4)	32 (27.4)	
Cyanosis	No	12 (85.7)	86 (73.5)	0.392
	Yes	2 (14.3)	28 (32.9)	
Normal physical examination	No	11 (78.6)	92 (78.6)	0.996
	Yes	3 (21.4)	25 (21.4)	
<b>Radiologic findings</b>				
Hyper inflation	No	9 (81.8)	88 (75.2)	0.625
	Yes	2 (18.2)	29 (24.8)	
Collapse	No	14 (100)	115 (98.3)	0.622
	Yes	NC	2 (1.7)	
Consolidation	No	14 (100)	114 (97.4)	0.544
	Yes	NC	3 (2.6)	
Scattered opacity	No	8 (57.1)	92 (78.6)	0.651
	Yes	3 (21.4)	25 (21.4)	
Radio opaque F.B	No	10 (71.4)	99 (84.6)	0.575
	Yes	1(7.1)**	18 (15.4)	
Mediastinal shift	No	14 (100)	116 (99.1)	0.728
	Yes	NC	1 (0.9)	
Pneumothorax	No	14 (100)	117 (100)	NC
	Yes	NC	NC	
Normal	No	9 (64.3)	64 (54.7)	0.495
	Yes	5 (35.7)	53 (45.3)	

\*significant at p < 0.05; IQR=interquartile range; NC=Not calculated.

\*\*only one case radiological has radio opaque when done bronchoscopy no FB found

**Table 7: Association between the gender and clinical symptoms, physical examination, and radiologic findings of cases A p-value>0.05 as shown in**

Variables	Gender (N, %)			p-value
		Male N=(58, 44.27%)	Female N=(73, 55.37%)	
Age Median (IQR)		1.5 (1-4)	2(1-5)	0.382
<b>Symptoms</b>				
Cough	No	9 (15.5)	22 (30.1)	0.051
	Yes	49 (84.5)	51 (69.9)	
Breathlessness	No	24 (41.4)	46 (63.0)	0.014*
	Yes	34 (58.6)	27 (37.0)	
Fever	No	45 (77.6)	58 (79.5)	0.563
	Yes	13 (22.4)	13 (17.8)	
Chocking	No	18 (31.0)	25 (34.2)	0.697
	Yes	40 (69.0)	48 (65.8)	
Vomiting	No	42 (72.4)	53 (72.6)	0.981
	Yes	16 (27.6)	20 (27.4)	

Variables		Gender (N, %)		p-value
		Male N=(58, 44.27%)	Female N=(73, 55.37%)	
Seizure	No	57 (98.3)	70 (95.9)	0.431
	Yes	1 (1.7)	3 (1.7)	
Hoarseness	No	56 (96.6)	71 (97.3)	0.115
	Yes	2 (3.4)	2 (2.7)	
Dysphagia	No	57 (98.3)	68 (93.2)	0.415
	Yes	1 (7.1)	3 (4.1)	
Drooling	No	57 (98.3)	70 (95.9)	0.885
	Yes	1 (1.7)	1 (1.4)	
Other	No	57 (98.28)	70 (98.59)	0.885
	Yes	1 (1.7)	1 (1.41)	
<b>Physical examination</b>				
Diminished air entry	No	10 (17.9)	28 (41.2)	0.005*
	Yes	46 (82.1)	40 (58.8)	
Unilateral wheeze	No	28 (50.0)	43 (63.2)	0.138
	Yes	28 (50.0)	25 (36.8)	
Stridor	No	53 (94.6)	62 (91.2)	0.459
	Yes	3 (5.4)	6 (8.8)	
Crepitation	No	46 (82.1)	61 (89.7)	0.223
	Yes	10 (17.9)	7 (10.3)	
Grunting	No	45 (77.6)	58 (81.7)	0.563
	Yes	13 (22.4)	13 (18.3)	
Wheeze	No	39 (67.2)	55 (77.5)	0.194
	Yes	19 (32.8)	16 (22.5)	
Cyanosis	No	40 (69.0)	58 (82.9)	0.065
	Yes	18 (31.0)	12 (17.1)	
Normal physical examination	No	58 (100)	73 (100)	NC
	Yes	NC	NC	
<b>Radiologic findings</b>				
Hyper inflation	No	36 (62)	61 (84.7)	0.007*
	Yes	20 (38)	11 (15.3)	
Collapse	No	56 (96.6)	73 (100)	0.110
	Yes	2 (3.4)	0 (00)	
Consolidation	No	56 (96.6)	72 (98.6)	0.430
	Yes	2 (3.4)	1 (1.4)	
Scattered opacity	No	42 (96.4)	58 (97.3)	0.451
	Yes	14 (3.6)	14 (1.4)	
Radio opaque F.B	No	50 (75)	59 (80.6)	0.246
	Yes	6 (25)	13 (19.4)	
Mediastinal shift	No	57 (98.3)	73 (100)	0.260
	Yes	1 (1.7)	0 (00)	
Pneumothorax	No	58 (100)	73 (100)	NC
	Yes	NC	NC	
Normal	No	36 (62.1)	37 (50.7)	0.193
	Yes	22 (37.9)	36 (49.3)	

\*significant at  $p < 0.05$ ; IQR=interquartile range; NC=Not calculated.

#### Association between Age and Clinical Symptoms, Physical Examination, and Radiologic Findings of Cases

**Table 8: Association between the age and clinical symptoms, physical examination, and radiologic findings of cases the p-value>0.05 as shown in**

Variables		Age (years) (N, %)		p-value
		Age more than three N=(43, 32.8%)	Age less than three N=(88, 67.2%)	
Gender	Male	17 (39.5)	41 (46.6)	0.445
	Female	26 (60.5)	47 (53.4)	

Variables	Age (years) (N, %)			p-value
		Age more than three N=(43, 32.8%)	Age less than three N=(88, 67.2%)	
<b>Symptoms</b>				
Cough	No	19 (44.2)	12 (13.6)	0.000*
	Yes	24 (55.8)	76 (86.4)	
Breathlessness	No	27 (62.8)	43 (48.9)	0.133
	Yes	16 (37.2)	45 (51.1)	
Fever	No	38 (90.5)	65 (74.7)	0.036*
	Yes	4 (9.3)	22 (25.3)	
Chocking	No	20 (46.5)	23 (26.1)	0.02*
	Yes	23 (53.5)	65 (73.9)	
Vomiting	No	28 (65.1)	67 (76.1)	0.185
	Yes	15 (34.9)	21 (23.9)	
Seizure	No	40 (93)	87 (98.9)	0.068
	Yes	3 (7)	1 (1.1)	
Hoarseness	No	41 (97.6)	86 (97.7)	0.596
	Yes	1 (2.4)	1 (1.1)	
Dysphagia	No	39 (92.9)	86 (97.7)	0.066
	Yes	3 (7.1)	1 (1.1)	
Drooling	No	41 (97.6)	86 (98.9)	0.596
	Yes	1 (2.4)	1 (1.1)	
Other	No	41 (97.6)	86 (98.9)	0.596
	Yes	1 (2.4)	1 (1.1)	
Diminished air entry	No	16 (43.2)	22 (25.3)	0.047*
	Yes	21 (56.8)	65 (73.9)	
Unilateral wheeze	No	25 (67.6)	46 (52.9)	0.130
	Yes	12 (32.4)	41 (46.6)	
Stridor	No	37 (86)	78 (89.7)	0.042*
	Yes	NC	9 (10.3)	
Crepitation	No	35 (94.6)	72 (82.8)	0.08
	Yes	2 (5.4)	15 (17.2)	
Grunting	No	37 (88.1)	66 (75.9)	0.105
	Yes	5 (11.9)	21 (24.1)	
Wheeze	No	34 (81)	60 (69)	0.151
	Yes	8 (19)	27 (31)	
Cyanosis	No	37 (88.1)	61 (70.9)	0.031*
	Yes	5 (11.9)	25 (29.1)	
<b>Radiologic findings</b>				
Hyper inflation	No	34 (79.1)	63 (74.1)	0.537
	Yes	9 (20.9)	22 (25.9)	
Collapse	No	42 (97.7)	87 (98.9)	0.602
	Yes	1 (2.3)	1 (1.1)	
Consolidation	No	43 (100)	85 (96.6)	0.221
	Yes	0 (00)	3 (3.4)	
Scattered opacity	No	40 (93)	60 (70.6)	0.004*
	Yes	3 (7)	25 (29.4)	
Radio opaque F.B	No	28 (65.1)	81 (95.3)	0.000*
	Yes	15 (34.9)	4 (4.7)	
Mediastinal shift	No	43 (100)	87 (98.9)	0.483
	Yes	NC	1 (1.1)	
Pneumothorax	No	43 (100)	88 (100)	NC
	Yes	NC	NC	
Normal	No	27 (62.8)	46 (52.3)	0.255
	Yes	16 (37.2)	42 (47.7)	

\*significant at  $p < 0.05$ ; IQR=interquartile range; NC=Not calculated.

## 5. DISCUSSION

Accidental inhalation of foreign bodies (FBs) is a worldwide health problem, and if the diagnosis is not made on time and treatment is not introduced early, it may be a frequent cause of morbidity and occasional mortality. It is well known that before the development of bronchoscopy, the mortality rate was 50%, whereas it is now <1% (Bittencourt *et al.*, 2006).

In this study, a total of 131 children who were admitted to Benghazi Children Hospital and underwent rigid bronchoscopy for the removal of foreign bodies in the airways were evaluated. The mean age of the studied group was (3.5±3.4 years) (2 months-15 years). While, the median age was 2 years and the interquartile range (IQR) was 4 (1-5). The foreign body aspiration was most common (50, 38.17%) in the age group (1-3 years), followed by children aged less than one year (38, 29.01%) that the majority of children were involved in age groups less than 1 to 3 years (88, 67.11%) followed by children in the age group (4-6) years (22, 16.79%). This result came in accordance with the result of Budhiraja *et al.*, (2021) study, which found that most common age group involved was between 0 and 3 years (44%), followed by 3–6 years (22%). Also, in the study of Sav *et al.*, (2021), the majority of cases (25, 71%) were less than 3 years old. Also, Rashi *et al.*, (2020) study results emphasize our results that the most common age group was between 1 and 3 years, representing 54% of cases., in the result of Alhomsy (2020) study, patients between one to two years old were the most common age group for FBA with 38.3%, and this was different from our study results.

In the work of Jan & Kamil (2021), the mean age of cases was 4.52±6.35 years. This result was different from our result that the mean age of cases was (3.5±3.4 years). Also, Puja *et al.*, (2017) found that the youngest child to aspirate was 6 months of age whereas maximum age documented was 12-year-old. This result was slightly different from our study result. Meanwhile, Pietras *et al.*, (2021) found that the average age of patients was 2.92 years among the study patients, 49 (74.24%) were no older than 3 years of age at the time of the procedure which was near to our results. On the other hand, the study of Reyad *et al.*, (2021) included 130 patients younger than 16 years-old who underwent rigid bronchoscopy for suspected foreign body aspiration, and their median age was 2.0 (IQR = 1.2–3.0) years. These results were identical to this study' results. Aydoğan *et al.*, (2006) stated in their study that the ages of cases ranged from 5 days to 16 years with a median age of 2.3 years (74%) of patients were less than 3 years old which is in agreement with our study result. Also, the results of Fasseeh *et al.*, (2021) showed that of the 203 patients (age ranging between 4 months and 15 years, mean = 2.99 years). FBA was most frequent in the age group 1–2 years, followed by 2–3 years (26.6 and 20.2%, respectively) with a median age of 2.6 years (IQR = 1.5–4.5) that was in accordance with this study' results. In the

study of Brkic *et al.*, (2018), they argued that children under 3 years of age account for the majority of cases. Reasons for this include the lack of molar teeth and poorer mastication, a tendency to put things in the mouth, crying, running, or playing with objects in the mouth, and less mature protective laryngeal reflexes (Safari & Manesh. 2016). In this study, females (73, 55.73 %) was more prevalent than males (58, 44.27%). This result was opposite to the results of Budhiraja *et al.*, (2021) study which stated males 34 (68%) were more than females 16 (32%) with the male to female ratio being 2:1. Also, the results of Jan & Kamil, (2021) (3) found that 65 (72.2%) were males and 25 (27.8%) were females and the study of Alhomsy (2020), stated that males were more common than females. Meanwhile, Sav *et al.*, (2021), stated that of the 35 patients included in the study, 19 (54%) were boys and 16 (46%) were girls. Also, Aydoğan *et al.*, (2006) mentioned that among the cases, there were 1106 boys (58.6%) and 781 girls (41.4%). The presence of a foreign body was proved by bronchoscopy in the majority of cases (117, 89.31%). While, there were no foreign bodies in the rest of the cases (14, 10.69%). This result was comparable to the study by Alhomsy (2020) that all 314 cases with FBAs had a bronchoscopy and 80% of them had positive results (FBs found), while 20 had a negative bronchoscopy (no FBs found). Also, in the study of Aydoğan *et al.*, (2006), in the bronchoscopy, a FB was identified in 79.1% of patients and no FB was seen in 20.9% of patients. In addition, in the Reyad *et al.*, (2021) study, the results showed that out of the studied patients, 105 (80.8%) showed the presence of a foreign body in the airway, which was successfully removed by rigid bronchoscopy. Fraga *et al.*, (2008), mentioned that during bronchoscopy, the foreign body was identified and removed in 60 cases (87%). In another 9 (13%), there were indirect signs, such as edema, hyperemia of bronchial mucosa and presence of secretion. However, the foreign body was not found (maybe coughed out). Conversely, Pietras *et al.*, (2021) in their study found that in 24 cases (36.36%), no foreign body was identified during rigid bronchoscopy, while in the remaining 42 cases (63.64%), foreign body was present in the airways. Also, Puja *et al.*, (2017) in their work stated that FBA was verified in 139 (68.5%) patients. These were different from our study results. In our study, the previous history of foreign body aspiration was witnessed in the majority of cases (108, 82.44%) as compared to only twenty-three of cases (17. 56%) with no history of foreign body aspiration. The result of Mohsen *et al.*, (2021) study had a similar result to our study results that a total of 453 (80.9%) patients had an explicit history of FBA. Whereas, Puja *et al.*, (2017) in their study stated that when detailed histories were taken, it was found that only 47% cases had a definite history of aspiration as compared to 53% cases where there was no history of aspiration. These findings were not comparable to our study results. In the current study, organic foreign bodies were more common than inorganic FB. The peanut (33, 39.76%) was the most abundant FB, followed by other organic FB. This result

was consistent with Budhiraja *et al.*, (2021) study results that the most common type of FB found was organic with peanuts being the commonest (48%). Also, Eren *et al.*, (2003) stated in their cohort study, there was a higher incidence of organic (vegetable) foreign bodies (FBs) (192 patients) than inorganic ones (20 patients). Thus, this result deduced that the main responsible factor is the consumption of inappropriate food. Mohsen *et al.*, (2021) in their study revealed that organic matter 467 (83.4%) was the most frequent FB. Seeds 273 (48.8%) and peanuts 101 (18%) were the most common forms of organic matter. Other organic matter included: apple peel, carrot pieces, popcorn, and peas. This study is comparable to our study in that the organic foreign bodies more common than inorganic and different in that in our study peanuts are more common than seeds. Also, the Mohsen *et al.*, (2021) in their study showed that non-organic matter 71 (12.7%), metal and plastic objects, represented a minority of cases, which was identical to our results study. Mohsen *et al.*, (2021) mentioned in their study that seed aspiration is a particularly complex clinical situation, as they contain volatile oils that can cause rapid bronchial damage, along with the volume expansion of the seeds in the bronchus due to imbibition which can lead to the complete obstruction of the airways. Conversely, Rashi *et al.*, (2020), found in their work that 12 cases (80%), were aspirated inorganic materials while in the remaining three, there were organic materials. they reported black Bengal gram, mucus plugs, and peanut as organic matter and spring, earring, pen cover, whistle, metal screw, iron nail, nose pin, charger pin, brush head, and ice cream spoon as inorganic materials. As mentioned in the work of Bittencourt *et al.*, (2006), nuts and vegetable foreign bodies prevailed over other causative agents and the kind of aspirated food varied according to country and regional diet habits. Also, Sultan & Van, (2016) mentioned that although the spectrum of FBs varies from country to country, depending on the diet and customs of the population, the most common foreign body aspiration (FBA) causing injuries are from diminutive food items. In Budhiraja *et al.*, (2021) work, FB were located in the right bronchus of 32 (64%) patients, the left bronchus of 12 (24%) patients, and the trachea of 6 (13.04%) patients. This finding was similar to our study in that most foreign bodies were found in the right main bronchus (46, 51.69%) followed by the left main bronchus (16, 17.98%). An equal number of cases reported the removal of foreign bodies from both main bronchus and trachea their explain right main bronchus is significantly wider and steeper than left main bronchus (Ramos *et al.*, 2016) location depend on the patient age and position at time of aspiration. Similar results were reported by Reyad *et al.*, (2021) in their work, that the right main bronchus, left main bronchus, lower trachea, and subglottic area were the most frequent (43.8%, 21.0%, 14.3%, and 12.4%, respectively). Also, Mohsen *et al.*, (2021) revealed that the right main bronchus 255 (40.2%) was the most frequent site of lodgment, followed by left main bronchus 159 (28.4%), trachea 79 (14.1%), and larynx

47 (8.4%). As well as, the study of Sav *et al.*, (2021) found that the most common localization of the foreign body was in the right main bronchus (62%). The other localizations were in the left main bronchus, trachea and both bronchi. Both Daroszewski *et al.*, (2013) and Tahir *et al.*, (2009) in their work explained that the right main bronchus is significantly wider and steeper than the left main bronchus, and the position of the carina to the left of the mid-trachea may be a much more important factor, since this increases the catchment area of the right main bronchus. Conversely, in the study of Rashi *et al.*, (2020), they observed that the right bronchus is the most common (60%) site of the aspirated FB followed by the left bronchus in 27% of cases. Also, Jan & Kamil, (2021), found that the right main bronchus was the most common foreign body 50 (55.5%) followed by the left bronchus 35(38.9%) and trachea found in 5 (5.6%). The time lag between the episode and the bronchoscopy is very important to avoid morbidity and even the mortality of the procedure (Aydoğan *et al.*, 2006). In current study, a large number of cases (83, 72.82%) that took more than two day (48hr) between aspiration and the removal of foreign body. Also, the cases who took less than one day (<24hr) were only twelve cases (10.53%). This result was consistent with the result of Budhiraja *et al.*, (2021) study, which found that the majority of children presented to the hospital after 3 days of aspiration and only five cases (10%) were brought to the hospital within a day of FBA. Also, Rashi *et al.*, (2020) stated similar results to this study in which the most common duration of the presentation after aspiration of a FB was within 3 days. Only one case presented within 24 h of aspiration, while two cases were reported after 5 months. On the other hand, the study of Aydoğan *et al.*, (2006) found the opposite result to our study that 823 patients (43.6%) were referred to our clinic within the first 24 h of the event while 4.7% of the patients were admitted to the hospital with the suspicion of FB in the airway later than 1 month. Also, Puja *et al.*, (2017) revealed that most of the patients with definitive histories reported immediately to the hospital. Maximum number of patients reported in the first 48 h of aspiration. One patient underwent bronchoscopy after one year. The inhalation of objects obstructing the airways can result in significant morbidity and mortality. So, the diagnosis of these accidents is crucial for the outcomes and management of these patients (Mohsen *et al.*, 2021). Aspirated FBs in children may be difficult to diagnose. Some patients have alarming symptoms of respiratory distress and present with urgent clinical problems, while others present with a chronic respiratory illness. A careful history and physical examination were strong indicators of the diagnosis and raised the index of suspicion of an aspirated foreign body. The rapid fatigue of cough reflex and the following asymptomatic phase tend to create a false sense of security, and the parents might forget the choking episode or consider it not so important to mention when the symptoms return. Misdiagnosis and the lack of suspicion on the part of physicians contribute significantly to the delay (Aydoğan

*et al.*, 2006). In this study, the common symptoms among our studied cases were cough (100, 77.5%), followed by choking among nearly two-thirds of cases (88, 68.2%), and followed by breathlessness among nearly half of cases (61, 47.3%) in decreasing order. This result was identical for cough in the study of Budhiraja *et al.*, (2021) and different for the order of other symptoms in that the clinical features of these patients were mainly cough, respiratory distress, wheeze, fever, stridor, choking and cyanosis in decreasing order. The same was true for Reyad *et al.*, (2021) study where the most frequent symptoms were sudden onset cough (30.0%) and breathlessness (21.5%). Choking and hoarseness were less common (6.9% and 0.8%, respectively). Comparable results were found in Fraga *et al.*, (2008) study in which among the clinical findings, a history of choking and sudden-onset cough was present in 52 (75.4%) patients. Also, Puja *et al.*, (2017) revealed that among the symptoms presented, the sudden onset of cough was most common presenting symptom followed by breathlessness. Fever was present in 43% of children. Few children presented with symptoms of asphyxiation such as choking, seizures and grunting. In this study, the physical examination showed that diminished air entry was found in nearly three-quarters of cases (86, 71.7%) followed by unilateral wheeze in thirty- five cases (53, 44.2%). This results were opposite to the results of Sav *et al.*, (2021) study, that wheezing and rales were detected in 24 patients (68%), diminished breath sound was found in 17 patients (48%) and 5% of patients (n = 2) had no pathological breath sound. Conversely, the study of Puja *et al.*, (2017) showed identical results to our study that, unilateral diminished air entry was the most common sign found followed by wheeze/ronchi. In our work, the radiological findings of studied cases showed that chest X-ray was normal in more than half of the cases (58, 45.7%), then followed by hyperinflation, scattered opacity and radio-opaque foreign bodies in descending order: (31, 24.4%), (28, 22%) and (19, 15.0%) respectively. The study of Budhiraja *et al.*, (2021) showed that only 6% of aspirated FB patients are spot diagnosed on X-ray chest as they were radio-opaque. Majority of patients X-ray-Chest showed emphysema in 48%, atelectasis and pneumonitis in 18% cases and 32% cases has normal X-ray-Chest findings. Similarly, in our study the x-ray of aspirated patients only diagnosed (21, 16%) by showing radio opaque foreign body. The other radiological features were different from our study. Our result were different to Fraga *et al.*, (2006) study that they revealed that a simple chest X-ray was conducted in 67 cases, and 8 (11.9%) presented no alterations. The most common finding was atelectasis (26 cases; 38.8%) Other alterations were hyperinflation (16 cases; 23.9%), lung parenchyma opacity (10 cases; 14.9%) and deviation of the trachea (9 cases; 13.4%). In 15 cases (22.4%), the foreign body was visible. It was found in this study that almost all cases had no complication except than one. This result was comparable to the result of Sav *et al.*, (2021) study in which no complication was detected in 92% of the

patients (n = 32) after bronchoscopy. There was no significant difference between age and the presence of foreign body. Correspondingly, the Pietraś *et al.*, (2021) study stated that the average age of patients who aspirated organic foreign bodies was 2.44 years old, while average age of patients who aspirated inorganic foreign bodies was 4.88 years old. The observed disparity was not statistically significant ( $p > 0.05$ ). Our result was different from the study of Fasseeh *et al.*, (2021) that demonstrates significant associations between the presence of a FB in the airways and age, witnessed choking episodes, sudden cough onset, new onset or recurrent wheeze, and the presence of unilateral diminished breath sounds, respiratory distress, and wheezes on the chest examination. In addition, the manifestation of radiographic abnormalities, unilateral chest hyperinflation, or radiopaque shadows was significantly associated with positive FBA ( $p < 0.05$ ). As stated in the Reyad *et al.*, (2021) study, the presence of chest X- ray abnormalities did not reveal a significant association with the detection of a foreign body ( $p = 0.361$ ). This result was identical to our results. In the study of Sav *et al.*, (2021) the association between the symptoms and findings of the patients and age (under and above) three years of cases showed no association ( $P\text{-value} > 0.05$ ), which was different from our study results that there were associations between cough, fever, choking, diminished air entry, stridor, cyanosis, scattered opacity shift, and radio opaque f.b.

## 6. CONCLUSION

FB aspiration is common in children and can be a life threatening event. a careful history and physical examination are important for early diagnosis and intervention. The majority of cases were less than three years old with a slight increase in the distribution of female over male gender. The organic foreign bodies were more predominant over the inorganic indicating that foods were the most common causative agents' of aspiration. Cough was the most common symptoms followed by choking and breathlessness. The physical examination showed that diminished air entry was the most common findings, then unilateral wheeze. The chest X-ray was normal in most cases although the foreign body were found in majority of cases indicating that rigid bronchoscopy must be performed in all suspected cases. Only one case had complication following bronchoscopy.

## 7. RECOMMENDATION

- It is essential for the physician to have a high index of suspicion, mainly in patients with acute onset of respiratory distress, especially with unilateral decrease in air entry.
- Bronchoscopy should be done in any case suspected history of FB aspiration
- Education of the public (caregivers, parents, and families) is the best preventive measure for decreasing the frequency of this problem.

- Parents, caregivers, and other family members should be educated to avoid feeding nuts and seeds to young children who cannot grind smaller inhalable pieces effectively as they do not have premolars or molars. They can be given in powdered form.
- The aspiration of inorganic foreign bodies is less frequent and requires additional preventive measures, as it can happen in older children. Therefore, it is important to avoid leaving small things on the floor or within reach of children.
- Toys should be selected according to the age of children; they should be given toys that do not have small and detachable parts.

- Finally, the places where the children spend most of their time must be checked.

## 8. LIMITATIONS

This study was limited by some factors, most of cases were observation during the period of the study...some cases leave hospital before done bronchoscopy some cases procedure done but no information or complete data about bronchoscopy finding. This study was based on retrospective review of cases files that had many missing data for different variables included in the study.

## LIST OF ABBREVIATIONS OR SYMBOLS

Abbreviation of symbols	Meaning
CT	Computed Tomography
ENT	Ear, Nose and Throat
ETT	Endotracheal Tube
FBA	Foreign Body Aspiration
FBs	Foreign Bodies
FOB	Flexible Fiberoptic Bronchoscope
ICU	Intensive Care Unit
IQR	Interquartile Range
NSC	National Safety Council

## REFERENCES

- Agarwal, R. K., Banerjee, G., Shembish, N., Jamal, B. A., Kareemullah, C., & Swaleh, A. (1988). Foreign bodies in the tracheobronchial tree: a review of 102 cases in Benghazi, Libya. *Annals of Tropical Paediatrics*, 8(4), 213–216.
- Alhomsy. (2020). Foreign body aspiration: study of epidemiological factors, site and type of foreign bodies in children. *European Journal of Biomedical*, 7(4), 471-476.
- Alwassia, A. A., Jose, A., Raddaoui, L., Hawkins, K., & Ahari, J. (2018). Endotracheal Tube Obstruction Due to Aspirated Foreign Bodies: An Overview of Etiology, Diagnosis, and Management. *Clinical Pulmonary Medicine*, 25(1), 20-22.
- Aydoğan, L. B., Tuncer, U., Soyulu, L., Kiroğlu, M., & Ozsahinoglu, C. (2006). Rigid bronchoscopy for the suspicion of foreign body in the airway. *International journal of pediatric otorhinolaryngology*, 70(5), 823-828.
- Bajaj, D., Sachdeva, A., & Deepak, D. (2021). Foreign body aspiration. *Journal of Thoracic Disease*, 13(8), 5159.
- Boyd, M., Watkins, F., Singh, S., Haponik, E., Chatterjee, A., Conforti, J., & Chin Jr, R. (2009). Prevalence of flexible bronchoscopic removal of foreign bodies in the advanced elderly. *Age and ageing*, 38(4), 396-400.
- Brkic, F., Umihanic, S., Altumbabic, H., Ramas, A., Salkic, A., Umihanic, S., Mujic, M., Softic, L. & Zulcic, S. (2018). Death as a consequence of foreign body aspiration in children. *Medical Archives*, 72(3), 220.
- Budhiraja, G., Singh, H., Guram, D., Pulkit, & Kaur, N. (2021). Foreign Body Aspiration in Pediatric Airway: A Clinical Study. *Indian Journal of Otolaryngology and Head & Neck Surgery*, 1-7.
- Chand, R., Shaikh, M., Khan, Y., Qureshi, M. A., Maheshwari, H., Yasir, M., & Hemandas, H. (2020). Frequency of various foreign bodies retrieved from the airway during bronchoscopy in children: a pediatric tertiary care center experience. *Cureus*, 12(7). Chaudhry R, Bordoni B. (2017). Anatomy, Thorax, Lungs. In: StatPearls.
- StatPearls Publishing, Treasure Island (FL); 2022. PMID: 29262068.
- Costa, C., Feijó, S., Monteiro, P., Martins, L., & Gonçalves, J. R. (2018). Role of bronchoscopy in foreign body aspiration management in adults: A seven year retrospective study. *Pulmonology*, 24(1), 50-52.
- Cui, Y., Shao, J., Sun, H., Wang, X., & Zhu, Z. (2020). Risk factor analysis of bronchospasm after tracheobronchial foreign body removal: Cases report and literature review (STROBE). *Medicine*, 99(52).
- Daroszewski, M., Szpinda, M., Wiśniewski, M., Flisiński, P., Szpinda, A., Woźniak, A., Woźniak, A., Kosiński, A., Grzybiak, M. & Mila-Kierzenkowska, C. (2013). Tracheo-bronchial angles in the human fetus—an anatomical, digital, and statistical study. *Medical science monitor basic research*, 19, 194.



- Dutau, Hervé; Vandemoortele, Thomas; Breen, David P. (2013). *Rigid Bronchoscopy. Clinics in Chest Medicine*, 34(3), 427-435. doi: 10.1016/j.ccm.2013.04.003
- Eren, Ş., Balci, A. E., Dikici, B., Doblan, M., & Eren, M. N. (2003). Foreign body aspiration in children: experience of 1160 cases. *Annals of tropical paediatrics*, 23(1), 31-37.
- Fasseeh, N. A., Elagamy, O. A., Gaafar, A. H., Reyad, H. M., Abougabal, M. S., Heiba, D. A., & Kantar, A. (2021). A new scoring system and clinical algorithm for the management of suspected foreign body aspiration in children: a retrospective cohort study. *Italian Journal of Pediatrics*, 47(1), 1-9.
- Fraga, A. D. M. A., Reis, M. C. D., Zambon, M. P., Toro, I. C., Ribeiro, J. D., & Baracat, E. C. E. (2008). Foreign body aspiration in children: clinical aspects, radiological aspects and bronchoscopic treatment. *Jornal Brasileiro de Pneumologia*, 34, 74-82.
- García, E. S., de Vega Sánchez, B., & Vicente, C. D. (2021). Crustacean remnants as a bronchial foreign body. *Pulmonology*, 27(6), 590-591.
- Gerber, A. C., Stocker, S., & Weiss, M. (2006). Tracheobronchial foreign body aspiration in children—diagnostic value of symptoms and signs. *Swiss medical weekly*, 136(3334), 533-538.
- Goh, P. L., Lim, E. H., Teo, D. S. H. M., & Sairin, M. E. (2022). Challenges in diagnosing foreign body aspiration in children. *Cureus*, 14(1).
- Goussard, P., Gie, R., Andronikou, S., & Morrison, J. L. (2014). Organic foreign body causing lung collapse and bronchopleural fistula with empyema. *Case Reports*, 2014, bcr2014204633.
- Haller, L., Barazzone-Argiroffo, C., Vidal, I., Corbelli, R., Anooshiravani- Dumont, M., & Mornand, A. (2018). Safely decreasing rigid bronchoscopies for foreign-body aspiration in children: an algorithm for the emergency department. *European Journal of Pediatric Surgery*, 28(03), 273-278.
- Hitter A, Karkas A, Schmerber S, Righini CA. Rigid bronchoscopy. *Progr Respir Res* 2010;38:83-94
- Holst-Albrechtsen, S., Kristensen, S., & Larsen, K. (2017). Bronchoscopy in children suspected of lower airway aspiration. *Dan Med J*, 64(11), A5419.
- Jan, G., & Kamil, M. (2021). Frequency and Types of Foreign Body Airway in Children. *Age (years)*, 4(76), 84-4.
- Karaaslan, E., & Yildiz, T. (2019). Management of anesthesia and complications in children with Tracheobronchial Foreign Body Aspiration. *Pakistan Journal of Medical Sciences*, 35(6), 1592.
- Kashif, M., Talib Hashmi, H. R., & Khaja, M. (2016). Early recognition of foreign body aspiration as the cause of cardiac arrest. *Case Reports in Critical Care*, 2016. nKorlacki, W., Korecka, K., & Dzielicki, J. (2011). Foreign body aspiration in children: diagnostic and therapeutic role of bronchoscopy. *Pediatric surgery international*, 27, 833-837.
- Leung, J., Ainsworth, J., Peters, R., Mehr, S., Smart, J., & Rose, E. (2021). Increased rates of peanut and tree nut aspiration as a possible consequence of allergy prevention by early introduction. *The Journal of Allergy and Clinical Immunology: In Practice*, 9(8), 3140-3146.
- Mallick, M. S. (2014). Tracheobronchial foreign body aspiration in children: a continuing diagnostic challenge. *African journal of paediatric surgery*, 11(3), 225- 228.
- McCullagh, K. L., Shah, R.N., Huang, B.Y. (2022). Anatomy of the Larynx and Cervical Trachea. *Neuroimaging Clin N Am*. 32(4):809-829. doi: 10.1016/j.nic.2022.07.011. PMID: 36244725.
- Mohammad, M., Saleem, M., Mahseeri, M., Alabdallat, I., Alomari, A., Qudaisat, I., Alomari, A., Qudaisat, I., Shudifat, A. & Alzoubi, M. N. (2017). Foreign body aspiration in children: a study of children who lived or died following aspiration. *International journal of pediatric otorhinolaryngology*, 98, 29-31.
- Mohsen, F., Bakkar, B., Melhem, S., Altom, R., Sawaf, B., Alkhija, I., & Nahas, L. D. (2021). Foreign body aspiration in a tertiary Syrian centre: A 7-year retrospective study. *Heliyon*, 7(3).
- Paradis, T. J., Dixon, J., & Tieu, B. H. (2016). The role of bronchoscopy in the diagnosis of airway disease. *Journal of thoracic disease*, 8(12), 3826.
- Pietraś, A., Markiewicz, M., & Mielnik-Niedzielska, G. (2021). Rigid Bronchoscopy in Foreign Body Aspiration Diagnosis and Treatment in Children. *Children*, 8(12), 1206.
- Puja, D., Arun, R. K., Ashok, B., & Rathi, S. (2017). Foreign body aspiration in paediatric airway. *International Journal of Medical Research & Health Sciences*, 6(3), 17-21.
- Rafanan, A. L., & Mehta, A. C. (2001). Adult airway foreign body removal: what's new?. *Clinics in chest medicine*, 22(2), 319-330.
- Ramasubramanian, P. (2008). *Clinical profile, outcome and follow-up of foreign body aspiration in children* (Doctoral dissertation, Madras Medical College, Chennai).
- Ramos, M. B., Botana-Rial, M., García-Fontán, E., Fernández-Villar, A., & Torreira, M. G. (2016). Update in the extraction of airway foreign bodies in adults. *Journal of thoracic disease*, 8(11), 3452.
- Ramos, M. B., Fernández-Villar, A., Rivo, J. E., Leiro, V., García-Fontán, E., Botana, M. I., Torres, M.L. & Canizares, M. A. (2009). Extraction of airway foreign bodies in adults: experience from 1987–2008. *Interactive cardiovascular and thoracic surgery*, 9(3), 402-405.
- Rashi, R., Kumar, A., Sinha, A. K., & Kumar, B. (2020). Foreign body inhalation in children: A mixed bag of experiences over two years in a tertiary care center of Eastern India. *Indian Journal of Child*

*Health*, 15-18.

- Reyad, H. M., El-Deeb, M. E., Abbas, A. M., Sherief, D., & Elagamy, O. A. (2021). Foreign body aspiration in Egyptian children clinical, radiological and bronchoscopic findings. *Journal of Multidisciplinary Healthcare*, 2299-2305.
- Safari, M., & Manesh, M. R. H. (2016). Demographic and clinical findings in children undergoing bronchoscopy for foreign body aspiration. *Ochsner Journal*, 16(2), 120-124.
- Saladin, K. S., & Porth, C. (2010). *Anatomy & physiology: the unity of form and function* (Vol. 5). New York: McGraw-Hill. Retrieved from [https://faculty.ksu.edu.sa/sites/default/files/chapter\\_22\\_respiratorysystem.pdf](https://faculty.ksu.edu.sa/sites/default/files/chapter_22_respiratorysystem.pdf)
- Salih, A. M., Alfaki, M., & Alam-Elhuda, D. M. (2016). Airway foreign bodies: A critical review for a common pediatric emergency. *World journal of emergency medicine*, 7(1), 5.
- Sav, N. M., Kiliçaslan, Ö., Karaca, S. E., Tamtürk, C., & Kabaklioğlu, M. (2021). Foreign Body Aspiration In Children; Duzce University Five-Years Results. *Konuralp Medical Journal*, 13(3), 601-605.
- Sehgal, I. S., Dhooria, S., Ram, B., Singh, N., Aggarwal, A. N., Gupta, D., Behera, D. & Agarwal, R. (2015). Foreign body inhalation in the adult population: experience of 25,998 bronchoscopies and systematic review of the literature. *Respiratory Care*, 60(10), 1438-1448.
- Sen, M. K., & Suri, J. C. (2000). Therapeutic bronchoscopy. *INDIAN JOURNAL OF CHEST DISEASES AND ALLIED SCIENCES*, 42(3), 167-180.
- Sinha, V., Talagauara Umesh, S., & Jha, S. G. (2017). Rigid bronchoscopy in pediatric patients. *Indian Journal of Otolaryngology and Head & Neck Surgery*, 69, 449-452.
- Sinnatamby, C. S., (2011). Last's Anatomy e-Book: Last's Anatomy e-Book. Elsevier Health Sciences.
- Sultan, T. A., & van As, A. B. (2016). Review of tracheobronchial foreign body aspiration in the South African paediatric age group. *Journal of thoracic disease*, 8(12), 3787.
- Tahir, N., Ramsden, W. H., & Stringer, M. D. (2009). Tracheobronchial anatomy and the distribution of inhaled foreign bodies in children. *European journal of pediatrics*, 168, 289-295.
- Tseng, H. J., Hanna, T. N., Shuaib, W., Aized, M., Khosa, F., & Linnau, K. F. (2015). Imaging foreign bodies: ingested, aspirated, and inserted. *Annals of emergency medicine*, 66(6), 570-582
- Verma, R. K., Ibrahim, M., & Garcia-Contreras, L. (2015). Lung anatomy and physiology and their implications for pulmonary drug delivery. *Pulmonary drug delivery: advances and challenges*, 1-18.
- Wetmore, R. F., Muntz, H. R., & McGill, T. J. (2000). Pediatric otolaryngology: principles and practical pathways. (*No Title*).
- Zhao, Z., Gao, Q., & Song, P. (2015). A rare case of bilateral bronchial foreign body. *Pakistan Journal of Medical Sciences*, 31(2), 477.