

## Early Vertebral Metastases in Non-Muscle-Invasive Bladder Cancer: A Case Report

Anouar El Ghazzaly<sup>1\*</sup>, Ilias Hassan<sup>1</sup>, Mohamed Amine Harchaoui<sup>1</sup>, Abdessamad El Bahri<sup>1</sup>, Mohammed Alami<sup>1</sup>, Ahmed Ameer<sup>1</sup>

<sup>1</sup>Department of Urology, Mohammed V Military Hospital, Rabat, Morocco

DOI: [10.36347/sjmcr.2024.v12i05.104](https://doi.org/10.36347/sjmcr.2024.v12i05.104)

| Received: 11.04.2024 | Accepted: 25.05.2024 | Published: 31.05.2024

\*Corresponding author: Anouar El Ghazzaly

Department of Urology, Mohammed V Military Hospital, Rabat, Morocco

### Abstract

### Case Report

Most urinary tract tumors are bladder cancers, whereas NMIBCs are the most common. In NMIBC, distant metastases are extremely rare, and imaging for staging is rarely requested without warning signs, nor recommended. Nonetheless, non-muscle invasive bladder cancers can develop distant metastases without regional progression. We present a case of NMIBC with vertebral metastasis in a young man with no risk factors for bladder tumors who responded well to systemic therapy. We also discuss possible explanations for this rare occurrence.

**Keywords:** Urothelial carcinoma; Non-muscle invasive bladder cancer; Vertebral metastases; Early metastasis.

**Copyright © 2024 The Author(s):** This is an open-access article distributed under the terms of the Creative Commons Attribution 4.0 International License (CC BY-NC 4.0) which permits unrestricted use, distribution, and reproduction in any medium for non-commercial use provided the original author and source are credited.

## INTRODUCTION

Bladder cancer is the most common urinary tract tumors. Nevertheless, it is relatively rare among young people. Around 70% of bladder tumors are superficial, and the occurrence of early distant metastases is rare. We report a case of a young man who developed vertebral metastases from a non-muscle-infiltrating bladder tumor. We discuss hypotheses that may explain distant metastases in this type of cancer.

## CASE PRESENTATION

A 31-year-old man, with no notable medical history or smoking history, presented to our center with a 15-day history of lumbosciatica deficiency. There was no fever, tuberculosis infection, or recent trauma in the patient.

In contrast, 6 months ago, the patient presented with macroscopic hematuria, for which a reno-vesical ultrasound revealed thickening of the bladder wall. A trans-urethral resection of the bladder was performed with complete and deep lesion resection. Histological examination revealed a papillary urothelial carcinoma infiltrating the chorion. There was no muscle infiltration (PT1). There was no evidence of vascular or perineural invasion. Unfortunately, the patient did not receive any further treatment after he was lost to follow-up.

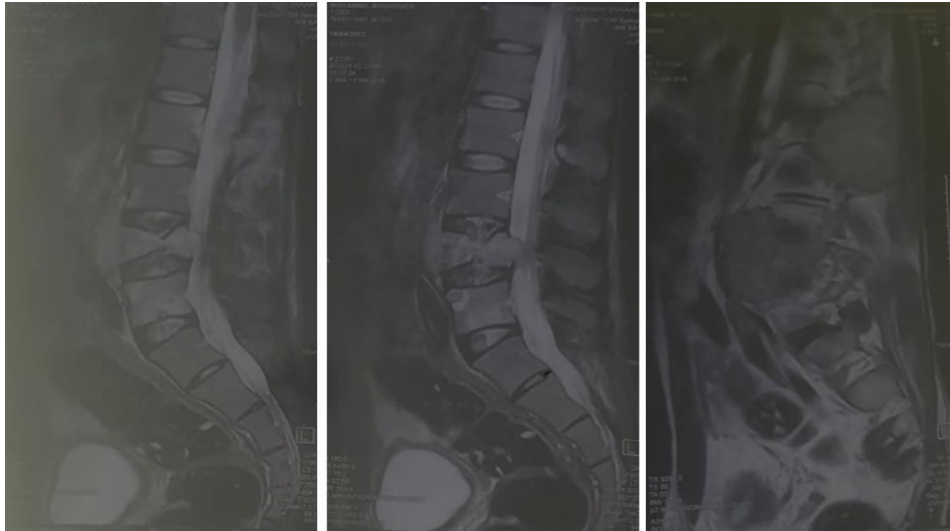
Upon admission, the patient presented with lumbar spinal syndrome and radicular syndrome type L4 and L5, without genital-sphincter disorders.

Lumbar MRI revealed a tumoral process of L4 vertebral body, infiltrating the right iliopsoas muscle. It was associated with an infiltrating mass in the posterior arch of L2 and the homolateral paravertebral and psoas muscles. There were also lytic lesions in L5 (**Figure 1**).

In light of the antecedent bladder cancer, a Uroscanner was performed, and no recurrence of the tumor was found.

In view of the rarity of vertebral metastases of non-muscle-invasive bladder cancer (NMIBC), a biopsy of the mass in the 4th lumbar vertebra was performed. Histological analysis showed poorly differentiated carcinomatous proliferation, with immunohistochemical staining positive for Ac Anti-CK7, GATA 3, and Ac Anti-P63, consistent with a urothelial origin.

As a result of the diagnosis of metastatic urothelial carcinoma, the patient was referred to medical oncology for further treatment. The patient received cisplatin-based systemic chemotherapy with good results.



**Figure 1: Sagittal lumbar MRI: Tumoral process of L4 vertebral body, the posterior arch of L2 and infiltrating the iliopsoas muscle**

## DISCUSSION

Bladder cancer is the 10th most common malignancy diagnosed and the 13th most deadly globally (Sung *et al.*, 2021). Around 75% of patients are diagnosed with non-muscle-infiltrating cancer, while 25% are muscle-infiltrating or metastatic (Kamat *et al.*, 2016). NMIBC has a high recurrence rate (50-70%), and a significant proportion (15-20%) progresses to muscle-infiltrating cancer (Witjes *et al.*, 2021).

Bladder cancer is relatively rare in the young population, and several studies have shown that younger bladder cancer patients have more favorable clinical, pathological, and prognostic features (Al-Zalabani *et al.*, 2016). There are several risk factors associated with bladder cancer, including smoking, male gender, age, exposure to carcinogens, chronic bladder inflammation, drugs (phenacetine and cyclophosphamide), and pelvic radiotherapy. Several genetic polymorphisms have been proposed as being associated with the development of bladder cancer (Woldu *et al.*, 2017).

The patient's history does not reveal any occupational or environmental exposure, and his young age makes it difficult to implicate external factors.

Transurethral resection of the bladder is the first critical step in bladder tumor staging and management. Inadequate resection of the tumor, inadequate sampling of the muscularis propria, or missing a tumor such as CIS, can lead to poor staging and early recurrence (Matthews *et al.*, 1984).

Although most NMIBC remain non-infiltrative, the risk of progression is significant. However, NMIBC rarely metastasizes directly to distant sites without progression to the bladder or regional lymph nodes (Hsieh *et al.*, 2015).

Metastasis rates for bladder cancer are 10%. The most common site of metastasis was lymph nodes (69%), followed by bone (47%), lung (37%), liver (26%), and peritoneum (16%) (Shinagare *et al.*, 2011). Of the bone metastases, 40% occurred in the spine (Sengeløv *et al.*, 1996).

Several mechanisms may explain distant metastases in NMIBC:

- Lymphovascular invasion of tumor cells into the microcirculatory system (Sundar & Ganesan, 2007), circulating tumor cells excreted into the bloodstream from the primary tumor act as a proxy for early metastatic spread of the disease (Mathieu *et al.*, 2016).
- TURBT or intravesical therapy may cause tumor cells to spread (Sylvester *et al.*, 2006).
- Batson's venous plexus facilitates the attachment of tumor cells to bone tissue. As in the spine, this plexus has no valve structure (del Regato, 1977) (Sasaki *et al.*, 2013).
- On the other hand, stage may be underestimated.

For NMIBC, metastases are detected between 7 and 40 months after treatment of the primary tumor (D'Souza *et al.*, 2011), while metastasis-free survival for MIBC is between 1 and 2 years (Rodríguez López *et al.*, 2018). There is a shorter metastasis-free survival interval in patients with bone metastases than elsewhere (Xu *et al.*, 2022).

Metastatic NMIBC is treated according to metastatic bladder tumor guidelines. Platinum-containing chemotherapy is proposed as first-line therapy.

This case highlights the possibility that distant metastases may occur even in patients without local recurrence or progression. It isn't recommended that

clinicians perform routine CT or extension tests for patients with NMIBC, but clinicians should be aware that NMIBC can cause metastases.

## CONCLUSION

NMIBC rarely metastasizes to the spine. However, it should be considered as a possible diagnosis when a patient presents with neurological signs and has a history of bladder cancer.

## REFERENCES

- Sung, H., Ferlay, J., Siegel, R. L., Laversanne, M., Soerjomataram, I., Jemal, A., & Bray, F. (2021). Global cancer statistics 2020: GLOBOCAN estimates of incidence and mortality worldwide for 36 cancers in 185 countries. *CA: a cancer journal for clinicians*, 71(3), 209-249. doi: 10.3322/caac.21660
- Kamat, A. M., Hahn, N. M., Efstathiou, J. A., Lerner, S. P., Malmström, P. U., Choi, W., ... & Kassouf, W. (2016). Bladder cancer. *The Lancet*, 388(10061), 2796-2810. doi: 10.1016/S0140-6736(16)30512-8
- Witjes, J. A., Bruins, H. M., Cathomas, R., Compérat, E. M., Cowan, N. C., Gakis, G., ... & van Der Heijden, A. G. (2021). European Association of Urology guidelines on muscle-invasive and metastatic bladder cancer: summary of the 2020 guidelines. *European urology*, 79(1), 82-104. doi: 10.1016/j.eururo.2020.03.055
- Al-Zalabani, A. H., Stewart, K. F., Wesselius, A., Schols, A. M., & Zeegers, M. P. (2016). Modifiable risk factors for the prevention of bladder cancer: a systematic review of meta-analyses. *European journal of epidemiology*, 31, 811-851. doi:10.1007/s10654-016-0138-6
- Woldu, S. L., Bagrodia, A., & Lotan, Y. (2017). Guideline of guidelines: non-muscle-invasive bladder cancer. *BJU international*, 119(3), 371-380. doi:10.1111/bju.13760
- Matthews, P. N., Madden, M., Bidgood, K. A., & Fisher, C. (1984). The clinicopathological features of metastatic superficial papillary bladder cancer. *The Journal of urology*, 132(5), 904-906. doi:10.1016/s0022-5347(17)49939-3
- Hsieh, M. C., Chiang, P. H., Rau, K. M., Chen, Y. Y., Su, Y. L., & Huang, C. H. (2015, November). The comparison of oncologic outcomes between metastatic upper tract urothelial carcinoma and urothelial carcinoma of the bladder after cisplatin-based chemotherapy. In *Urologic Oncology: Seminars and Original Investigations* (Vol. 33, No. 11, pp. 495-e9). Elsevier. doi: 10.1016/j.urolonc.2015.07.001
- Shinagare, A. B., Ramaiya, N. H., Jagannathan, J. P., Fennessy, F. M., Taplin, M. E., & Van den Abbeele, A. D. (2011). Metastatic pattern of bladder cancer: correlation with the characteristics of the primary tumor. *American Journal of Roentgenology*, 196(1), 117-122. doi: 10.2214/AJR.10.5036
- Sengelov, L., Kamby, C., & von der Maase, H. (1996). Pattern of metastases in relation to characteristics of primary tumor and treatment in patients with disseminated urothelial carcinoma. *The Journal of urology*, 155(1), 111-114.
- Sundar, S. S., & Ganesan, T. S. (2007). Role of lymphangiogenesis in cancer. *Journal of Clinical Oncology*, 25(27), 4298-4307. doi: 10.1200/JCO.2006.07.1092
- Mathieu, R., Lucca, I., Rouprêt, M., Briganti, A., & Shariat, S. F. (2016). The prognostic role of lymphovascular invasion in urothelial carcinoma of the bladder. *Nature Reviews Urology*, 13(8), 471-479. doi:10.1038/nrurol.2016.126
- Sylvester, R. J., Van Der Meijden, A. P., Oosterlinck, W., Witjes, J. A., Bouffieux, C., Denis, L., ... & Kurth, K. (2006). Predicting recurrence and progression in individual patients with stage Ta T1 bladder cancer using EORTC risk tables: a combined analysis of 2596 patients from seven EORTC trials. *European urology*, 49(3), 466-477. doi: 10.1016/j.eururo.2005.12.031
- Del Regato, J. A. (1977, March). Pathways of metastatic spread of malignant tumors. In *Seminars in Oncology* (Vol. 4, No. 1, pp. 33-38).
- Sasaki, Y., Oi, H., Oyama, T., Kagawa, J., Komori, M., Senzaki, T., ... & Kanayama, H. O. (2013). Non-muscle invasive bladder cancer with multiple bone metastasis without local invasion: a case report. *Hinyokika kyo. Acta Urologica Japonica*, 59(10), 669-672.
- D'souza, N., Khan, M. J., Robinson, S., & Motiwala, H. (2011). A rare and unusual case of isolated cerebellar metastasis from a non-muscle invasive transitional cell carcinoma of bladder. *JRSM short reports*, 2(6), 1-3. doi:10.1258/shorts.2011.011014
- López, S. R., Arroyo, F. D., Pérez, M. Á. P. U., Sánchez, D. L., Corellano, J. V., Puerto, A. P., ... & Fernández, L. C. (2018). Metastasis of Ta low-grade bladder cancer into the lung and paraneoplastic syndrome without local invasion: A case report and literature review. *Urology Case Reports*, 17, 17-18. doi: 10.1016/j.eucr.2017.11.018
- Xu, T., Gu, W., Wang, X., Xia, L., He, Y., Dong, F., ... & Yao, X. (2022). Distant metastasis without regional progression in non-muscle invasive bladder cancer: case report and pooled analysis of literature. *World Journal of Surgical Oncology*, 20(1), 226. doi: 10.1186/s12957-022-02664-5