

Relationship between P16INK4a Overexpression in Human Papillomavirus Infection in High Grade CIN and Cervical Carcinoma

Dr. Rawshan Ara Sultana^{1*}, Dr. Labiba Yasmin Rahman², Dr. Marufa Khatun³, Dr. Md. Faysal Kamal⁴, Dr. Abu Taher Mohammad Nurul Amin⁵, Dr Tamanna Rahman⁶

¹Consultant, Department of Obstetrics & Gynaecology, Dhaka Medical College Hospital, Dhaka, Bangladesh

²Assistant Professor & HOD (cc), Department of Pathology, Institute of Applied Health Science (University of Science & Technology Chattogram (USTC)), Bangabandhu Memorial Hospital (BBMH), Chattogram, Bangladesh

³Assistant Professor, Department of Obstetrics & Gynaecology, Universal Medical College Hospital, Dhaka, Bangladesh

⁴Medical Officer, Department of General Surgery, Bangabandhu Sheikh Mujib Medical University, Dhaka, Bangladesh

⁵Lieutenant Colonel, Urology Department, CMH, Dhaka, Bangladesh

⁶Junior Consultant, Gynaecology & Obstetrics, Dhaka Medical College Hospital, Dhaka, Bangladesh

DOI: [10.36347/sjams.2024.v12i06.002](https://doi.org/10.36347/sjams.2024.v12i06.002)

| Received: 25.04.2024 | Accepted: 30.05.2024 | Published: 01.06.2024

*Corresponding author: Dr. Rawshan Ara Sultana

Consultant, Department of Obstetrics & Gynaecology, Dhaka Medical College Hospital, Dhaka, Bangladesh

Abstract

Original Research Article

Background: High-risk HPV strains are a well-known contributor to the carcinogenesis of cervical squamous cell carcinoma (SCC). Indeed, there has been a high detection of HPV DNA in SCC and precancerous lesions. **Objective:** The aim of the study was to assess the Relationship Between Human Papillomavirus Infection and P16INK4a Overexpression in Cervical Squamous Cell Carcinoma. **Methodology:** This descriptive cross-sectional study was carried out in the Pathology Department of DMC with collaboration of Bangabandhu Sheikh Mujib Medical University (BSMMU), Microbiology Department and Bangladesh Agricultural University (BAU), Mymensingh, during July 2017 to June 2018. A total 50 VIA positive and clinically suspected premalignant and malignant patient's attendant at DMC included as study population. Colposcopic biopsy specimens were sent to the Department of Pathology, DMCH, for histopathological examination. Some portion of biopsy samples were preserved at -4°C for HR-HPV DNA detection. Statistical analyses were done by using the SPSS 26.0. **Result:** Highest number of cases 20 (40%) were in fourth decade and their mean age was found to be 44.20±11.20, ranging from 28 to 67 years. Among 50 positive cases, maximum number of 32 (62%) cases were married between 16 to 20 years of age, 12 (22%) cases were married in less than 15 years of age and 6 (8%) cases were married at more than 20 years of age. The findings of colposcopic examinations of total 50 cases. Common diagnoses were CIN II in 24 (48%) cases, 8(16%) case represented CIN III, Squamous cell carcinoma in 16 (32%) cases and Adeno Carcinoma 2(4%) cases. In comparison of p16 score with cervical lesions in study subjects there were 26 true positive cases and 13 true negative cases. According to p16 score a total 37 (26 true positive+ 11 false positive) cases were p16 positive. Out of which 16(32.0%) and 21(42.0%) were HR-HPV positive and negative respectively. Similarly according to p16 score 13 nevasive cases were negative for HR-HPV DNA as well. The difference was statistically significant. We also examined the correlation between p16INK4a overexpression and patient age and found that the age distribution of p16INK4a overexpression patients did not significantly differ from that of p16INK4a non-overexpression patients. **Conclusion:** The study's findings demonstrated that HR-HPV-infected cervical lesions are linked to immunohistochemistry overexpression of p16. It can be deduced that p16 overexpression indicates the potential utility as a diagnostic.

Keywords: P16ink4a, squamous cell carcinoma (SCC), High-risk HPV.

Copyright © 2024 The Author(s): This is an open-access article distributed under the terms of the Creative Commons Attribution 4.0 International License (CC BY-NC 4.0) which permits unrestricted use, distribution, and reproduction in any medium for non-commercial use provided the original author and source are credited.

INTRODUCTION

High-risk HPV strains are a well-known contributor to the carcinogenesis of cervical squamous cell carcinoma (SCC). Indeed, there has been a high detection of HPV DNA in SCC and precancerous lesions [1]. Cervical epithelial cells are infected by high-risk HPVs, and oncoproteins E6 and E7 have the capacity to

bind and deactivate the host-cell regulatory protein p53 and, correspondingly, retinoblastoma protein (pRb). When high-risk HPVs inactivate these tumor suppressor genes, the host cells proliferate uncontrollably [2]. One of the cyclin-dependent kinase inhibitors, P16INK4a, inhibits the phosphorylation of pRb and, as a result, is crucial for controlling the mammalian cell cycle [3].

Citation: Rawshan Ara Sultana, Labiba Yasmin Rahman, Marufa Khatun, Md. Faysal Kamal, Abu Taher Mohammad Nurul Amin, Tamanna Rahman. Relationship between P16INK4a Overexpression in Human Papillomavirus Infection in High Grade CIN and Cervical Carcinoma. Sch J App Med Sci, 2024 Jun 12(6): 716-721.

Furthermore, certain research has shown that p16INK4a is highly activated and contributes significantly to either replicative senescence or early senescence brought on by oncogenic ras [4]. As a result, p16INK4a is regarded as a crucial tumor suppressor. On the other hand, overexpression of p16INK4a has been shown to be negatively correlated with functioning pRb [5]. Cervical intraepithelial neoplasia (CIN), a term used to describe precancerous lesions, precedes invasive cervical cancer, which is primarily squamous cell carcinomas. Of them, only a negligible portion develop into invasive cervical cancer and high grade lesions (HSIL) from low grade lesions (LSIL). Typically, advance to CIN II, and only 12% of CIN III cases proceed to aggressive malignancy [6]. Compared to women who are not infected, the chance of getting cervical squamous cell carcinoma increases by approximately 400 times after HPV-16 infection and by approximately 250 times after HPV-18 infection [7]. These days, a number of biotechnologies are available to detect precancerous lesions of the cervix in addition to cancer screening programs [8]. An inhibitor of Cyclin D Depended Kinases (CDK 4, 6) is p16INK4A (p16). This protein, a tumor suppressor, phosphorylates the retinoblastoma protein to slow down the cell cycle through the inactivation of CDK. P16 activities are significantly impacted when Rb is functionally inactivated by the HPV oncogene E7. P16 is expressed more highly as a result of it. Significant p16 protein rise in dysplastic cells is observed after HPV infections; this is not observed in normal cervical epithelium [9]. Immunohistochemical detection of this p16 overexpression aids in the identification of HPV-infected cells. As a result, p16 protein analysis may enhance traditional histopathological diagnosis of preneoplastic illnesses including HPV infection [10]. Early marriage, many pregnancies, and other circumstances are significant determinants in the development of cervical premalignant and malignant lesions caused by HPV in our culture. Therefore, to reduce the incidence of cervical cancer, new and efficient HPV detection methods should be used with established ones [11]. Thus the aim of the study was to assess the

Relationship Between Human Papillomavirus Infection and P16ink4a Overexpression in Cervical Squamous Cell Carcinoma.

METHODOLOGY

This descriptive cross-sectional study was carried out in the Pathology Department of DMC with collaboration of Bangabandhu Sreikh Mujib Medical University (BSMMU), Microbiology Department and Bangladesh Agricultural University (BAU), Mymensingh, during July 2017 to June 2018. A total 50 VIA positive and clinically suspected premalignant and malignant patient's attendant at DMC included as study population. Ethical clearance was taken from institutional ethical committee of DMC, Dhaka. 50 VIA positive patients with complaints of lower abdominal pain, irregular per vaginal bleeding, dyspareunia and post coital bleeding were selected from GOPD. These patients were advised for colposcopic examination by the gynecologist. After taking detail history with attention to age, age of first pregnancy, parity, history of contraception, sign & symptoms, 50 patients were selected. Colposcopic examinations were done by gynecologist. Colposcopic biopsy specimens were sent to the Department of Pathology, DMCH, for histopathological examination. Some portion of biopsy samples were preserved at -4°C for HR-HPV DNA detection. HR-HPV (16, 18) DNA were detected by PCR. p16 IHC were performed from the paraffin blocks. The sections were stained with p16 antibody was done manually following the avidin-biotin-peroxidase staining method. All the sections that showed either strong nuclear or cytoplasmic stains were considered positive. To determine the score of p16 expression, a four-semi quantitative class was used. PCR utilizing the consensus primer, directed at relatively conserved regions of specific HPV genomes, allowed amplification of specific HR-HPV genotypes in a single reaction. The present study aimed to detect HR-HPV namely HPV 16 and 18. Statistical analyses were done by using the SPSS 26.0.

Evaluation of p16INK4a immunostaining

	Positive cells (%)			
Intensity	0	<5	<50	>50
-	Negative	Negative	Negative	Negative
+	Negative	Weakly Positive	Weakly Positive	Weakly Positive
++	Negative	Weakly Positive	Moderately Positive	Moderately Positive
+++	Negative	Weakly Positive	Moderately Positive	Strongly Positive

RESULT

Table I: Distribution of patients according to age (n=50)

Age	n	%
≤30	7	14
31 - 40	20	40
41 - 50	7	14

Age	n	%
51 - 60	9	18
>60	7	14
Mean±SD (years)	44.20±11.20	
Range (years)	28.00-67.00	

Table I shows age distribution of the patients. Highest number of cases 20 (40%) were in fourth decade

and their mean age was found to be 44.20±11.20, ranging from 28 to 67 years.

Table II: Distribution of patients according to age during marriage (n=50)

Age at marriage (years)	n	%
≤15	12	22
16 – 20	32	62
>20	6	8
Mean±SD (years)	15.33±2.23	
Range (years)	12-22	

Table II shows distribution of patients according to the age during marriage. Among 50 cases, maximum number of 32 (62%) cases were married between 16 to 20 years of age, 12 (22%) cases were

married in less than 15 years of age and 6 (8%) cases were married at more than 20 years of age. The mean marital age was 15.33±2.23 ranging from 12 to 22 years.

Table III: Distribution of patients according to their sign and symptoms (n=50)

Sign - symptoms	n	%
Per vaginal discharge	41	82
Backache/ lower abdominal pain	38	76
Irregular p/v bleeding	27	54
Post coital bleeding	4	8

Table III shows sign symptoms of study population. Most common symptoms observed were per vaginal whitish discharge in 41 (82%), lower abdominal

pain in 38 (76%), irregular p/v bleeding in 27 (54%) and post coital bleeding found in 4 (8%) cases.

Table IV: Distribution of patients according to colposcopic examination with high-risk HPV infection (n=50)

Colposcopic examination	n	%
CIN II	24	48.0
CIN III	8	16.0
Carcinoma Cervix	18	36.0
Total	50	100.0

(CIN II–Cervical intraepithelial neoplasia II, CIN III–Cervical intraepithelial neoplasia III)

Table IV demonstrates the findings of colposcopic examinations of total 50 cases. Common diagnoses were CIN II in 24 (48%) cases, 8(16%) case

represented CIN III and Carcinoma cervix in 18 (36%) cases.

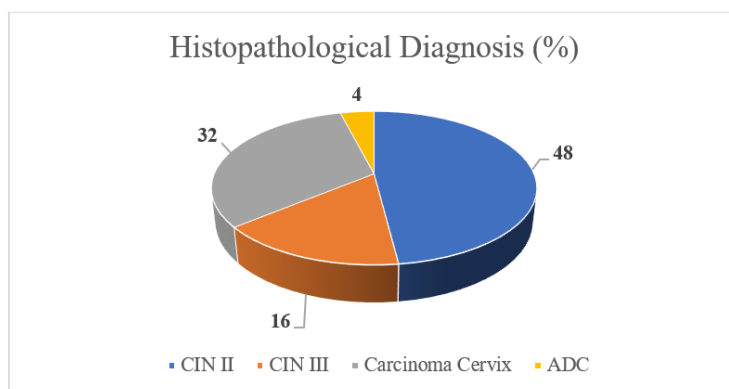


Figure 1: Bar diagram showing distribution of the patients by histopathological diagnoses (n=50)

(CIN II–Cervical intraepithelial neoplasia II, CIN III–Cervical intraepithelial neoplasia III, ISCC- Invasive squamous cell carcinoma, ADC- Adenocarcinoma)

This bar diagram reveals the histopathological diagnoses of 50 patients. It shows that the common diagnoses were invasive squamous cell carcinoma in 36%, Carcinoma Cervix in 36%, CIN II in 48% and CIN III in 16 and adenocarcinoma 3% case each.

Table VIII: Distribution of p16 score with high-risk HPV infection (n=50)

Dx	p16 score				US	Total	p16 positive
	Neg <5%	Weak + ve 5-25%	Mod+ve 26-50%	Intense+ve 50%			
CIN II	0	0	0	0	0	0	0(0.0)
CIN III	0	0	2	6	0	8	8(100.0%)
ISCC	0	0	0	18	0	18	18(100.0%)
ADC	0	0	0	2	0	1	1(100.0%)
Total	8	1	8	33	0	50	26

(CC-Carcinoma Cervix, CIN II–Cervical intraepithelial neoplasia II, CIN III–Cervical intraepithelial neoplasia III, ISCC- Invasive squamous cell carcinoma, ADC- Adenocarcinoma, US- Unsatisfactory).

Table VIII shows distribution of p16 score with cervical lesions in study subjects. Among 50 cases, p16 is intensely positive in total 26 cases. All 12 cases of cervical cancer including 11 (100%) cases of ISCC and 1 (100%) case of ADC were intensely positive. Apart from that, 24 (48%) cases of CIN II and 8(100%) case of CIN III expressed intense p16 positivity.

Table IX: Comparison of p16 score with cervical lesions in study subjects (n=50)

p16 score	H/P Diagnosis	
	Positive (n=22)	Negative (n=18)
Positive for dysplasia (P)	26 (true positive)	11 (false positive)
Negative for dysplasia (N)	0 (false negative)	13 (true negative)

Table IX shows comparison of p16 score with cervical lesions in study subjects. It reveals that, among

50 cases, there were 26 true positive cases and 13 true negative cases.

Table XII: Comparison of p16 score with HPV: (n=50)

HR-HPV (16, 18)	p16 score		p value
	Positive	Negative	
Positive	16 (32.0)	0 (0.0)	0.007s
Negative	21 (42.0)	13 (26.0)	

Kappa=0.250

According to p16 score a total 37 (26 true positive+ 11 false positive) cases were p16 positive. Out of which 16(32.0%) and 21(42.0%) were HR-HPV positive and negative respectively. Similarly according

to p16 score 13 nevatve cases were negative for HR-HPV DNA as well. The difference was statistically significant.

Table XIII: Patients age distribution in overexpression and non-overexpression of p16INK4a

p16INK4a expression	Age (years)				
	≤30	31 - 40	41 - 50	51 - 60	>60
Overexpression*	13	55	26	9	2
Non-Overexpression*	6	23	12	5	5

*Mann–Whitney test, not significant.

We also examined the correlation between p16INK4a overexpression and patient age and found that the age distribution of p16INK4a overexpression patients did not significantly differ from that of p16INK4a non-overexpression patients.

DISCUSSION

One of the cyclin-dependent kinase inhibitors that stops pRb from being phosphorylated is P16INK4a, which is regarded as a crucial tumor suppressor. The

functional status of pRb regulates the amount of p16INK4a overexpression, and HPV E7-induced pRb inactivation causes p16INK4a overexpression. High level of p16INK4a overexpression has been observed in cervical cancer [12].

In our study Highest number of cases 20 (40%) were in fourth decade and their mean age was found to be 44.20±11.20, ranging from 28 to 67 years. Authors also noted nearly identical data on the peak age occurrence [13].

Among 50 cases, maximum number of 32 (62%) cases were married between 16 to 20 years of age, 12 (22%) cases were married in less than 15 years of age and 6 (8%) cases were married at more than 20 years of age. The mean marital age was 15.33±2.23 ranging from 12 to 22 years Similarly, in Bangladesh Karim *et al.* [14]. Most common symptoms observed were per vaginal whitish discharge in 41 (82%), lower abdominal pain in 38 (76%), irregular p/v bleeding in 27 (54%) and post coital bleeding found in 4 (8%) cases. In a study, Begum *et al.* observed abnormal intermenstrual bleeding in 12.19%, post-coital bleeding in 24.3%, and excessive vaginal discharge in 56.0% which are comparable with the current study [15]. Here in colposcopic examinations of total 50 cases. Common diagnoses were SCC in 14 (28%) cases, CIN II in 24(48%) cases and 8(16%) case represented CIN III. In the histopathological diagnoses of 50 patients. It shows that the common diagnoses were invasive squamous cell carcinoma in 25%, Carcinoma Cervix in 28%, CIN II in 48% and CIN III and adenocarcinoma 3% case each. This finding is consistent with that of Karim *et al.* [14]. Among 50 cases, p16 is intensely positive in total 26 cases. All 12 cases of cervical cancer including 11 (100%) cases of ISCC and 1 (100%) case of ADC were intensely positive. Apart from that, 8 (50%) cases of CIN I, 4 (60%) cases of CIN II and 1(100%) case of CIN III expressed intense p16 positivity.

All the cases of Carcinoma Cervix were scored negative (no stain) and 1/12 case of expressed weak p16 positivity, 5/12 cases of CIN II were moderately p16 positive. This current study shows comparison of p16 score with cervical lesions in study subjects. It reveals that, among 50 cases, there were 26 true positive cases and 13 true negative cases. According to p16 score a total 37 (26 true positive+ 11 false positive) cases were p16 positive. Out of which 16(32.0%) and 21(42.0%) were HR-HPV positive and negative respectively. Similarly according to p16 score 13 nevasive cases were negative for HR-HPV DNA as well. The difference was statistically significant. We also examined the correlation between p16INK4a overexpression and patient age and found that the age distribution of p16INK4a overexpression patients did not significantly differ from that of p16INK4a non-overexpression

patients. Sano *et al.* examined the overexpression levels of p16INK4a between HPV6/11 and HPV16 and documented the variations in pRb's functional inactivation caused by various HPVs [16]. Overexpression of p16INK4a was observed in the neoplastic cells alone and never detected in normal Cells [17].

CONCLUSION

It was never possible to identify p16INK4a overexpression in normal cells, only in the cancerous cells. The study showed overexpression of p16 in 26 cases of premalignant and malignant lesions out of 50 cases. The study's findings demonstrated that HR-HPV-infected cervical lesions are linked to immunohistochemistry overexpression of p16. It can be deduced that p16 overexpression indicates the potential utility as a diagnostic.

REFERENCE

1. Nakagawa, H., Sugano, K., Fujii, T., Kubushiro, K., Tsukazaki, K., & Nozawa, S. (2002). Frequent detection of human papilloma viruses in cervical dysplasia by PCR single-strand DNA-conformational polymorphism analysis. *Anticancer research*, 22(3), 1655-1660.
2. Fujii, T., Tsukazaki, K., Kiguchi, K., Kubushiro, K., Yajima, M., & Nozawa, S. (1995). The major E6/E7 transcript of HPV-16 in exfoliated cells from cervical neoplasia patients. *Gynecologic oncology*, 58(2), 210-215.
3. Bringold, F., & Serrano, M. (2000). Tumor suppressors and oncogenes in cellular senescence☆. *Experimental gerontology*, 35(3), 317-329.
4. Ohtani, N., Zebedee, Z., Huot, T. J., Stinson, J. A., Sugimoto, M., Ohashi, Y., ... & Hara, E. (2001). Opposing effects of Ets and Id proteins on p16INK4a expression during cellular senescence. *Nature*, 409(6823), 1067-1070.
5. Sakaguchi, M., Fujii, Y., Hirabayashi, H., Yoon, H. E., Komoto, Y., Oue, T., ... & Matsuda, H. (1996). Inversely correlated expression of p16 and Rb protein in non-small cell lung cancers: an immunohistochemical study. *International journal of cancer*, 65(4), 442-445.
6. Grigore, M., Teleman, S., Ungureanu, D., & Mares, A. (2013). Molecular markers in cervical screening—a promise for the future. *Revista Romana de Medicina de Laborator*, 21(2), 231-239.
7. de Sanjose, S., Quint, W. G., Alemany, L., Geraets, D. T., Klaustermeier, J. E., Lloveras, B., ... & Bosch, F. X. (2010). Human papillomavirus genotype attribution in invasive cervical cancer: a retrospective cross-sectional worldwide study. *The lancet oncology*, 11(11), 1048-1056.
8. Stanculescu, R. (2016). Biotechnologies Involved in Differentiation of Cervical Lesions. In *Human*

Papillomavirus-Research in a Global Perspective. IntechOpen.

9. Benevolo, M., Mottoliese, M., Marandino, F., Vocaturo, G., Sindico, R., Piperno, G., ... & Vocaturo, A. (2006). Immunohistochemical expression of p16INK4a is predictive of HR-HPV infection in cervical low-grade lesions. *Modern Pathology*, 19(3), 384-391.
10. Benevolo, M., Mottoliese, M., Marandino, F., Vocaturo, G., Sindico, R., Piperno, G., ... & Vocaturo, A. (2006). Immunohistochemical expression of p16INK4a is predictive of HR-HPV infection in cervical low-grade lesions. *Modern Pathology*, 19(3), 384-391.
11. Giarrè, M., Caldeira, S., Malanchi, I., Ciccolini, F., Leão, M. J., & Tommasino, M. (2001). Induction of pRb degradation by the human papillomavirus type 16 E7 protein is essential to efficiently overcome p16INK4a-imposed G1 cell cycle Arrest. *Journal of virology*, 75(10), 4705-4712.
12. Yoshinouchi, M. I. T. S. U. O., Hongo, A. T. S. U. S. H., Takamoto, N., Ono, Y., Nagao, S., Miyagi, Y., ... & Kodama, J. (2000). Alteration of the CDKN2/p16 gene is not required for HPV-positive uterine cervical cancer cell lines. *International journal of oncology*, 16(3), 537-578.
13. Boldrini, N. T., Freitas, L. B., Coutinho, A. R., Loureiro, F. Z., Spano, L. C., & Miranda, A. E. (2014). High-grade cervical lesions among women attending a reference clinic in Brazil: associated factors and comparison among screening methods. *PloS one*, 9(7), e102169.
14. Karim, S.S., Tabassum, F., Razzaque, S., Dewan, R.K., Jinnah, M.A, Haque, N. (2017). Detection of modified agNOR in colposcopically abnormal lesions of cervix and its correlation with ki67 expression. *Journal of Histopathology and Cytopathology*. 2017;1(1): 13-19.
15. Begum, K. S., Sultana, K., & Begum, R. S. (2014). Result of Colposcopy among VIA positive cases attending in Colposcopy Clinic of BSMMU. *J. Med Sci Jan*, 22(1), 15-22.
16. Sano, T., Oyama, T., Kashiwabara, K., Fukuda, T., & Nakajima, T. (1998). Expression status of p16 protein is associated with human papillomavirus oncogenic potential in cervical and genital lesions. *The American journal of pathology*, 153(6), 1741-1748.
17. Ishikawa, M., Fujii, T., Saito, M., Nindl, I., Ono, A., Kubushiro, K., ... & Nozawa, S. (2006). Overexpression of p16INK4a as an indicator for human papillomavirus oncogenic activity in cervical squamous neoplasia. *International Journal of Gynecologic Cancer*, 16(1).