

Clinical Presentations and Complications among Cholesteatoma Cases

Dr. Md. Mahbulul Islam^{1*}, Dr. Samir Mohammad Tasrif², Dr. Md. Shahidullah³, Dr. S M Nafeez Imtiaz⁴, Dr. Md. Sha Sakender⁵, Dr. Md. Sahidur Rahman⁶, Dr. Mridul Deb Nath⁷

¹Indoor Medical Officer, Department of ENT & Head Neck Surgery, Shaheed Suhrawardy Medical College & Hospital, Dhaka, Bangladesh

²Assistant Registrar, Department of ENT & HNS, Shaheed Suhrawardy Medical College & Hospital, Dhaka, Bangladesh

³Registrar, Department of ENT & HNS, Shaheed Suhrawardy Medical College & Hospital, Dhaka, Bangladesh

⁴Assistant Registrar, Department of ENT & HNS, Shaheed Suhrawardy Medical College & Hospital, Dhaka, Bangladesh

⁵Registrar, Department of ENT & HNS, Shaheed Suhrawardy Medical College & Hospital, Dhaka, Bangladesh

⁶Assistant registrar, Department of ENT & HNS, Shaheed Suhrawardy Medical College & Hospital, Dhaka, Bangladesh

⁷Indoor Medical Officer, Department of ENT & HNS, Shaheed Suhrawardy Medical College & Hospital, Dhaka, Bangladesh

DOI: 10.36347/sjams.2024.v12i06.010

| Received: 27.04.2024 | Accepted: 04.06.2024 | Published: 21.06.2024

*Corresponding author: Dr. Md. Mahbulul Islam

Indoor Medical Officer, Department of ENT & Head Neck Surgery, Shaheed Suhrawardy Medical College & Hospital, Dhaka, Bangladesh.

Email: chisty2007rpmc@gmail.com

Abstract

Original Research Article

Background: Cholesteatoma is an abnormal collection of keratin-producing squamous epithelium in areas such as the middle ear, epitympanum, mastoid, or petrous apex. This three-dimensional epidermoid structure grows independently, replacing middle ear mucosa, and resorbing and replacing underlying bone. This study aimed to assess the clinical presentations and complications among cholesteatoma cases. **Methods:** This was a prospective observational study that was conducted in the Department of ENT & Head Neck Surgery, Shaheed Suhrawardy Medical College & Hospital, Dhaka, Bangladesh, from 01 January 2023 to 31 December 2023. The study enrolled a total of 43 cases with cholesteatoma using a random sampling technique. Data analysis was performed using MS Office tools. **Results:** The most prevalent symptoms observed were ear discharge in 93.0% of cases and hearing impairment in 74.4%. Notably, 81.4% of cases showed involvement of the pars flaccida. The most common complications were postauricular abscesses (14%) and postauricular sinuses (11.6%). Among the patients, 18 underwent CT scan evaluations, with findings including circumscribed cavities with ossicular erosion in 16 cases and space-occupying lesions in the brain in 2 cases. **Conclusion:** In cholesteatoma cases, ear discharge and hearing impairment are prevalent symptoms, while postauricular abscesses and sinuses are common complications. Pars flaccida involvement is frequent, and CT scans may be necessary for accurate diagnosis in many patients.

Keywords: Clinical presentations, Cholesteatoma, Discharge from ear, Hearing impairment, Postauricular abscess, CT scan.

Copyright © 2024 The Author(s): This is an open-access article distributed under the terms of the Creative Commons Attribution 4.0 International License (CC BY-NC 4.0) which permits unrestricted use, distribution, and reproduction in any medium for non-commercial use provided the original author and source are credited.

INTRODUCTION

Cholesteatoma represents the advanced stage of (squamous epithelial) retraction of the pars tensa or pars flaccida, which are not self-cleansing and thus retain epithelial debris, prompting a secondary inflammatory mucosal reaction [1]. This condition is a gradually progressive and destructive disease of the middle ear cleft, capable of eroding the surrounding soft and hard tissues, and is frequently observed in otological practice [2]. Histologically, attic-antral disease consists of three components: the cystic content, the matrix, and the perimatrix. The perimatrix, which interfaces with bone and granulation tissue, produces various proteolytic enzymes that may lead to bone destruction [3].

Cholesteatoma can be either congenital or acquired, with acquired cholesteatoma further classified as primary or secondary [4]. Among the three types of cholesteatomas, the most common form is primarily acquired chronic active squamous otitis media, characterized by the accumulation of retained keratin debris [5]. Another form is secondary acquired chronic active squamous otitis media, where keratin debris is retained within the middle ear, mastoid, or both. The third type involves acquired chronic active squamous otitis media in which the mucosa undergoes metaplasia to a squamous type [6]. The clinical presentation of cholesteatoma in uncomplicated cases typically includes discharge and deafness. The discharge is usually thick, purulent, foul-

Citation: Md. Mahbulul Islam, Samir Mohammad Tasrif, Md. Shahidullah, S M Nafeez Imtiaz, Md. Sha Sakender, Md. Sahidur Rahman, Mridul Deb Nath. Clinical Presentations and Complications among Cholesteatoma Cases. Sch J App Med Sci, 2024 Jun 12(6): 763-767.

smelling, scanty, and occasionally bloodstained [7]. This condition can often be asymptomatic and may be discovered incidentally. However, in the presence of complications, patients may develop symptoms such as earache, fever, chills and rigors, postauricular swelling, vomiting, vertigo, headache, postauricular discharging sinus, and facial weakness [8]. Many cases of cholesteatoma present with extracranial complications and occasionally severe intracranial complications, especially in children. This is largely due to factors such as illiteracy, poverty, lack of awareness, and limited medical facilities, particularly in rural areas. Since cholesteatoma is considered unsafe due to the risk of complications, especially intracranial ones, early diagnosis and treatment are crucial for patient safety [9]. The objective of this study was to assess the clinical presentations and complications among cholesteatoma cases.

METHODOLOGY

This was a prospective observational study that was conducted in the Department of ENT & Head Neck Surgery, Shaheed Suhrawardy Medical College & Hospital, Dhaka, Bangladesh, from 01 January 2023 to 31 December 2023. A total of 43 cases of cholesteatoma were enrolled as study subjects and selected using a random sampling technique. Written consent was obtained from all patients before data collection. According to the inclusion criteria, only cases of cholesteatoma were included, regardless of age and gender. Conversely, the exclusion criteria for this study ruled out cases with mucosal otitis media. All demographic and clinical information of the patients was recorded, and data were analyzed using MS Office tools.

RESULT

More than half (51%) of our patients were from the 11-20 years' age group, followed by 20.9% from the ≤ 10 years' age group, and 16.3% from the 21-30 years' age group. We observed that the highest number of patients (93.0%) had discharge from the ear as a symptom. In second highest number (74.4%) was found hearing impairment. Besides, in more than 10% of cases, earache (16.3%), fleshy mass in the ear (14%), post auricular painful swelling (4.7%), and fever (11.6%) were found. In the majority of our patients (81.4%), the involvement of the pars flaccida was observed. Additionally, the involvement of both pars flaccida and pars tensa was found in 11.6% of cases, while the involvement of the pars tensa alone was observed in 7% of cases. In the current study, postauricular abscesses were the most common complication, accounting for 14.0% of cases, followed by post auricular sinuses at 4.7%. Meningitis occurred in 7.0% of cases, while facial palsy was observed in 4.7%. Less frequently encountered complications included extradural abscesses, lateral sinus thrombophlebitis, and temporal lobe abscesses, each representing 2.3% of cases. Among the total patients, 18 underwent CT scan evaluations. In 16 cases, CT scans revealed a circumscribed cavity with ossicular erosion, while in 2 cases, space-occupying lesions were identified in the brain.

Table 1: Age distribution of patients (N=43)

Age (Year)	n	%
≤ 10 Yrs.	9	20.9%
11-20 Yrs.	22	51.2%
21-30 Yrs.	7	16.3%
31-40 Yrs.	4	9.3%
>40 Yrs.	1	2.3%

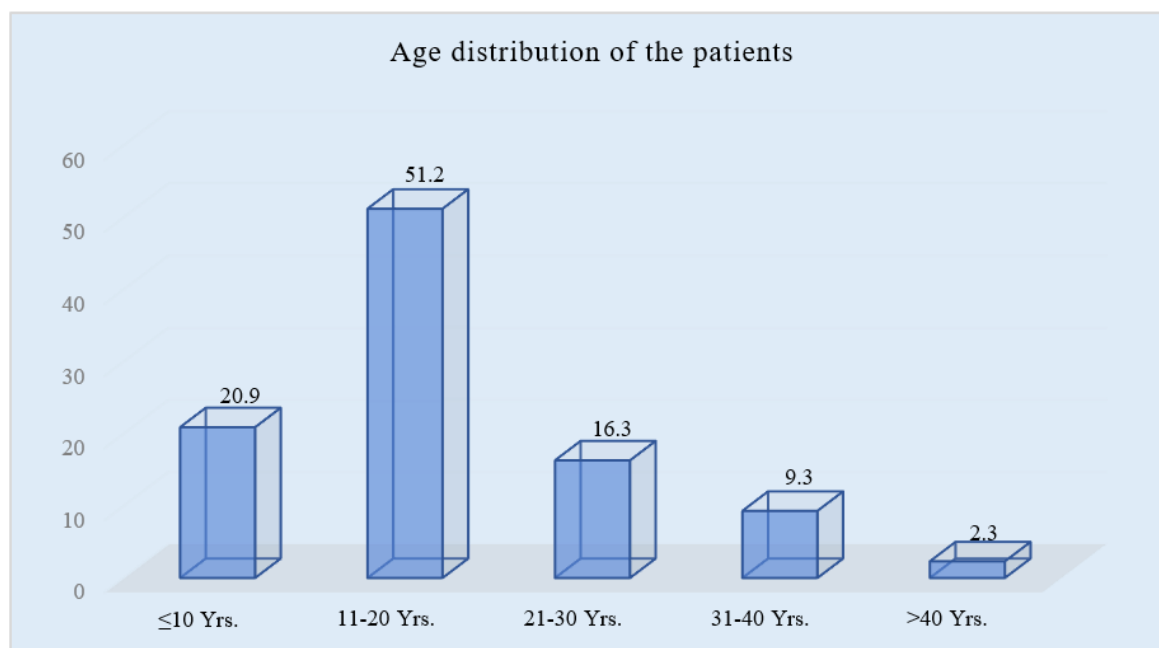


Figure I: Column chart showed age wise patients distribution (N=43)

Table 2: Distribution of symptoms

Symptoms	n	%
Discharge from ear	40	93.0%
Hearing impairment	32	74.4%
Earache	7	16.3%
Fleshy mass in the ear	6	14.0%
Post auricular painful swelling	2	4.7%
Fever	5	11.6%
Headache	4	9.3%
Post auricular discharging sinus	1	2.4%
Vomiting	3	7.0%
Vertigo	2	4.7%
Neck rigidity	2	4.7%

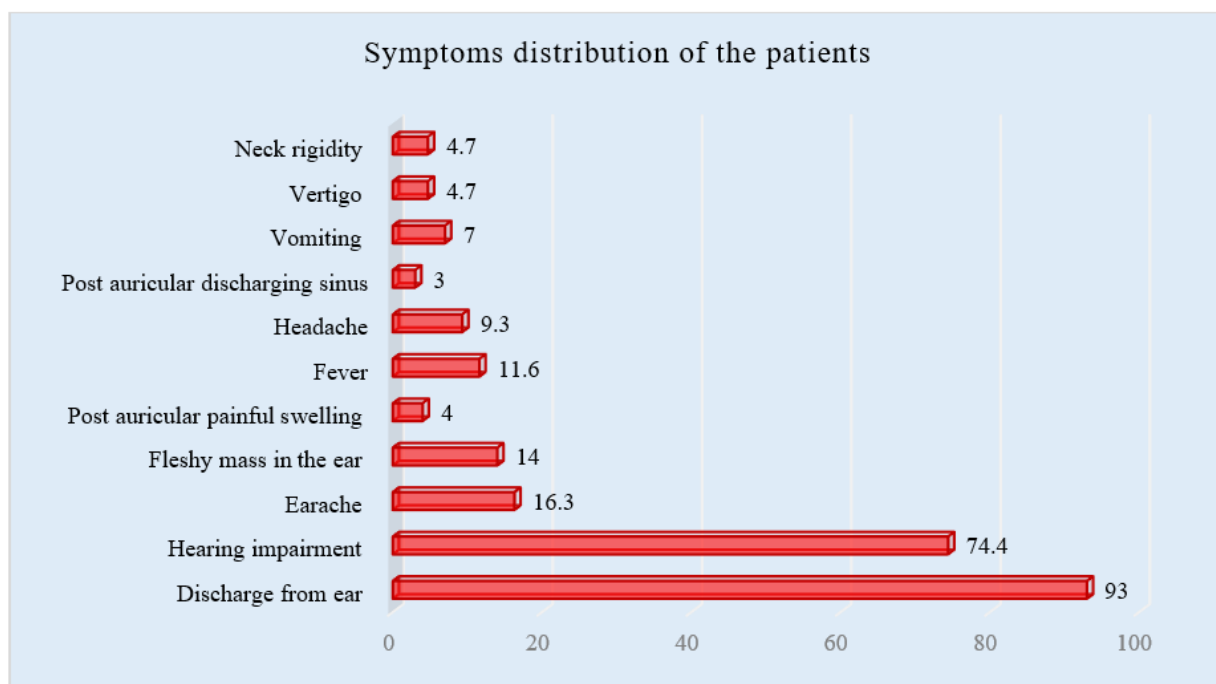


Figure II: Bar chart showed symptoms wise patients distribution (N=43)

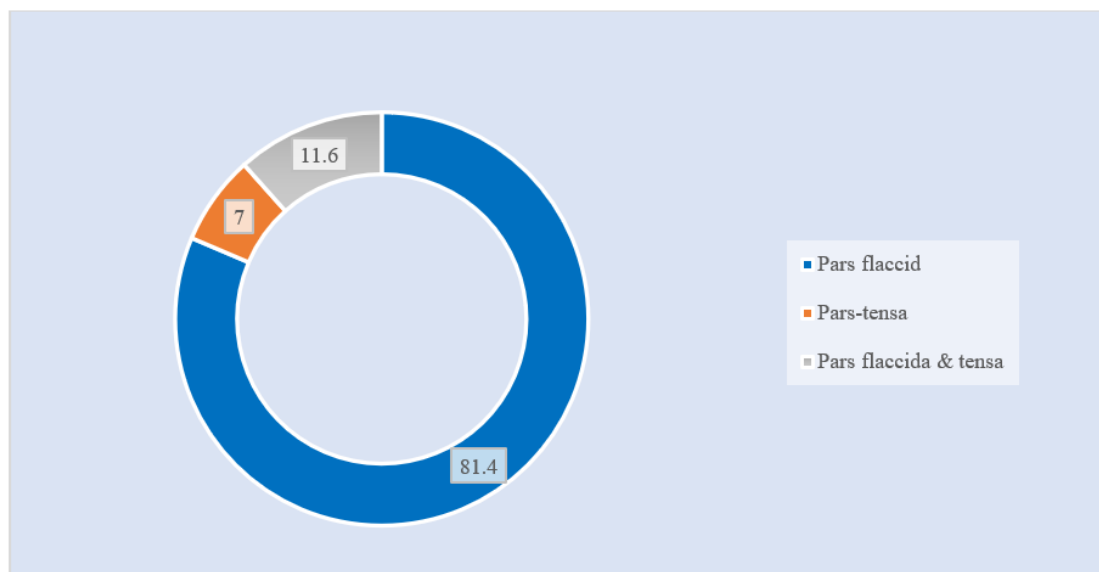
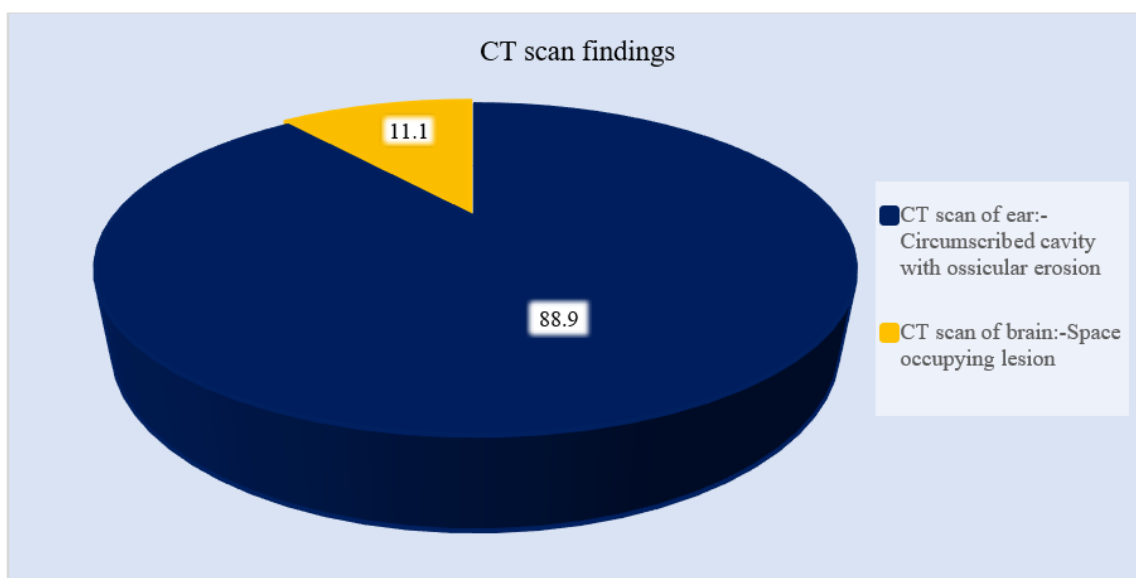


Figure III: Ring chart showed Site of cholesteatoma of the patients (N=43)

Table 3: Distribution of complications

Complications	n	%
Postauricular abscess	6	14.0%
Postauricular sinus	5	11.6%
Meningitis	3	7.0%
Facial palsy	2	4.7%
Extradural abscess	1	2.3%
Lateral sinus thrombophlebitis	1	2.3%
Temporal lobe abscess	1	2.3%

**Figure IV: Pie chart showed CT scan findings of the patients (n=18)**

DISCUSSION

This study aimed to assess the clinical presentations and complications among cholesteatoma cases. In this current study, more than half (51%) of our patients belonged to the 11-20 years' age group, followed by 20.9% from the ≤ 10 years' age group, and 16.3% from the 21-30 years age group. Similar findings were reported in another study [10]. We observed that the highest number of patients (93.0%) presented with ear discharge as a symptom. The second most common symptom was hearing impairment, found in 74.4% of cases. Additionally, earache (16.3%), fleshy mass in the ear (14%), post auricular painful swelling (4.7%), and fever (11.6%) were found in more than 10% of cases. A study conducted by Khan, ASGHAR ULLAH, *et al.*, demonstrated that 90.4% of cases presented with a discharge symptom, which is consistent with the findings of this study [11]. In the majority of our patients (81.4%), involvement of the pars flaccida was observed. Additionally, both pars flaccida and pars tensa were involved in 11.6% of cases, while pars tensa alone was involved in 7% of cases. Regarding complications, postauricular abscesses were the most common, accounting for 14.0% of cases, followed by postauricular sinuses at 4.7%. Meningitis occurred in 7.0% of cases, while facial palsy was observed in 4.7%. These findings align with those reported in a study by [12], but contrast

with studies [13,14], which reported intracranial complications in approximately 12% of cholesteatoma cases. Among the total patients, 18 underwent CT scan evaluations. In 16 cases, CT scans revealed a circumscribed cavity with ossicular erosion, while in 2 cases, space-occupying lesions were identified in the brain. The diagnosis of intracranial abscess, especially as a complication of chronic suppurative otitis media or cholesteatoma and other causes, is challenging but crucial [15]. In developing setups, the incidence of intracranial complications remains higher with cholesteatoma. However, it is worth noting that the incidence of intracranial complications has decreased from 2.3-5% to 0.24% in recent times [16,17]. All the findings from this current study may prove valuable for future research endeavors in similar areas.

LIMITATION OF THE STUDY

This study was conducted at a single center with a small sample size and over a relatively short period. Therefore, it's important to note that the findings of this study may not accurately reflect the broader scenario across the entire country.

CONCLUSION & RECOMMENDATION

In cases of cholesteatoma, prevalent symptoms include ear discharge and hearing impairment, often

accompanied by postauricular abscesses and sinuses as common complications. Pars flaccida involvement is frequently observed in these cases, contributing to the characteristic presentation. Due to the complexity of cholesteatoma and the need for precise diagnosis, computed tomography (CT) scans may be necessary for many patients to accurately assess the extent of the lesion and its associated complications. By utilizing CT imaging alongside thorough clinical evaluation, healthcare providers can effectively diagnose cholesteatoma, tailor treatment plans, and mitigate the risk of further complications, ultimately improving outcomes for affected individuals.

REFERENCES

1. Khan, M. A., Asaduzzaman, A. K. M., Islam, M. T., Ahmed, B., Hossain, M. K., Sumon, M. M. A. K., & Rabbani, S. M. G. (2017). Clinical presentation of cholesteatoma-A study of 50 cases. *Headache*, 5, 10.
2. Cawthorne, T. (1971). Congenital cholesteatoma. *Acta oto-rhinolaryngologica Belgica*. 25(6):833-6.
3. McDonald, T. J., Cody, D. T. R., & Ryan Jr, R. E. (1984). Congenital cholesteatoma of the ear. *Annals of Otolaryngology, Rhinology & Laryngology*, 93(6), 637-640.
4. Jackler, R. K. (1989). The surgical anatomy of cholesteatoma. *Otolaryngologic Clinics of North America*, 22(5), 883-896.
5. Sadé, J., & Shatz, A. (1988). Cholesteatoma in children. *The Journal of Laryngology & Otology*, 102(11), 1003-1006.
6. Gray, R. F., & Hawthorne, M. Synopsis of Otolaryngology, 5th ed.
7. Alan, G, Kerr. & John, B. (1997). editors. Scot Brown's Otolaryngology, Otology 6th edn. *Butterworth and Heinemann*.
8. Herald Ludman Tony wright, Editors, Disease of the ear, 6th ed, 1998.
9. Ballenger, J.J. (1985). Disease of ear nose and throat. Head Neck, 13th ed. *Philadepiphia Lea and Fabiger*, 11360-42.
10. Khan, M. A., Asaduzzaman, A. K. M., Islam, M. T., Ahmed, B., Hossain, M. K., Sumon, M. M. A. K., & Rabbani, S. M. G. (2017). Clinical presentation of cholesteatoma-A study of 50 cases. *Headache*, 5, 10.
11. Khan, A. U., Khan, Q. A. I. S. A. R., Ahmed, N. A. S. E. E. R., Ullah, I., & Khan, M. F. (2013). Clinical findings and diagnosis of cholesteatoma. *Pak J Med Health Sci*, 7, 1184-9.
12. Kempainen, H. O., Puhakka, H. J., Laippala, P. J., Sipilä, M. M., Manninen, M. P., & Karma, P. H. (1999). Epidemiology and aetiology of middle ear cholesteatoma. *Acta oto-laryngologica*, 119(5), 568-572.
13. Nyrop, M., & Bonding, P. (1997). Extensive cholesteatoma: long-term results of three surgical techniques. *The Journal of Laryngology & Otology*, 111(6), 521-526.
14. ALHO, O. P., Jokinen, K., Laitakari, K., & Palokangas, J. (1997). Chronic suppurative otitis media and cholesteatoma. Vanishing diseases among Western populations?. *Clinical Otolaryngology & Allied Sciences*, 22(4), 358-361.
15. Page, C., Lehmann, P., Jeanjean, P., Strunski, V., & Legars, D. (2005, June). Intra cranial abscess and empyemas from ENT origin. In *Annales D'oto-laryngologie et de Chirurgie Cervico Faciale: Bulletin de la Societe D'oto-laryngologie des Hopitaux de Paris* (Vol. 122, No. 3, pp. 120-126).
16. Spiegel, J. H., Lustig, L. R., Lee, K. C., Murr, A. H., & Schindler, R. A. (1998). Contemporary presentation and management of a spectrum of mastoid abscesses. *The laryngoscope*, 108(6), 822-828.
17. Tekin, M., Osma, Ü., Meriç, F., & Topçu, İ. (2002). Kolesteatomlu kronik otitis media: Olguların klinik değerlendirilmesi. *The Turkish Journal of Ear Nose and Throat*, 9(4), 263-266.