

A Giant Dermatofibrosarcoma of Darier-Ferrand of the Abdominal Wall: A Surgical Management Challenge

Ahmed OUBIHI^{1,2*}, Mohammed FDIL^{1,2}, Abdesslam BOUASSRIA^{1,2}, Hicham EL BOUHADDOUTI^{1,2}, Oudii MOUAQIT^{1,2}, Khalid AIT TALEB^{1,2}, El Bachir BENJELLOUN^{1,2}

¹Department of Visceral Surgery A, CHU Hassan II, Fez, Morocco

²Faculty of Medicine and Pharmacy, Sidi Mohammed Ben Abdellah University, Fez, Morocco

DOI: [10.36347/sajs.2024.v10i07.022](https://doi.org/10.36347/sajs.2024.v10i07.022)

| Received: 22.05.2024 | Accepted: 03.07.2024 | Published: 16.07.2024

*Corresponding author: Ahmed OUBIHI

Department of Visceral Surgery A, CHU Hassan II, Fez, Morocco

Abstract

Case Report

Darier-Ferrand dermatofibrosarcoma is a rare skin tumor, generally diagnosed late, given its character, its slow and painless evolution as well as its lack of awareness by practitioners. After histological confirmation, treatment is planned according to the location and extent of the lesions in order to predict possible aesthetic and functional sequelae. Surgical resection and the gold standard. It is because of the high recurrence rate associated with wide local excision, the introduction of Mohs micrographic surgery, when the technical platform is suitable, has really helped to reduce recurrence rates dermatofibrosarcoma. But skin reconstruction, after significant loss of substance secondary to a resection respecting safety margins, represents a surgical challenge. Imatinib is recommended for neoadjuvant treatment to reduce tumor mass as well as in cases of unresectable or metastatic tumors. radiotherapy can be offered after incomplete surgery without any benefit after complete resection. In this paper we report the case of a patient operated for extensive lesions of the subumbilical wall in favor of a Darier-Ferrand dermatofibrosarcoma whose management of the loss of substance was a surgical challenge.

Keywords: Case Report, Dermatofibrosarcoma of Darier-Ferrand, Surgical Resection, Skin Reconstruction.

Copyright © 2024 The Author(s): This is an open-access article distributed under the terms of the Creative Commons Attribution 4.0 International License (CC BY-NC 4.0) which permits unrestricted use, distribution, and reproduction in any medium for non-commercial use provided the original author and source are credited.

INTRODUCTION

Darier-Ferrand dermatofibrosarcoma (DFS) is a rare mesenchymal tumor, representing the most common cutaneous sarcoma [1]. It was described by Darier and Ferrand in 1924 [2]. It generally appears in adults between 20 and 50 years of age, preferentially on the trunk and limbs [1-3]. The cases reported in the literature are not numerous and the management does not follow a consensus. This management of DFS requires a multidisciplinary approach regardless of the clinical or immunohistochemical variant. Surgery is the standard treatment for localized diseases with a high propensity for local recurrence [3, 4]. Surgical management is a technical challenge due to the importance of substance losses [1]. We report the case of a patient admitted for extensive subumbilical lesions in favor of a Darier-Ferrand dermatofibrosarcoma whose skin reconstruction presented a challenge given the importance of the loss of substance after a wide surgical resection.

CASE REPORT

71-year-old man, without notable pathological history, presenting a subcutaneous and subumbilical

mass evolving for a year, slightly painful, with progressive increase in volume, without notion of pruritus or ulceration, with preservation of the condition general. The physical examination finds a patient in good general condition with a subcutaneous subumbilical mass of 06 cm of firm, rigid consistency, well limited without inflammatory signs nearby, mobile in relation to the deep plane, as well as multiple formations cutaneous subumbilical, with a pedicled implantation base (figure 1). Without other abnormalities on clinical examination. A biopsy whose histological study favors a spindle cell tumor, benign in appearance, evoking either a histiocytofibroma, a schwannoma or a neurofibroma. The immunohistochemical complement showing a slightly atypical spindle cell tumor proliferation with diffuse CD 34+, suggesting the diagnosis of Darier-Ferrand dermatofibrosarcoma. Thoracoabdominopelvic CT shows a subcutaneous subumbilical parietal tumor mass, measuring 57*48*61 mm, without invasion of the aponeurosis of the rectus muscle or the umbilicus, associated with multiple nodular cutaneous lesions of the abdominal wall anterior surrounding, the largest of which measure 13*14 mm and 43*12 mm (figure 2). Without other specific anomalies.

Citation: Ahmed OUBIHI, Mohammed FDIL, Abdesslam BOUASSRIA, Hicham EL BOUHADDOUTI, Oudii MOUAQIT, Khalid AIT TALEB, El Bachir BENJELLOUN. A Giant Dermatofibrosarcoma of Darier-Ferrand of the Abdominal Wall: A Surgical Management Challenge. SAS J Surg, 2024 Jul 10(7): 844-850.

When the patient was admitted, a large single-piece surgical resection was indicated but the major challenge was skin reconstruction given the extent of the lesions as well as the loss of substance expected after the resection. The first surgical stage consisted of a complete cutaneous and subcutaneous excision up to the aponeurotic plane in a single piece, removing all the lesions, with a minimum safety margin of 01 cm, leaving a significant loss of substance (figure 3.A). The second stage of the intervention consisted of performing an abdominoplasty with transposition of the umbilicus. The abdominal flap was taken off along the plane of the fascia up to the xiphoid symphysis above, the pubis below and the middle axillary line outside with preservation of the umbilicus in place to allow coverage of the loss of substance by the skin flap despite non-optimal skin elasticity. The abdominal flap was replaced then sutured

in two layers on suction redons. The neoumbilicus was transposed and fixed (figure 3.B).

Pathological studies of the skin resection piece measuring 19.5*13.5*1.5 cm (figure 4) showing a histological and immunohistochemical appearance of a Darrier-Ferrand dermatofibrosarcoma. With healthy limits, the closest peripheral limit was 4mm and the depth was 2mm.

The postoperative course was simple with wearing an abdominal compression belt for 6 weeks. Redons were collected before the home release at POD4. The early postoperative result was satisfactory. Currently, 1 year after the operation, the aesthetic and functional results are satisfactory for the patient without any notion of local recurrence.

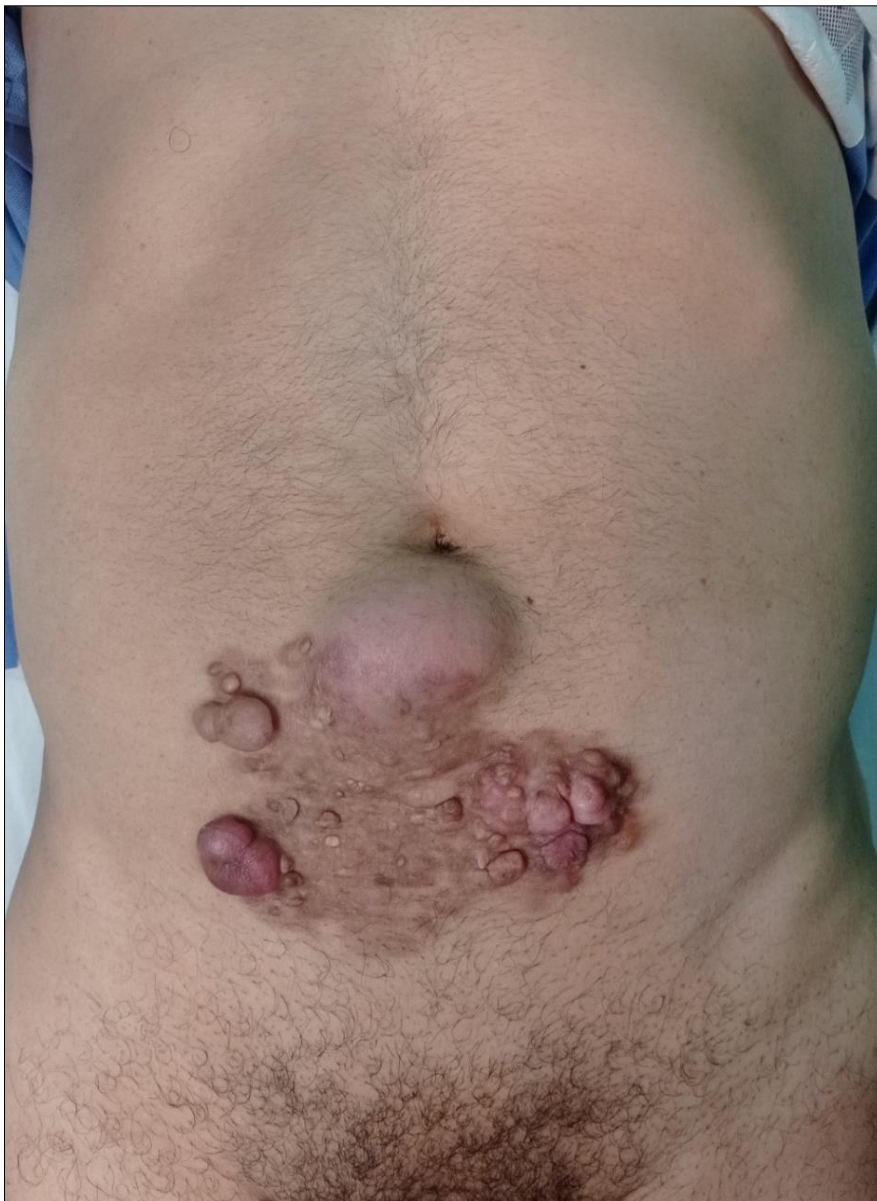

Figure 1: Clinical aspect, multiple extensive subumbilical cutaneous and subcutaneous lesions

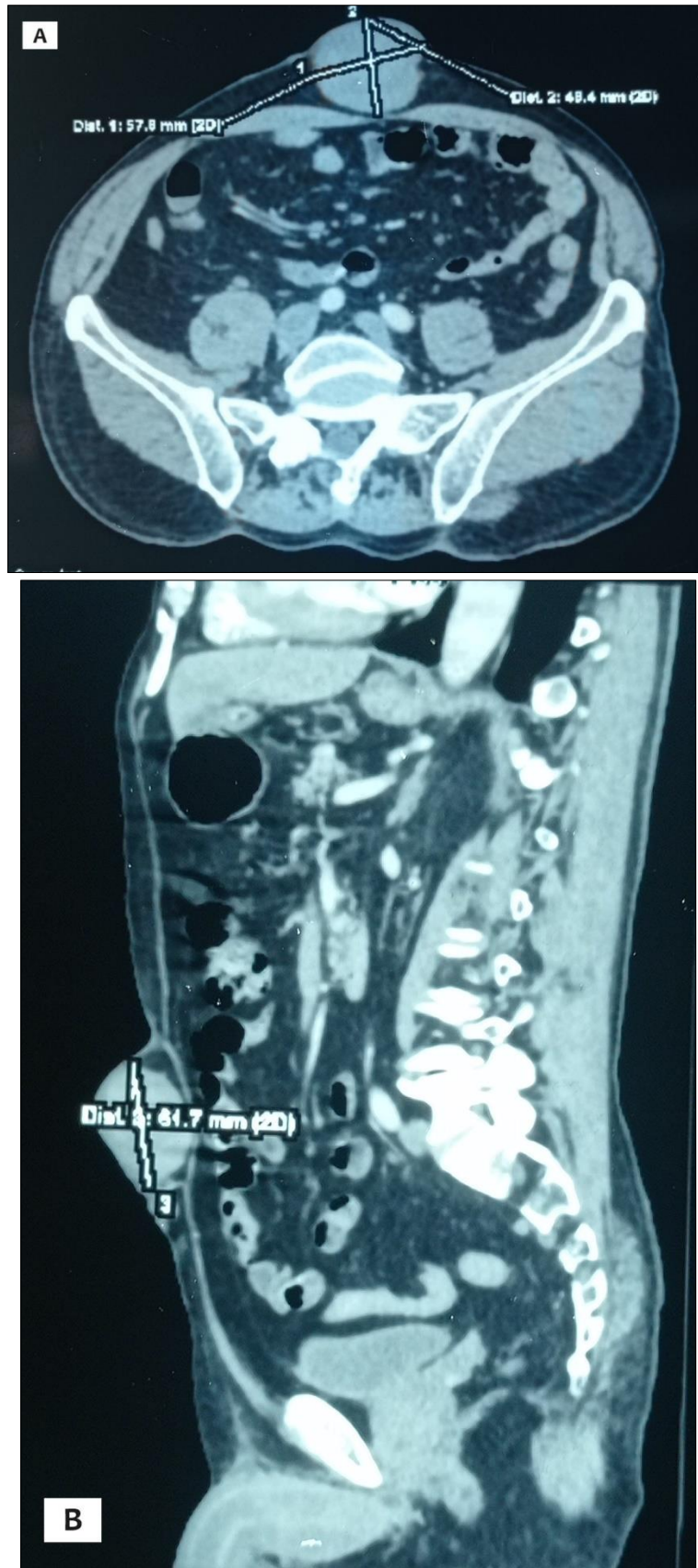


Figure 2: CT axial and sagittal sections passing through the largest mass, measuring 57*48*61 mm, with cutaneous and subcutaneous development without invasion of the aponeurosis of the rectus muscle or the umbilicus

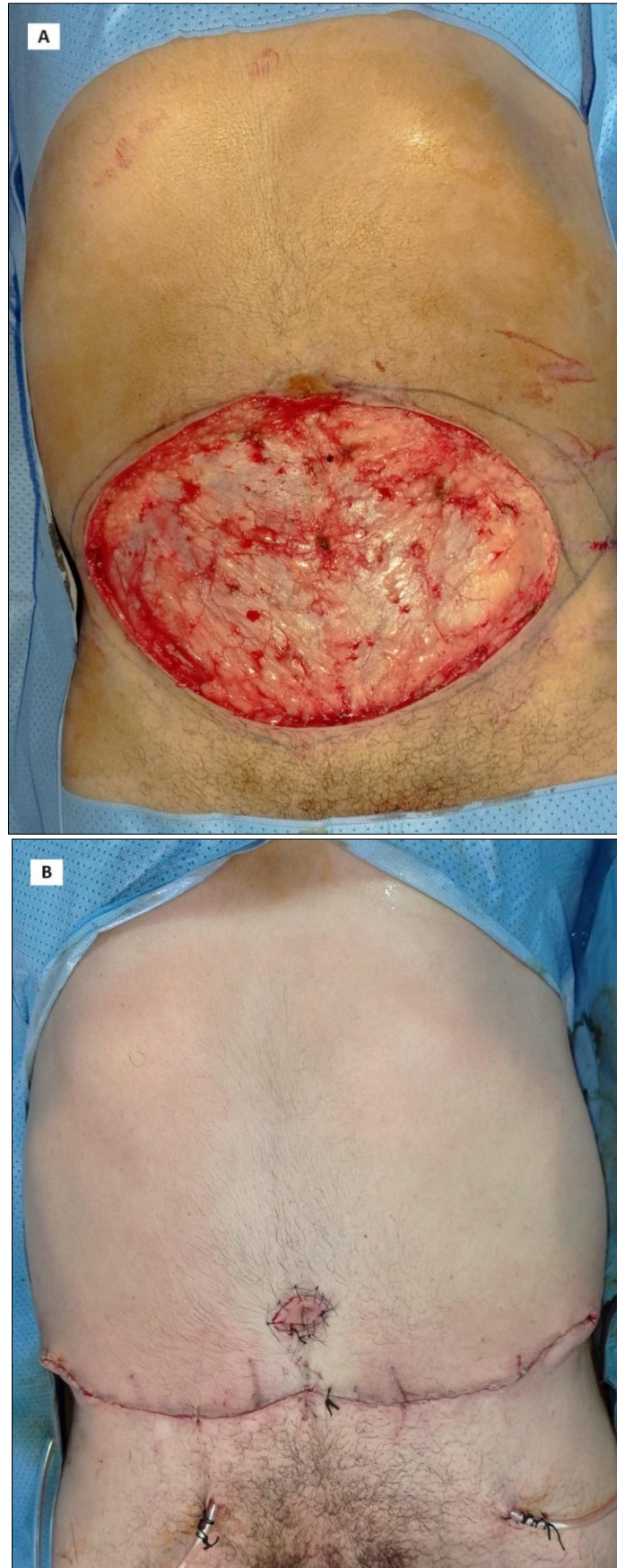


Figure 3: Operative findings: Wide single-piece resection up to the aponeurotic plane with significant loss of substance (A); Final appearance after abdominoplasty with transposition of the umbilicus (B)

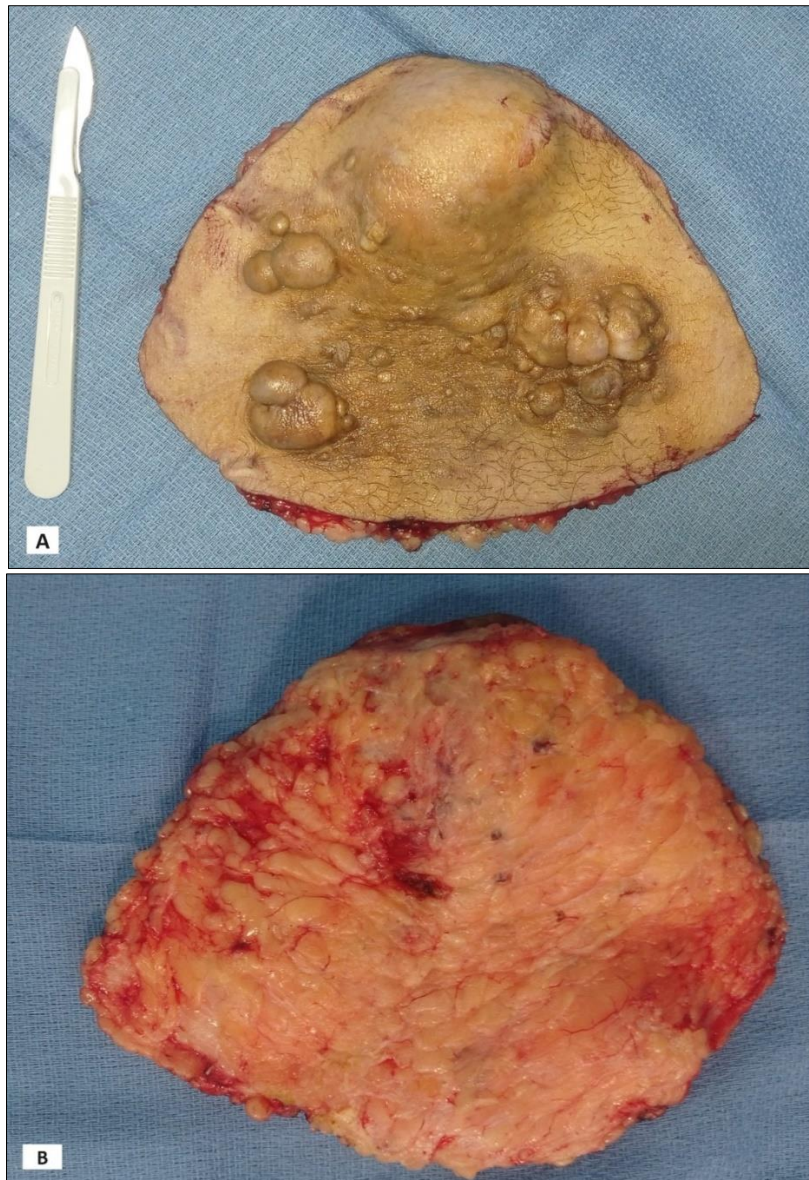


Figure 4: Surgical specimen of the cutaneous and subcutaneous resection measuring 19.5*13.5*1.5 cm; anterior (A) and deep (B) view

DISCUSSION

DFS is a rare, low-grade mesenchymal tumor with intradermal development, accounting for 1.8% of all soft tissue sarcomas and only 0.1% of all cancers. Which mainly affects young adults aged 20 to 50 with a female predominance of 1.58 [3-5]. It was first described by Taylor in 1890 and then by Darier and Ferrand in 1924 [2-6]. It is characterized by slow infiltrative growth, local aggressiveness, and a high potential for local recurrence if not properly treated. However, distant metastases are extremely rare ($\approx 5\%$) and generally occur as a late sequela after local recurrences [6]. DFS rarely presents with lymphatic or hematogenous spread [3].

It occurs after local trauma in 10 to 20% of cases which could aggravate a pre-existing disorder and can also occur on healthy skin without pre-existing dermatosis or local trauma as in our case [4]. Usually,

most patients with DFS may present quite late, when the tumor is in the protruding phase, due to its rarity and indolent onset [3].

DFS can affect the entire human body. The trunk is the most frequent site of DFS lesion which was at 52.80% then the areas of the upper and lower limbs and the areas of the head and neck at 31.75% and 15.45% respectively [3, 4]. The size varies according to publications between 1 to 5cm, reaching 30cm [4-10]. This lesion is painful in 10 to 25% of cases, due to the mass effect when it increases in volume and the presence of hemorrhagic ulcerations. Most authors report the clinical evolution in two stages [4-7]:

- The infiltrative stage: the lesion appears as an indurated plaque, covered with normal skin, pink or purplish in color, well defined and mobile in relation to the deeper planes. More

rarely, it presents as a firm nodule, an atrophic plaque or a sclerodermiform lesion.

- The nodular stage: this initial lesion spreads and becomes irregular, producing after a few months to a few years, a multinodular mass, often polychrome, hard and mobile.

The transformation into a malignant fibrosarcomatous form can be either *de Novo* or after a long progressive history of the disease [4-7].

The ultrasound mainly shows a hypoechoic mass richly vascularized on Doppler. The CT scan shows a solitary, well-defined, isodense, cutaneous or subcutaneous mass without calcifications and the MRI shows a well-defined mass, isointense with the muscle on T1, and hypointense on T2. Radiological extension assessment is only recommended for patients whose clinical examination raises suspicion of metastases, in cases of recurrent DFS and in cases of sarcomatous transformation [8].

The treatment of DFS is surgical, the superiority and effectiveness of surgery unequivocal. The difficulty of surgery lies in the subclinical extension of the tumor. The most widespread technique is that of wide local excision (WLE) with a safety margin of 3 to 5cm lateral and in depth with sacrifice of a healthy anatomical barrier, without lymph node dissection [1-4]. Histologically, the tumor is considered a low-grade sarcoma of malignancy made of a dense cellular proliferation, poorly limited, not encapsulated, occupying the dermis most often in its entirety, and sending fine extensions sometimes very deep into the hypodermis. , which explains the recurrences, the epidermis is respected and the cells are arranged in radiating bundles (Wheel Spoke appearance) which are very evocative [4, 5].

Mohs micrographic surgery (MMS) is an alternative to wide excision that is considered by some to be the preferred treatment for DFS. This is an ablation method that provides precise microscopic control of the entire tumor margin while maximizing the preservation of healthy tissue. It is performed by removing a thin margin of tissue circumferentially around and deep to the clinical tumor which is then examined under a microscope. The process is repeated until the tumor shows negative histological margins. This technique takes longer and requires a suitable technical platform. The reconstruction is carried out in a second step, particularly when performing a slow Mohs with paraffin embedding [1-6]. A meta-analysis conducted between 2008 to 2018 including 684 patients revealed that the recurrence of DFS after WLE and MMS was 9.10% and 2.72% respectively after an average follow-up time for the two groups of 5.32 years. [3].

Concerning the coverage of the loss of substance, the therapeutic alternatives are numerous.

such as skin grafting, abdominoplasties with or without transposition of the umbilicus, the placement of synthetic material to reinforce the weakening of the abdominal wall secondary to an aponeurotic or associated muscular resection, the use of a flap pedicled rectus latissimus dorsi muscle, thus, a reverse abdominoplasty with transposition of the umbilicus has been reported for an epigastric location. All these options and others must be discussed depending on the location, extent of the lesions as well as their functional and aesthetic results in consultation with the patient [1].

Radiotherapy finds its place for recurrences, multiple locations, large tumors or inoperable primary, locations preventing wide excision and especially after an insufficient or invaded excision margin [1-9]. A combination of conservative excision and adjuvant radiotherapy has been reported to reduce the local recurrence rate by 5% [6]. In case of healthy margin, no adjuvant treatment is necessary. DFS are characterized by a translocation between chromosomes 17 and 22 t (17,22) with overexpression of the PDGFRB receptor which is an exploitable receptor that can be targeted by Imatinib. In fact, some studies have shown its interest, it is a tyrosine kinase inhibitor which has proven its effectiveness in localized and metastatic DFS in the presence of t (17,22), and consequently it constitutes an option in case of unresectable, recurrent or metastatic tumor and it is preferable to carry out a cytogenetic study looking for t (17,22) before initiating it [4-9]. In the case of metastatic disease that has progressed under Imatinib, chemotherapy can be attempted by analogy with soft tissue sarcomas, these are most often protocols based on mono or polychemotherapy with Doxorubicin, Ifosfamide, Epirubicin, Gemcitabine, Dacarbazine, Temozolomide, Vinorelbine or a tyrosine kinase inhibitor based on Pazopanib [9].

There is no consensus regarding the rate of surveillance which must be focused on clinical examination and maintained over time due to the slow evolution and recurrent potential of this tumor. Monitoring can be done every 3 to 6 months for the first 5 years and then annually. Sometimes an MRI will be used in a few selected cases [4].

The most commonly cited predictive factors for recurrence are: size, rapid progression and especially the quality of initial excision [4].

CONCLUSION

Despite the rarity of Darier-Ferrand fibrosarcoma and its slow progression, the high risk of recurrence and the aesthetic and functional prognosis make its surgical management a challenge mainly for skin coverage. Chemotherapy and radiotherapy have limited indications without consensus based on high-level clinical trials.

Conflicts of Interest: The authors declared no potential conflicts of interest with respect to the research, authorship, and/or publication of this article.

REFERENCES

1. Bilger, G., Nicolai, M., Perez, M., & Simon, E. (2021, March). Case report: Epigastric dermatofibroma reconstruction by reverse abdominoplasty with umbilic transposition. In *Annales de Chirurgie Plastique et Esthetique* (Vol. 66, No. 3, pp. 261-267).
2. Darier, J. (1924). Dermatofibromes progressifs et recidivants ou fibrosarcomes de la peau. *Ann. Dermatol. Venereol.*, 5, 545-562.
3. Malan, M., Xuejingzi, W., & Quan, S. J. (2019). The efficacy of Mohs micrographic surgery over the traditional wide local excision surgery in the cure of dermatofibrosarcoma protuberans. *Pan African Medical Journal*, 33(1).
4. Loukil, I., Zouari, A., & Abid, B. (2021). Dermatofibrosarcoma protuberans (Darier-Ferrand) of the abdomen: a case report. *The Pan African Medical Journal*, 38, 365-365.
5. Ouahbi, H., Amadour, L., Elmernissi, F., Tahiri, L., Harmouch, T., Benbrahim, Z., ... & Mellas, N. (2019). Outcome of locally advanced Darier and Ferrand dermatofibrosarcoma: about a case and literature review. *The Pan African Medical Journal*, 32, 97-97.
6. Triki, A., Aloui, M., Ghaleb, M., Jbir, I., Naceur, B., Hassouna, J. B., ... & Rahal, K. (2021). Giant Darier-Ferrand dermatofibrosarcoma protuberans of the abdomen and pelvis: a case report. *Journal of Medical Case Reports*, 15, 1-4.
7. Frikha, F., Mseddi, M., Bahloul, E., Chaabouni, R., Masmoudi, A., Boudaya, S., ... & Turki, H. (2020). Dermatofibrosarcoma protuberans (Report of 49 cases). *Our Dermatol Online*, 11(1), 25-31.
8. Zhang, L., Liu, Q. Y., Cao, Y., Zhong, J. S., & Zhang, W. D. (2015). Dermatofibrosarcoma protuberans: computed tomography and magnetic resonance imaging findings. *Medicine*, 94(24), e1001.
9. Guerrouaz, M. A., Kharkhach, A., Miry, A., Harroudi, T. E., Sbai, A., & Mezouar, L. (2022). Recurrent Darier-Ferrand dermatofibrosarcoma in the abdominal wall: the role of preoperative radiotherapy (case report). *The Pan African Medical Journal*, 41, 234-234.
10. Hammas, N., Badioui, I., Znati, K., Benlemlih, A., Chbani, L., El Fatemi, H., ... & Amarti, A. (2014). Dermatofibrosarcoma protuberans: report of 27 cases and review of the literature. *The Pan African Medical Journal*, 18, 280-280.