

Post Obstructive Acute Pulmonary Edema after Sedation

H. Asri^{1*}, A. Zegmout¹, A. Rafik¹, H. H. Souhi¹, H. Elouazzani¹, I. Rhorfi¹

¹Pulmonology and Phtisiology Department of Mohamed V Military Hospital Teaching, Rabat, Morocco

DOI: [10.36347/sjmcr.2024.v12i07.019](https://doi.org/10.36347/sjmcr.2024.v12i07.019)

| Received: 26.04.2024 | Accepted: 02.06.2024 | Published: 19.07.2024

*Corresponding author: H. Asri

Pulmonology and Phtisiology Department of Mohamed V Military Hospital Teaching, Rabat, Morocco

Abstract

Case Report

Post-obstructive acute pulmonary edema (POAPE) is a serious and rare respiratory complication, especially under sedation. We report the case of a patient without comorbidities undergoing sedated colonoscopy who developed respiratory distress, desaturation, and clinical and radiological signs suggestive of acute pulmonary edema. Etiological investigations, including cardiac assessment, returned normal, and the patient's condition improved within hours. The diagnosis of post-obstructive pulmonary edema was established. Through this case report, we emphasize the seriousness of this complication, necessitating early intervention.

Keywords: Post obstructif, edema, sedation, coloscopy.

Copyright © 2024 The Author(s): This is an open-access article distributed under the terms of the Creative Commons Attribution **4.0 International License (CC BY-NC 4.0)** which permits unrestricted use, distribution, and reproduction in any medium for non-commercial use provided the original author and source are credited.

INTRODUCTION

Negative pressure pulmonary edema (NPPE) is an unexpected complication that can have fatal consequences. Prevention is crucial and relies on identifying predisposing factors and early diagnostic and therapeutic management. The pathophysiology of NPPE involves increased intrathoracic pressure following difficult inspiration against obstructed upper airways, in this case, upper respiratory infections, leading to fluid extravasation into the pulmonary interstitium. We present a clinical observation of NPPE complicating a sedated colonoscopy, preceded by upper respiratory infection, resulting in upper airway obstruction.

CASE REPORT

A 67-year-old occasional smoker with no comorbidities presented respiratory distress during sedated colonoscopy: ambient air oxygen saturation was 70% with bilateral crepitant rales. The patient reported sore throat and headache three days prior. Thoracic CT scan revealed diffuse bilateral alveolo-interstitial involvement suggestive of non-cardiogenic pulmonary edema. Laboratory tests were unremarkable, and spontaneous improvement occurred within 24 hours, with radiological resolution within a week, confirming the diagnosis of post-obstructive pulmonary edema.

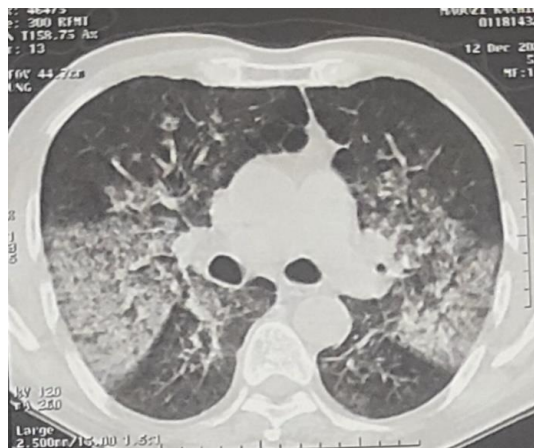


Figure 1: The thoracic CT scan reveals diffuse bilateral alveolo-interstitial involvement suggestive of non-cardiogenic pulmonary edema

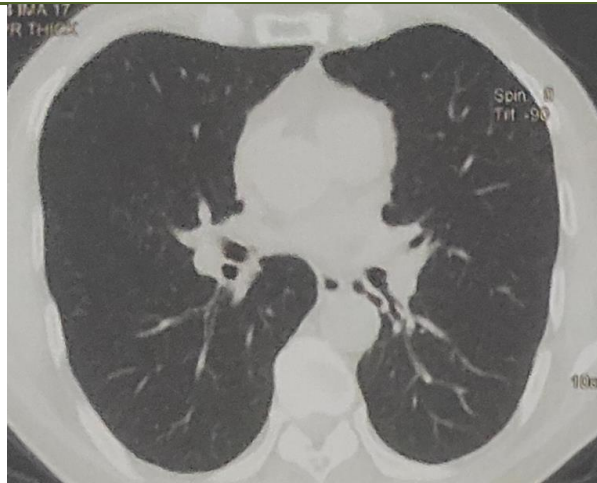


Figure 2: Shows the resolution of radiological lesions one week a later

DISCUSSION

NPPE was first described in 1973, categorized into two subtypes: type I associated with violent inspiratory efforts in acute airway obstructions, and type II associated with relief from chronic partial airway obstructions [1]. Incidence ranges from 0.1% to 11%, with higher prevalence in males and ASA physical statuses I and II [2] Risk factors include obesity, upper airway obstruction, short neck, upper airway surgery, obstructive sleep apnea syndrome, and mediastinal masses. Differential diagnoses include cardiogenic pulmonary edema, intraoperative fluid overload, COVID-19 infection, anaphylaxis, and acute respiratory distress syndrome [3].

The pathophysiology of NPPE involves acute airway obstruction leading to significant negative intrathoracic pressures, increasing right heart preload and pulmonary venous pressure, resulting in interstitial fluid extravasation. Hypoxia-induced peripheral vasoconstriction exacerbates the hydrostatic gradient [4]. Management typically involves oxygen therapy, with the role of positive end-expiratory pressure (PEEP) unclear, as some cases resolve without specific treatment. The use of diuretics remains controversial [5].

In our patient's case, favorable evolution occurred with high-concentration oxygen therapy alone.

CONCLUSION

NPPE generally has a favorable prognosis. However, healthcare professionals performing procedures under sedation or general anesthesia, radiologists, and anesthesiologists should be aware of this complication and predisposing factors to prevent its occurrence.

REFERENCES

1. Mesrati, M. A., Jaoued, O., Mahjoub, Y., Boussaid, M., Fkih Hassen, M., Atrous, S., & Aissaoui, A. (2020). Postobstructive pulmonary edema: a fatal complication in suicidal near-hanging. *SAGE open medical case reports*, 8, 2050313X20922712.
2. Silva, L. A. R., Guedes, A. A., Salgado, M. F., Chaves, L. F. M., & Araújo, F. D. P. (2019). Edema pulmonar por pressão negativa: relato de casos e revisão da literatura. *Revista Brasileira de anesthesiologia*, 69, 222-226.
3. Onk, D., Işık, O., Subaşı, F., Karaali, S., & Kuyruklyıldız, U. (2022). Negative-pressure pulmonary edema after mammoplasty: a case report. *Pan African Medical Journal*, 42(1), 15.
4. Bouhabba, N., Bensghir, M., Fjouji, S., Azendour, H., & Haimeur, C. (2015). Œdème aigue post chirurgical: Complication redoutable. *Pan African Medical Journal*, 20(1).
5. Van Kooy, M. A., & Gargiulo, R. F. (2000). Postobstructive pulmonary edema. *Am Fam Physician*, 62(2), 401-404.