

Leber's Hereditary Optic Neuropathy Following Unilateral Syphilitic Optic Neuritis

Shinji Makino^{1*}

¹Department of Ophthalmology, Jichi Medical University, Shomotsuke, Tochigi 329-0498, Japan

DOI: [10.36347/sjmcr.2024.v12i07.020](https://doi.org/10.36347/sjmcr.2024.v12i07.020)

| Received: 09.06.2024 | Accepted: 13.07.2024 | Published: 19.07.2024

*Corresponding author: Shinji Makino

Department of Ophthalmology, Jichi Medical University, Shomotsuke, Tochigi 329-0498, Japan

Abstract

Case Report

This report describes a case of Leber's hereditary optic neuropathy (LHON) following unilateral syphilitic optic neuritis. A 31-year-old man presented with a four-day history of decreased vision in his left eye. At the initial visit, the patient's best corrected visual acuity (BCVA) was 1.2 and 0.02 in the right and left eye, respectively, along with a relative afferent pupillary defect in the left eye. Goldmann visual field testing revealed a central absolute scotoma and an enlarged blind spot in the left eye. Serological testing confirmed syphilis with rapid plasma reagin positivity. The patient was diagnosed with syphilitic optic neuritis and treated with intravenous penicillin G (24 million units daily) for two weeks. After two weeks of therapy, his left BCVA improved to 0.4 after two months. However, five months later, despite completing syphilis treatment, the patient developed acute painless visual loss in both eyes. His BCVA decreased to 0.8 and 0.05 in the right and left eyes, respectively. Goldmann visual field testing revealed a central absolute scotoma and an enlarged blind spot in both eyes. After two weeks, BCVA progressively declined to 0.4 in the right and 0.04 in the left eye. Furthermore, Goldmann visual field testing revealed an enlarged central absolute scotoma and blind spot in both eyes. Six months after the initial examination, his BCVA was counting fingers and 0.02 in the right and left eye, respectively. The optic discs appeared diffusely pale in both eyes. Genetic testing for LHON revealed a pathologic mtDNA 11778 point mutation. This case underscores the importance of considering the possibility of LHON if acute or subacute vision loss occurs subsequently or simultaneously in both eyes and remains unresponsive to treatment.

Keywords: Leber's hereditary optic neuropathy, syphilitic optic neuritis.

Copyright © 2024 The Author(s): This is an open-access article distributed under the terms of the Creative Commons Attribution 4.0 International License (CC BY-NC 4.0) which permits unrestricted use, distribution, and reproduction in any medium for non-commercial use provided the original author and source are credited.

INTRODUCTION

The incidence of syphilis has been increasing worldwide, making it a significant medical problem [1]. Unfortunately, syphilitic ocular manifestations are often undiagnosed because of the lack of typical characteristics. Although ocular disease can affect most components of the eye, uveitis is the most common form of syphilitic eye disease, while optic neuritis occurs infrequently [1-5].

Leber's hereditary optic neuropathy (LHON) is a maternally inherited mitochondrial disease characterized by acute, subacute, painless, sequential, or simultaneous bilateral visual loss [6]. It is often misdiagnosed as optic neuritis in its early stages owing to the acute nature of the disease, which can initially affect one eye [7-9]. To date, only one documented case of typical optic neuritis and LHON in a single patient has been reported [10].

Herein, we report a rare case with syphilitic optic neuritis preceding the onset of LHON in both eyes.

CASE PRESENTATION

A 31-year-old man presented with a four-day history of decreased vision in his left eye. The patient's medical history was insignificant, and he was not taking any medications at that time. His younger brother had decreased vision in both eyes (unknown cause).

At the initial visit, his best corrected visual acuity (BCVA) was 1.2 and 0.02 in the right and left eye, respectively. A relative afferent pupillary defect was observed in the left eye. Slit-lamp examination revealed no cells, flares, or keratic precipitates in the anterior segments of either eye. Fundoscopy revealed no abnormalities in either eye (Figure 1). Goldmann visual field testing revealed a central absolute scotoma and an enlarged blind spot in the left eye (Figure 2).

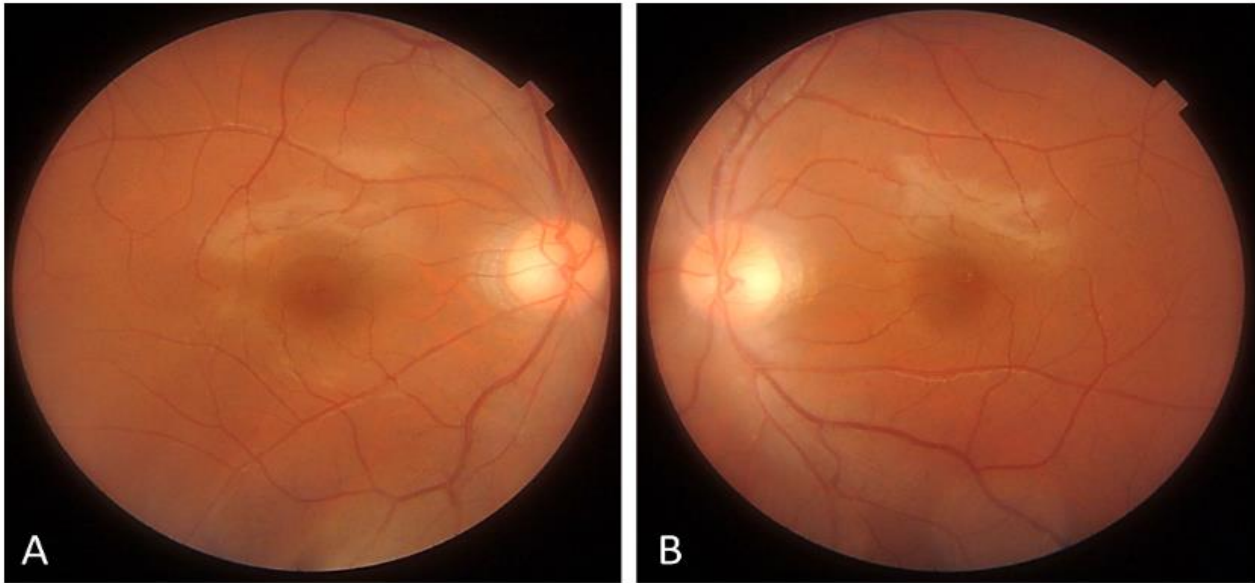


Figure 1: Photographs of the right (A) and left (B) fundus at initial examination

Funduscopy revealed no abnormal findings in either eye.

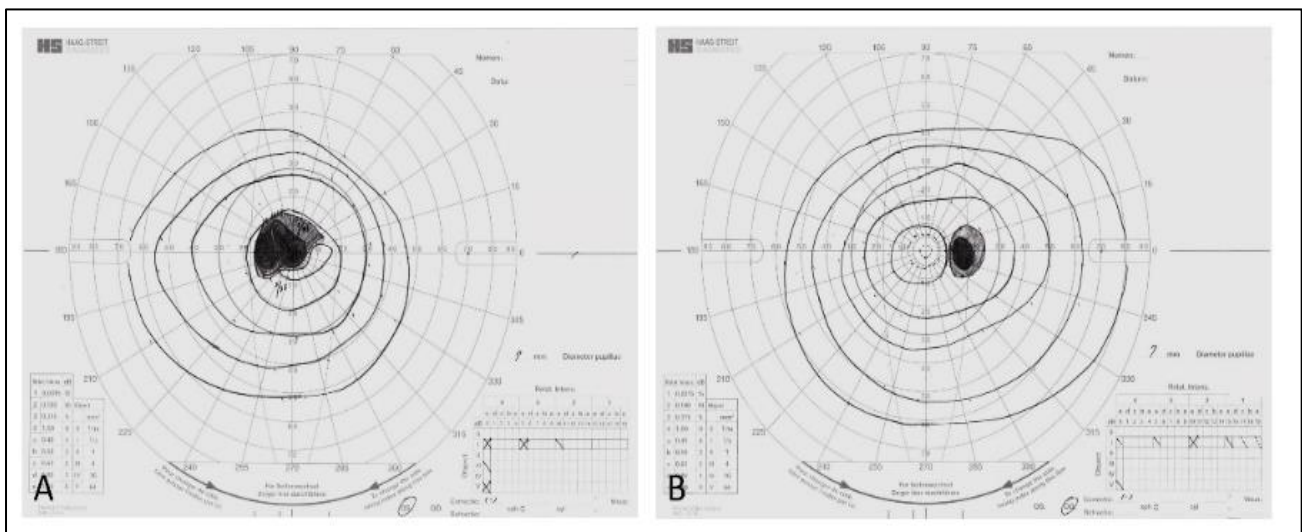


Figure 2: Goldmann perimetry of the left (A) and right (B) eyes

Note the central absolute scotoma and an enlarged blind spot in the left eye.

Baseline blood test results were within normal limits. Serological testing for syphilis revealed positive results for the serum rapid plasma reagin (RPR) (189.0) and the IgM fluorescent treponemal antibody absorption (FTA-ABS) tests. Conversely, the cerebrospinal fluid (CSF) tested negative for RPR and positive for FTA-ABS. The CSF analysis revealed lymphocytic pleocytosis (100 cells/ μ L), and increased protein (36 mg/dL, reference range: 10–40) and glucose content (61 mg/dL, reference range: 50–75). The human immunodeficiency virus serological test results were negative. Fluorescein angiography revealed no abnormalities. T1-weighted orbital contrast-enhanced

magnetic resonance imaging with fat suppression revealed a mildly swollen enhanced lesion in the left optic nerve. The patient was diagnosed with syphilitic optic neuritis and received treatment with intravenous penicillin G (PCG) and intravenous methylprednisolone pulse therapy. Furthermore, we planned to administer 1 g of intravenous methylprednisolone daily for three days. After receiving 1 g of intravenous methylprednisolone daily for three days, his BCVA improved to 0.08 within a week. Funduscopy revealed no particular changes in either eye (Figure 3). Goldmann visual field testing revealed the improvement in the central absolute scotoma and enlarged blind spot in the left eye (Figure 4).

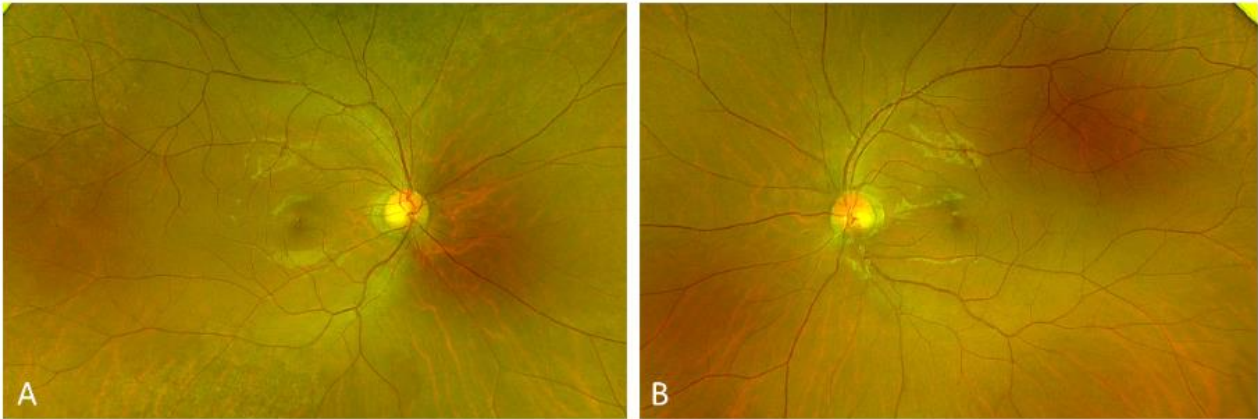


Figure 3: Photographs of the left fundus after the intravenous methylprednisolone pulse therapy

Funduscopy revealed no particular changes in either eye.

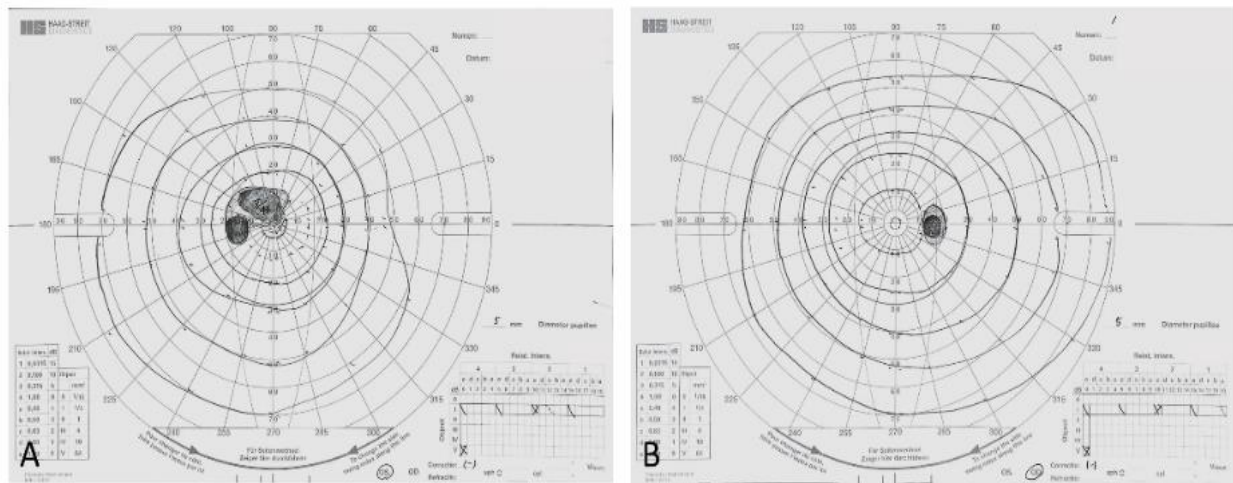


Figure 4: Goldmann perimetry of the left (A) and right (B) eyes after the intravenous methylprednisolone pulse therapy

Note the improvement in the central absolute scotoma and enlarged blind spot in the left eye.

Twenty-four million units of PCG were administered daily for two weeks. After two weeks of

therapy, his left BCVA improved to 0.4 in two months, with no considerable changes noted on funduscopy (Figure 5). Goldmann visual field testing revealed the mild improvement of the central absolute scotoma in the left eye (Figure 6).

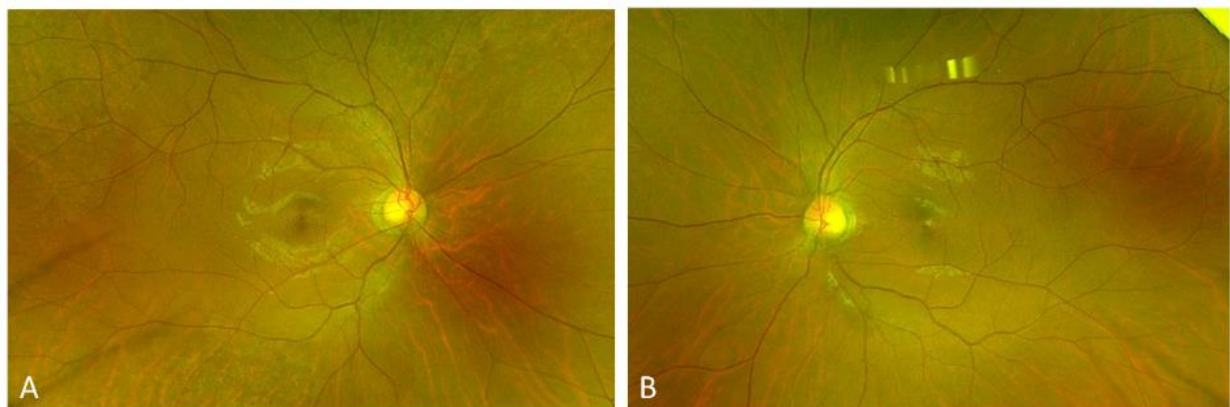


Figure 5: Photographs of the left fundus after the intravenous penicillin G therapy

Funduscopy revealed no particular changes in either eye.

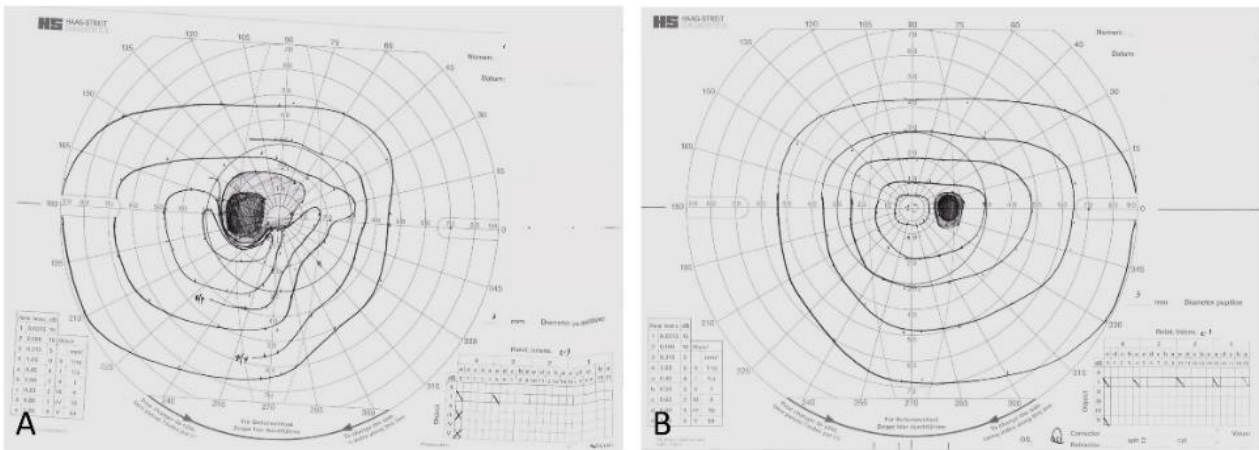


Figure 6: Goldmann perimetry of the left (A) and right (B) eyes after the intravenous penicillin G therapy

Note the mild improvement of the central absolute scotoma in the left eye.

Five months later, despite the completion of the syphilis treatment, the patient experienced acute painless visual loss in both eyes. His BCVA decreased to 0.8 and

0.05 in the right and left eyes, respectively. Fundus examination revealed no particular changes in the right eye; however, mild temporal disc pallor was observed in the left eye (Figure 7). Goldmann visual field testing revealed a central absolute scotoma and enlarged blind spots in both eyes (Figure 8).

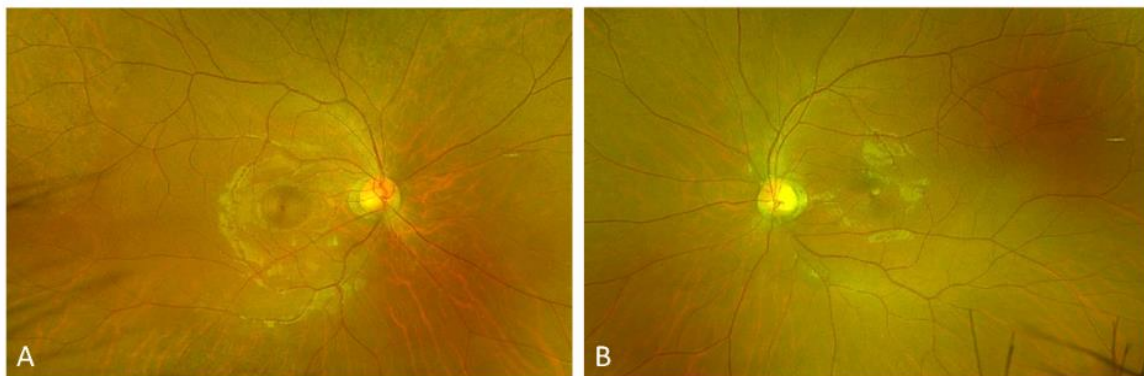


Figure 7: Photographs of the right (A) and left (B) fundus five months after the initial examination

There was no optic disc swelling in the right eye or mild temporal disc pallor in the left eye.

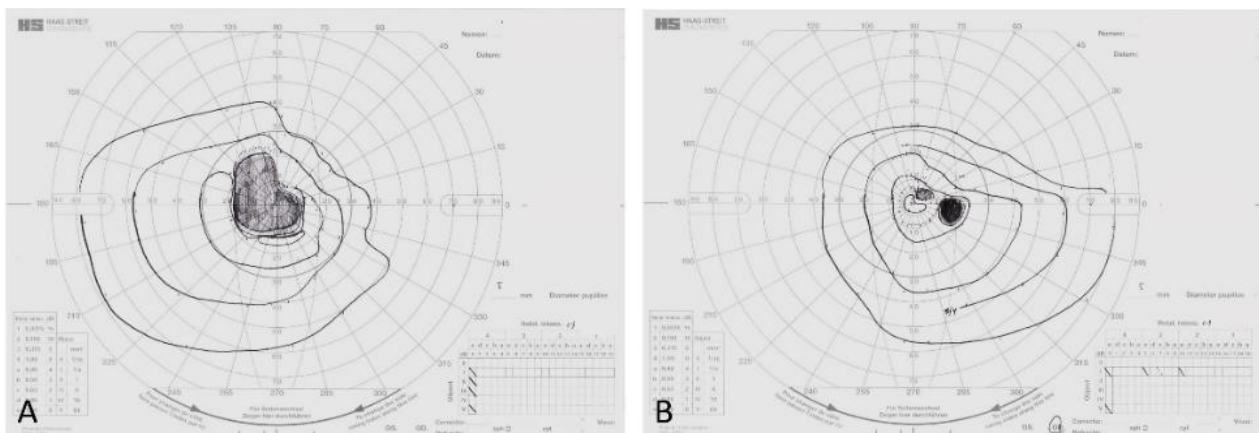


Figure 8: Goldmann perimetry of the left (A) and right (B) eyes five months after the initial examination

Note a central absolute scotoma and enlarged blind spot in both eyes.

After two weeks, the BCVA continued to decline to 0.4 in the right eye and 0.04 in the left eye, with an enlarged central absolute scotoma and blind

spots noted in both eyes on repeat Goldmann visual field testing (Figure 9). Six months after the initial examination, his BCVA was counting fingers in the right eye and 0.02 in the left eye. The optic discs appeared diffusely pale in both eyes (Figure 10).

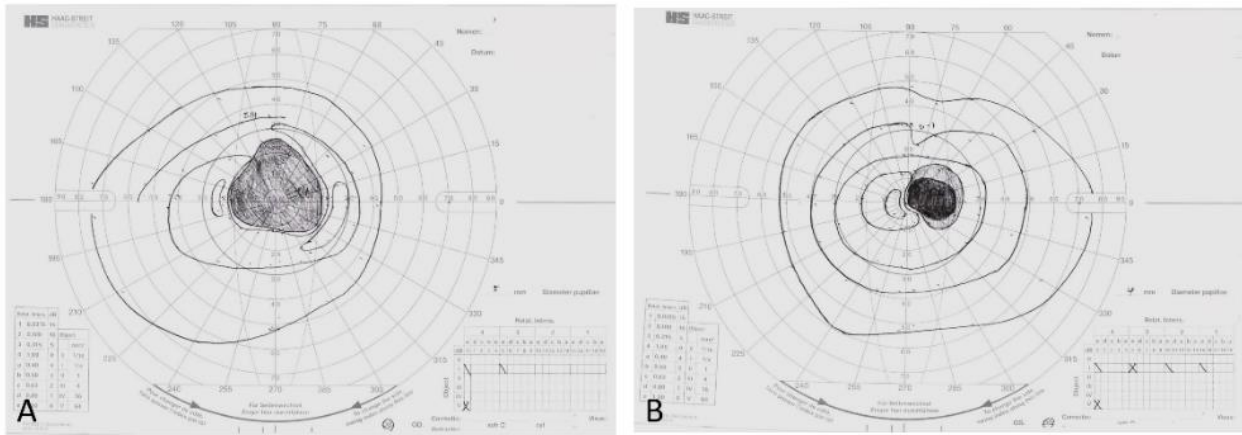


Figure 9: Goldmann perimetry of the left (A) and right (B) eyes

Note enlarged central absolute scotoma and blind spot in both eyes.

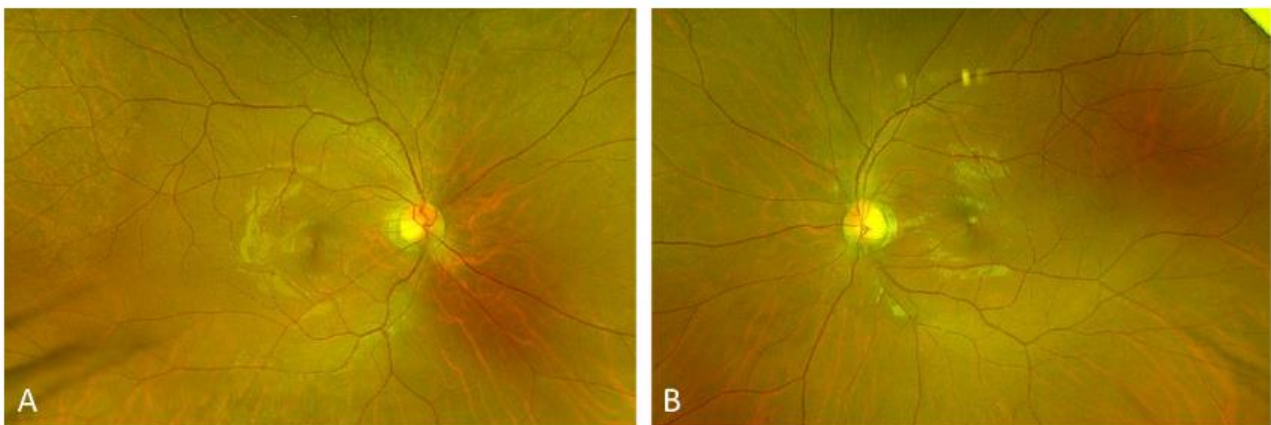


Figure 10: Photographs of the right (A) and left (B) fundus six months after the initial examination

Note the optic disc looked diffusely pale in both eyes.

Genetic testing for LHON revealed a pathologic mtDNA 11778 point mutation (<m.11778G>A; Arg340His>).

DISCUSSION

We presented a case involving syphilitic optic neuritis preceding the onset of LHON.

Leber's hereditary optic neuropathy, a mitochondrial disease caused by genetic mutation [1], is frequently misdiagnosed in its early stage as other types of optic neuropathy [7-9, 11]. Differentiating between LHON and optic neuritis is clinically important because of the associated acute vision loss.

When considering the moderate visual improvement with PCG therapy, it suggests that the initial visual loss in the patient was caused by syphilitic optic neuritis rather than by LHON. Previously, various conditions related to typical optic neuropathies, such as trauma [12], nutritional deficit [13], and ethambutol administration [14], were suggested to be precipitating factors for the development of LHON. Although remains unclear whether the association between syphilitic optic neuritis and LHON is coincidental or if there is an underlying pathogenic relationship, we speculate that syphilitic optic neuritis acted as a factor precipitating the onset of LHON.

CONCLUSIONS

In this report, we highlight a case of syphilitic optic neuritis preceding LHON onset. Clinicians should

consider the possibility of LHON if acute or subacute loss of vision occurs subsequently or simultaneously in both eyes and does not respond to steroids or PCG.

REFERENCES

- 1 Bandettini di Poggio, M., Primavera, A., Capello, E., Bandini, F., Mazzarello, G., Viscoli, C., & Schenone, A. (2010). A case of secondary syphilis presenting as optic neuritis. *Neurological Sciences*, 31(3), 365-367.
- 2 Zhou, X. Y., & Sobol, W. M. (2022). Bilateral papillitis as the initial presentation of neurosyphilis in a patient previously treated for primary and secondary syphilis. *Am J Ophthalmol Case Rep*, 28, 101737.
- 3 Yamashita, S., Tago, M., Nishi, T. M., & Yamashita, S. I. (2022). Unilateral syphilitic optic neuritis without meningitis or uveitis. *Clinical Case Reports*, 10(4), e05678.
- 4 Kabanovski, A., Donaldson, L., Jeeva-Patel, T., & Margolin, E. A. (2022). Optic disc edema in syphilis. *Journal of Neuro-Ophthalmology*, 42(1), e173-e180.
- 5 Gonzalez-Martinez, A., Quintas, S., Vivancos, D. C., Cebrián, J., & Vivancos, J. (2020). Diagnosis of syphilitic bilateral papillitis mimicking papilloedema. *Emerging Infectious Diseases*, 26(1), 171-173.
- 6 Riordan-Eva, P., & Harding, A. E. (1995). Leber's hereditary optic neuropathy: the clinical relevance of different mitochondrial DNA mutations. *Journal of medical genetics*, 32(2), 81-87.
- 7 Chang, M. (2018). Leber's hereditary optic neuropathy misdiagnosed as optic neuritis and Lyme disease in a patient with multiple sclerosis. *BMJ Case Rep*, 11(1), e227109.
- 8 Hsu, T. K., Wang, A. G., Yen, M. Y., & Liu, J. H. (2014). Leber's hereditary optic neuropathy masquerading as optic neuritis with spontaneous visual recovery. *Clin Exp Optom*, 97(1), 84-86.
- 9 McClelland, C. M., Van Stavern, G. P., & Tselis, A. C. (2011). Leber hereditary optic neuropathy mimicking neuromyelitis optica. *Journal of Neuro-Ophthalmology*, 31(3), 265-268.
- 10 Lee, C., Park, K. A., Lee, G. I., Oh, S. Y., Min, J. H., & Kim, B. J. (2020). Leber's hereditary optic neuropathy following unilateral painful optic neuritis: a case report. *BMC Ophthalmol*, 20(1), 195.
- 11 Hashemi, N., Yalamanchili, S. S., Zhang, J., & Lee, A. G. (2012). Leber hereditary optic neuropathy mimicking thyroid-related optic neuropathy. *J Neuroophthalmol*, 32(1), 95-96.
- 12 Apinyawasisuk, S., Chan, J. W., & Arnold, A. C. (2016). Trauma-associated Leber hereditary optic neuropathy. *Neuroophthalmol (Aeolus Press)*, 40(4), 192-196.
- 13 Santos-Garcia, D., Abella, J., De Domingo, B., & de la Fuente-Fernandez, R. (2009). Leber hereditary optic neuropathy associated with malabsorption syndrome after bariatric surgery. *J Neuroophthalmol*, 29(1), 75-76.
- 14 Seo, J. H., Hwang, J. M., & Park, S. S. (2010). Antituberculosis medication as a possible epigenetic factor of Leber's hereditary optic neuropathy. *Clin Exp Ophthalmol*, 38(4), 363-366.