

Boerhaave Syndrome Rare Pathological Entity: About 2 Cases

Alae Chakir^{1*}, Yousfi H¹, Benelhaj¹, Tonguino RN¹, Salek M², Lamsiah T¹

¹Department of Gastroenterology, Moulay Ismail Military Hospital Meknes, Morocco

²Department of Radiology, Moulay Ismail Military Hospital- Meknes, Morocco

DOI: <https://doi.org/10.36347/sjmcr.2024.v12i08.015>

| Received: 22.06.2024 | Accepted: 28.07.2024 | Published: 16.08.2024

*Corresponding author: Alae Chakir

Department of Gastroenterology, Moulay Ismail Military Hospital Meknes, Morocco

Abstract

Case Report

Boerhaave syndrome is a rare emergency spontaneous rupture of the esophagus as a consequence of barotrauma. Its incidence is estimated at 1.3/1,000,000 per year in the United States, and the diagnosis should be made in the presence of chest pain preceded by intense vomiting, and confirmed by imaging. Our clinical cases have just shown that symptomatology depends on the extent of the lesions, with a normal clinical examination in the first case and subcutaneous emphysema in the second. A CT scan remains the gold standard for confirming the diagnosis.

Keywords: Boerhaave, vomiting, pneumomediastinum.

Copyright © 2024 The Author(s): This is an open-access article distributed under the terms of the Creative Commons Attribution 4.0 International License (CC BY-NC 4.0) which permits unrestricted use, distribution, and reproduction in any medium for non-commercial use provided the original author and source are credited.

INTRODUCTION

Spontaneous oesophageal rupture (SOR), or Boerhaave syndrome, is a barotrauma due to a sudden increase in intra-oesophageal pressure (up to 200 mmHg), caused by intraluminal hyperpressure with the glottis closed [1].

First described by Hermann Boerhaave in 1724.

The term "spontaneous" is used to differentiate Boerhaave's syndrome from oesophageal ruptures caused by iatrogenic, traumatic or tumour perforation. Rupture of the oesophagus is associated with mediastinitis, which can lead to rapid death if left untreated.

Vomiting most often occurs after a heavy meal and/or heavy alcohol consumption. Other causes include epileptic seizures, coughing, asthma attacks and prolonged labour during delivery [2].

There are few epidemiological data on oesophageal perforation. A nationwide study in Iceland found an annual incidence of 3.1 cases per million people [3].

We present the observations of two patients admitted to emergency with Boerhaave syndrome.

OBSERVATIONS

CASE 1

The patient was 34 years old and an active smoker with 12 pack-years of alcohol consumption estimated at 15g per day, with no other medical or surgical history, particularly respiratory.

The patient presented 3 days prior to admission with excessive postprandial morning vomiting complicated by intense chest pain with posterior radiation.

All of this was accompanied by a fever of 38°C.

The clinical examination revealed no other signs. The electrocardiogram showed no abnormalities. The biological work-up requested in the emergency department showed hyperleukocytosis at 20,000/ml with a predominance of neutrophils and a frank inflammatory syndrome: CRP at 300 mg/l and acute functional renal failure with creatinine at 20 mg/dl, troponin measurement was negative.

The patient underwent a frontal chest X-ray showing Isolated pneumomediastinum. (figure 1)

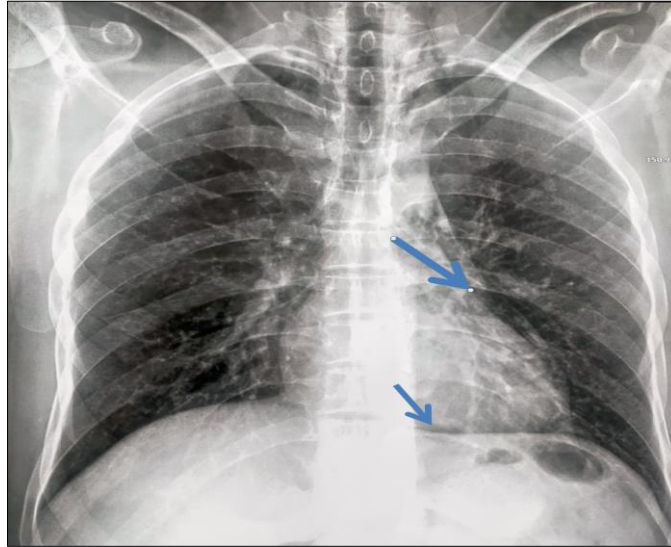


Figure 1: Frontal chest X-ray showing Isolated pneumomediastinum

An additional CT scan confirmed the pneumomediastinum with the presence of radiological signs in favour of Boerhaave syndrome (figure 2)

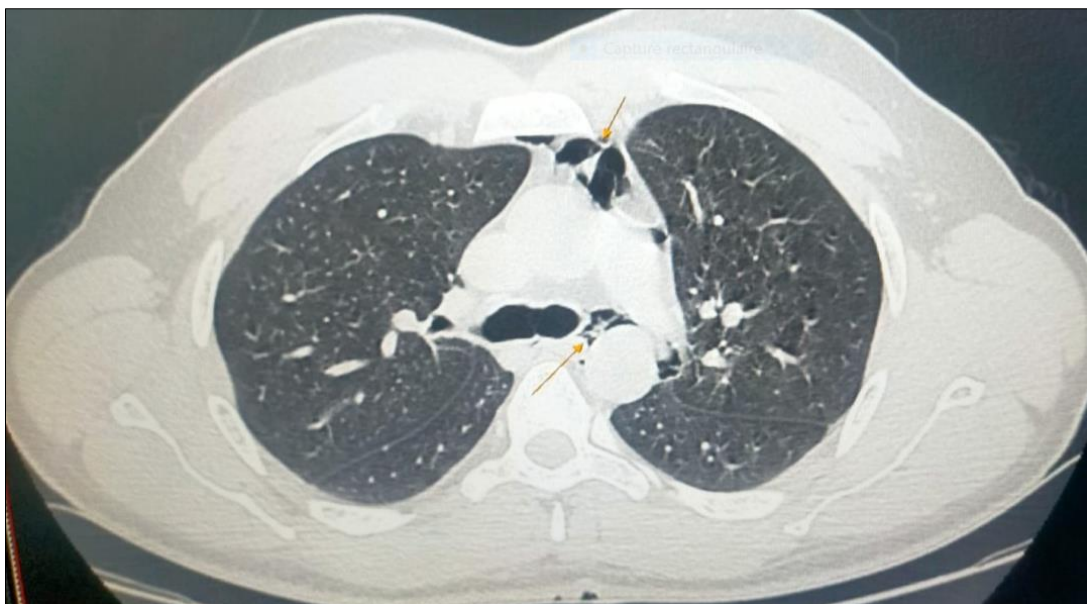

Figure 2: CT scan confirmed the pneumomediastinum with the presence of radiological signs in favour of Boerhaave syndrome.

The patient was put in condition with the prescription of analgesics in addition to a broad-spectrum probabilistic antibiotic therapy.

After conditioning and correction of the defects, the patient underwent surgical cure of the oesophageal perforation with mediastinal drainage.

The outcome was favourable after a 48-hour stay in the ICU.

CASE 2

The patient was 18 years old and had no previous medical or surgical history. She was admitted to emergency with incoercible vomiting and transfixing chest pain extending to the cervical region.

Examination revealed a dehydrated patient with cervical emphysema. Biological tests revealed an inflammatory syndrome with a CRP of 240 and functional renal failure with creatinine of 22 mg/dl. A cervico-thoracic CT scan revealed a pneumomediastinum with cervical subcutaneous emphysema in favour of Boerhaave syndrome (figure 3)

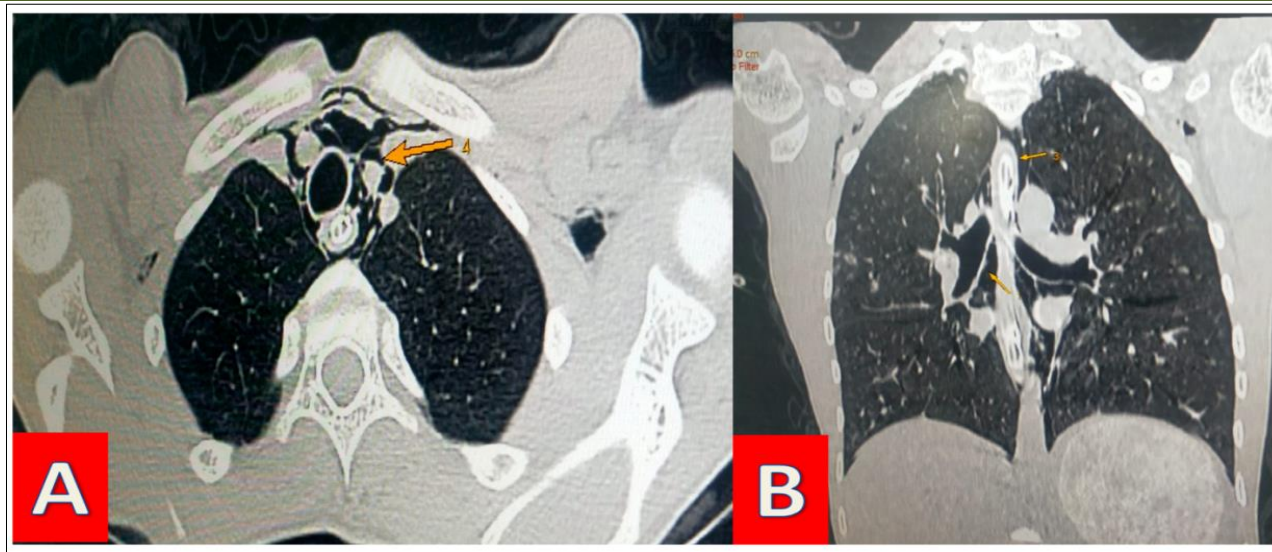


Figure 3: CT scan confirmed the pneumomediastium with the presence of radiological signs in favour of Boerhaave syndrome.

- A. Axial section
B. Coronal section

The post-operative course was good.

DISCUSSION

Boerhaave syndrome is a rare and probably under-diagnosed condition, with an estimated incidence of 1.3/1,000,000 per year in the United States [4]. Depending on the series, it accounts for between 8% and 56% of all causes of oesophageal perforation [5], it predominantly affects men (80% of cases), with a sex ratio ranging from 2:1 to 5:1 [6], and the preferred age range is between 40 and 60.² The risk factors are chronic alcoholism and an underlying oesophageal pathology. Our patient is 34 years old, younger than the age range described in the literature, with a history of chronic alcoholism, which is in line with what is cited above in the literature [7].

The clinical presentation depends on the size and location of the oesophageal breach [9]. The pain is generally constant, usually located in the retro-sternal thorax, radiating to the back and left shoulder blade, or in the abdominal epigastric region [10]. A history of violent or recurrent vomiting preceding the onset of pain should guide the clinician [8]. The first case report describes a patient referred to emergency with severe chest pain preceded by violent vomiting.

Diagnosis is based primarily on imaging. A standard chest X-ray [11], may reveal indirect and aspecific signs of oesophageal perforation, such as pneumomediastinum [12].

However, the reference radiological examination is the thoracic or thoracoabdominal CT scan, with a sensitivity of 92% to 100% [13].

Surgery remains the reference treatment, which consists of repairing the oesophagus by direct suture of the wound after debridement of the necrotic areas [5].

CONCLUSION

Boerhaave syndrome is a rare pathological entity which should be considered in the presence of chest pain preceded by intense vomiting. Diagnosis is based on imaging and management is multidisciplinary with recourse to emergency surgery.

REFERENCES

1. Simonnet, B., Salaun, B., Thicoïpé, M., Jeannin, L., & Chanseau, P. (2009). Rupture spontanée de l'œsophage. *Journal européen des urgences*, 22(1), 10-13.
2. Dayen, C., Mishellany, H., Hellmuth, D., Mayeux, I., Aubry, P., & Glerant, J. C. (2001). La rupture spontanée de l'œsophage ou syndrome de Boerhaave: A propos de trois cas et revue de la littérature. *Revue des maladies respiratoires*, 18(5), 537-540.
3. Vidarsdottir, H., Blondal, S., & Alfredsson, H. (2010). Perforations œsophagiennes en Islande : étude de l'incidence, de l'étiologie et des résultats chirurgicaux sur l'ensemble de la population. *Thorac Cardiovasc Surg*, 58, 476–80.
4. Turner, A., & Turner, S. Boerhaave Syndrome. StatPearls [Internet]. Treasure Island (FL): StatPearls Publishing; 2017 Jun-2017 Apr 19.
5. Chirica, M., Champault, A., Dray, X., Sulpice, L., Munoz-Bongrand, N., & Sarfati, E. (2010). Esophageal perforations. *J Visc Surg*, 147, e117-28.

6. Zwischenberger, J. B., Savage, C., & Bidani, A. (2001). Surgical aspects of esophageal disease. *Am J Respir Crit Care Med*, 164, 1037-40.
7. Colsy, M., Argote, C., Guilhem-Ducléon, H., & Chourbagi, M. (2007). Mediastinitis and septic shock emphasizing a Boerhaave syndrome in a 73-year-old woman. *Journal Européen des Urgences*, 20, 140-2.
8. Trueman, D. (2004). A case study. *Air Medical Journal*, 23, 30-2.
9. Vial, C., & Whyte, R. (2005). Boerhaave's Syndrome: Diagnosis and treatment. *Surg Clin N Am*, 85, 515-24.
10. Khaqan, J. J. (1997). Boerhaave's syndrome. *Postgrad Med Jf*, 73, 265-70.
11. Curci, J. J., & Horman, M. J. (1976). Boerhaave's syndrome: The importance of early diagnosis and treatment. *Ann Surg*, 183, 401-8.
12. Vogel, S. B., Rout, W. R., Martin, T. D., & Abbitt, P. L. (2005). Esophageal perforation in adults: aggressive, conservative treatment lowers morbidity and mortality. *Annals of surgery*, 241(6), 1016-1023.
13. di Castelguidone, E. D. L., Merola, S., Pinto, A., Raissaki, M., Gagliardi, N., & Romano, L. (2006). Esophageal injuries: spectrum of multidetector row CT findings. *European journal of radiology*, 59(3), 344-348.