

# Acute Mesenteric Portal Venous Thrombosis Revealed a Strangulated Hernia: A Case Report

Aksim Hanane<sup>1\*</sup>, Oualid Hadadia<sup>1</sup>, Lasfar Intissar<sup>1</sup>, Belhamdi Meryem<sup>1</sup>, Akka Rachid<sup>1</sup><sup>1</sup>Department of Gastroenterology Avicenne Military Hospital, Marrakech, MoroccoDOI: <https://doi.org/10.36347/sjams.2024.v12i09.004>

| Received: 03.08.2024 | Accepted: 10.09.2024 | Published: 13.09.2024

\*Corresponding author: Aksim Hanane

Department of Gastroenterology Avicenne Military Hospital, Marrakech, Morocco

**Abstract****Case Report**

Mesenteric ischemia is a frequent pathology with a variety of etiologies, the consequences of which can range from simple transient alteration of intestinal activity to transmural necrosis. Venous thrombosis is rarer (5% of cases of mesenteric ischemia), is sometimes not very symptomatic but can also be lethal, the clinical presentation is non-specific, hence the role of multimodal imaging in confirming the diagnosis. We present a rare case of mesenteric venous ischemia revealed a strangulated hernia in a 55-year-old man.

**Keywords:** mesenteric vein thrombosis, ischemia, strangulated hernia, anticoagulation.

Copyright © 2024 The Author(s): This is an open-access article distributed under the terms of the Creative Commons Attribution 4.0 International License (CC BY-NC 4.0) which permits unrestricted use, distribution, and reproduction in any medium for non-commercial use provided the original author and source are credited.

## INTRODUCTION

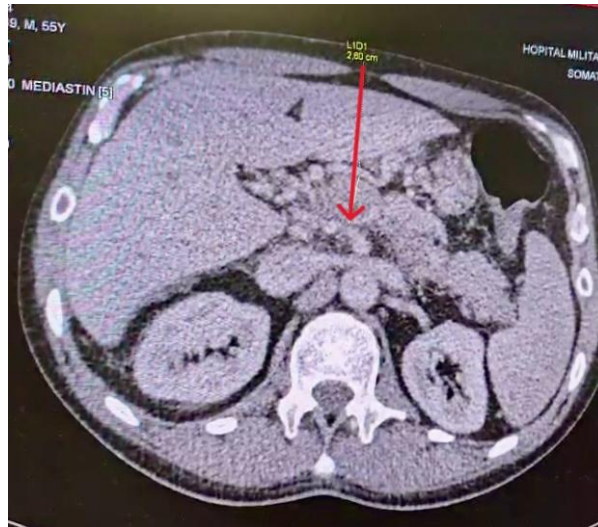
Acute mesenteric portal ischemia is caused by interruption of blood supply to the small intestine, which may be secondary to mesenteric arterial embolism (50%), mesenteric arterial thrombosis (15-25%) or mesenteric venous thrombosis (5-15%) [1]. It is a life-threatening emergency, with a high mortality rate of 50-70% [1]. Early diagnosis and intervention are necessary to reduce mortality [1]. We report a case of mesenteric portal thrombosis responsible for acute mesenteric ischemia in a 55-year-old man revealed a strangulated hernia.

## CASE REPORT

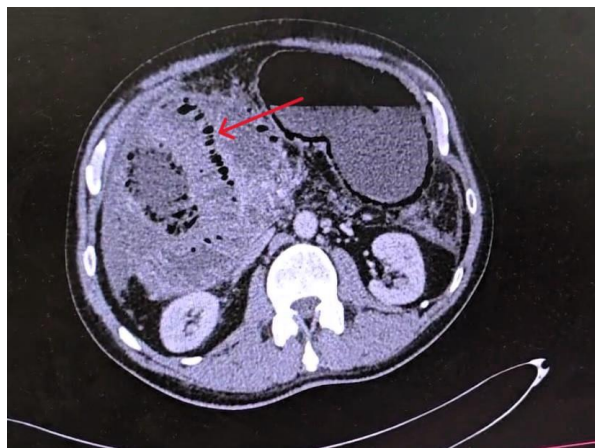
We report the case of a 55-year-old adult male admitted to the emergency department for sudden-onset diffuse abdominal pain with vomiting. The patient's pathological history included epilepsy on sodium valproate 500 mg, hypertension on Converting Enzyme Inhibitor (CEI) 5 mg, dyslipidemia on Rosuvastatin 10 mg, and no known drug allergy or herbal medication. The clinical history dated back to a week earlier, with the onset of abdominal pain initially localized to the epigastrium and rapidly generalized to the entire abdomen, unrelieved by usual treatment, associated with vomiting and no evidence of digestive bleeding, all evolving in an apyretic context and preserved general condition. On clinical examination, the patient was conscious (GSC 15/15), normocardiac (HR 80 beats/min), normotensive, slightly tachypneic

(respiratory rate 22 breaths/min) and apyretic (36°). Diffuse abdominal tenderness was present, with silence on abdominal auscultation and no other pathological signs. Biological workup revealed hyperleukocytosis at 18,000 /mm<sup>3</sup>, C-reactive protein (CRP) at 203 mg/L, no hydroelectrolytic disorders, and the rest of the workup was normal. Abdominal ultrasonography revealed diffuse digestive thickening of the small intestine, associated with a small intraperitoneal effusion, with impermeability of the portal trunk on color Doppler. We completed the work-up with an abdomino-pelvic CT scan before and after injection of contrast medium (PDC). It showed mesenteric portal thrombosis with signs of congestion and segmental gellic edema with no obvious underlying cause, and no pneumatosis or pneumoperitoneum (Figure A). The patient was put on anticoagulant treatment but with no clinical improvement and a worsening of his general condition, hence the indication for a follow-up abdominal CT scan, which revealed significant distension of the stomach and oesophagus, with dilatation of the small intestines measuring 7cm in maximum diameter with no hydroaeric level, aeroportosis and parietal pneumatosis of the intestinal intestines, enlarged appearance and non-opacified hypodermis of the portal trunk, associated with millimetric serpiginous vascular structures related to portal cavern (figure B). The diagnosis of entero-mesenteric infarction due to venous thrombosis was accepted, and the patient underwent resection of the necrotic jejunal intestines, revealing an epiploic breach responsible for a strangulated internal hernia at the time of surgical exploration (figure C). The evolution was

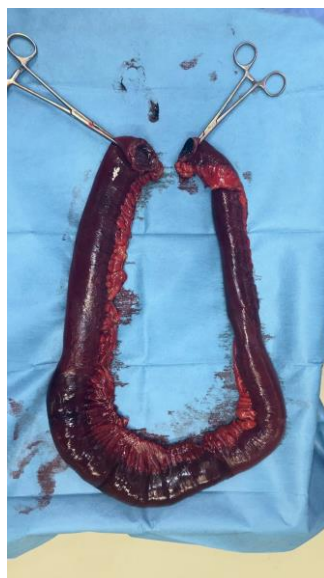marked by a worsening of the patient's condition and death.



**Figure A:** Abdominal computed tomography (CT) in axial section with injection of PDC at venous time, showing venous thrombosis of the portal trunk (red arrow)



**Figure B:** Abdominal axial computed tomography (CT) scan showing parietal pneumatosis (red arrow)



**Figure C:** Photo shows necrotic intestinal handles

## DISCUSSION

Mesenteric portal venous thrombosis is a rare condition that can have morbid and sometimes fatal consequences. Conventional approaches have involved resection and stoma placement and/or anticoagulation. The disadvantage is that conventional approaches do not treat the underlying thrombus. This can sometimes lead to a downward spiral of worsening ischemia, culminating in further resections resulting in loss of bowel length and subsequent short bowel syndrome [2].

The superior mesenteric vein (SMV) drains the intestine from the duodenum to the right two-thirds of the transverse colon, and ends by joining the splenic vein to form the portal vein [3]. Thrombosis of the portal vein reduces blood drainage from this large part of the intestine, and can therefore lead to ischemic necrosis. thrombosis of the superior mesenteric vein (TSMV) can be either primary, i.e. without a predisposing cause, or secondary, i.e. due to known causes such as thrombophilia, prothrombotic and primary hypercoagulable states (heparin-induced thrombocytopenia, essential thrombocythemia, post-splenectomy thrombocytosis, and neoplastic disorders) [4]. Singal *et al.*, reported that gain-of-function mutation in JAK2V617F is also associated with MVT [3].

Although the incidence of TSMV is low, the mortality rate is high, at 19-23% [4]. Hence the importance of early diagnosis of thrombosis to avoid irreversible vessel damage. CT scans are used for this purpose, identifying 90% of such cases. Blood tests are not generally useful in cases of DVT, but some sources report an increase in D-lactate, lactate dehydrogenase and L-lactate [4]. Abdominal Doppler ultrasonography is useful in cases of large-vessel obstruction. The incidence of mesenteric vein thrombosis (MVT) is high in men aged between 40 and 60 [3].

Patients with acute and subacute MVT may present with abdominal symptoms such as severe mid-abdominal pain, nausea, gastrointestinal bleeding, constipation and fever due to phlebitis [3]. Abdominal distension and ascites may also be present. In severe cases, rebound tenderness and rigidity may be reported due to peritoneal involvement [3]. Patients with chronic MVT are usually asymptomatic due to the development of collateral circulation and are diagnosed incidentally. The extent of ischemia and necrosis depends on where the obstruction occurs. Most damage occurs when the terminal vessels are occluded. The development of ischemia and subsequent necrosis in MVT is gradual compared to that of mesenteric arterial thrombosis. Spasm of the mesenteric arteries due to venous occlusion may occur, which will result in no improvement in intestinal blood flow even after removal of the venous obstruction [3].

Patients with acute MVT are initially treated with analgesics, blood transfusions and antibiotics [3]. Anticoagulants are then the preferred choice of management. Initially, unfractionated or low-molecular-weight heparin (LMWH) is administered, and the International Normalized Ratio (INR) is reduced to 2-3. A retrospective study of 20 MVT patients by Hollingshead *et al.*, showed that the thrombolytic approach resolved the clot in 75% of patients, that 60% of patients reported complications, the most common of which was bleeding, and that one patient died [5].

Zhang *et al.*, reported in a retrospective study that the group of MVT patients who received anticoagulant therapy had a shorter hospital stay, a reduced mortality rate, less need for surgical intervention and less risk of developing short bowel syndrome compared to the group of patients who did not receive anticoagulant therapy [6]. Patients with peritoneal signs benefit from surgical management. Resection and anastomosis are performed to preserve as much of the bowel as possible [3]. Approximately 2 to 3 days after the first resection, another operation can be performed to determine the need for further resection. Another study reported that 80% of patients with splanchnic vein thrombosis (SVT) were treated with anticoagulants, of which LMWH therapy and vitamin K antagonists accounted for 31.9% and 25.4% of cases, respectively. Direct oral anticoagulants (DOACs) were used in only 1.7% of cases [7].

## CONCLUSION

Mesenteric ischemia is relatively rare and carries a high mortality risk. Consequently, early diagnosis and prompt treatment are necessary to reduce morbidity and mortality. Our patient had a rare case of mesenteric venous ischemia and infarction complicated by a strangulated hernia. Clinical manifestations are not specific to this pathology, which is why medical imaging is of vital importance in diagnosis and therapy. Most cases are managed surgically. The prognosis depends on the origin of the ischemia, its extent and how early it is treated.

## REFERENCES

1. Bala, M., Kashuk, J., Moore, E. E., Kluger, Y., Biffl, W., Gomes, C. A., ... & Catena, F. (2017). Acute mesenteric ischemia: guidelines of the World Society of Emergency Surgery. *World Journal of Emergency Surgery*, 12, 1-11. doi: 10.1186/s13017-017-0150-5.
2. Clair, D. G., & Beach, J. M. (2016). Mesenteric ischemia. *New England Journal of Medicine*, 374(10), 959-968. doi: 10.1056/NEJMra1503884.
3. Singal, A. K., Kamath, P. S., & Tefferi, A. (2013, March). Mesenteric venous thrombosis. In *Mayo Clinic Proceedings* (Vol. 88, No. 3, pp. 285-294). Elsevier. doi: 10.1016/j.mayocp.2013.01.012.

4. Sulger, E., Dhaliwal, H. S. ... & Oropallo, A. (2024). Gonzalez, « Mesenteric Venous Thrombosis », in *StatPearls*, Treasure Island (FL): StatPearls Publishing. Consulté le. [En ligne]. Disponible sur: <http://www.ncbi.nlm.nih.gov/books/NBK459184/>
5. Hollingshead, M., Burke, C. T., Mauro, M. A., Weeks, S. M., Dixon, R. G., & Jaques, P. F. (2005). Transcatheter thrombolytic therapy for acute mesenteric and portal vein thrombosis. *Journal of vascular and interventional radiology*, 16(5), 651-661. doi: 10.1097/01.RVI.0000156265.79960.86.
6. Zhang, J., Duan, Z. Q., Song, Q. B., Luo, Y. W., Xin, S. J., & Zhang, Q. (2004). Acute mesenteric venous thrombosis: a better outcome achieved through improved imaging techniques and a changed policy of clinical management. *European journal of vascular and endovascular surgery*, 28(3), 329-334. doi: 10.1016/j.ejvs.2004.06.001.
7. Candeloro, M., Valeriani, E., Monreal, M., Ageno, W., Riva, N., Lopez-Reyes, R., ... & Di Nisio, M. (2022). Anticoagulant therapy for splanchnic vein thrombosis: an individual patient data meta-analysis. *Blood advances*, 6(15), 4516-4523. doi: 10.1182/bloodadvances.2022007961.