

Imaging of Tongue Carcinoma: About 20 Cases

A. Zidani^{1*}, K. Aalloula¹, Y. Bouktib¹, M. Ouali Idrissi¹

¹Radiology Department, Arrazi Hospital, Mohammed VI university Hospital, Cadi Ayyad University, Marrakech, Morocco

DOI: <https://doi.org/10.36347/sjams.2024.v12i11.001>

Received: 23.09.2024 | Accepted: 29.10.2024 | Published: 02.11.2024

*Corresponding author: A. Zidani

Radiology Department, Arrazi Hospital, Mohammed VI university Hospital, Cadi Ayyad University, Marrakech, Morocco

Abstract

Original Research Article

The tongue enables taste and plays a critical role in formation of food bolus and deglutition. The tongue is also crucial for speech and the earliest sign of tongue paresis is a change in the quality of speech. Given the importance of the tongue, tongue carcinoma should be accurately staged in order to optimise treatment options and preserve organ function. The intent of this review is to familiarise radiologists with the pertinent anatomy of the tongue and the behaviour of tongue carcinoma so as to map malignant infiltration accurately.

Keywords: TNM staging, tongue carcinoma, computed tomography, magnetic resonance imaging.

Copyright © 2024 The Author(s): This is an open-access article distributed under the terms of the Creative Commons Attribution 4.0 International License (CC BY-NC 4.0) which permits unrestricted use, distribution, and reproduction in any medium for non-commercial use provided the original author and source are credited.

INTRODUCTION

- Tongue: centrepiece of oral cavity and the oropharynx.
- Malignant tumors of the tongue are common.
- Epidermoide carcinoma: 95%.
- MRI:
 - Positive diagnosis
 - Regional locoextension.
- Prognosis: TNM

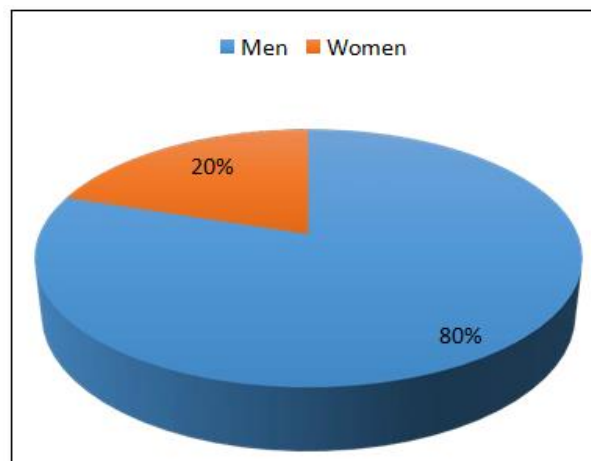
The aim of this study:

- Illustrate the role of imaging in the positive diagnosis of tongue tumors
- Regional loco extension assessment.
- Show the essential elements to be mentioned on

the report of imaging that may have a surgical impact.

MATERIELS AND MATHODS

- Retrospective study of 20 cases of tumor of the tongue
- Locality: Radiology department of AR-RAZI hospital of Mohamed VI CHU of Marrakech
- Period: 3 years, from February 2015 to February 2018.
- Average age: 42 years.
- Male prédominance, 16 men/4women
- 12 patients were smokers and 4 of them were alcoholics.
- Dental prothesis: 7 patients



Clinical Signs:

- Budding and ulcerous lesions of the tongue + bleeding
- MRI was tested on all our patients.
- MRI technique:
 - Antenna: head and neck.
 - MRI imaging protocol:
 - Séquences T1 in axial, coronal and sagittal planes.
 - Séquences T2 in axial plan.
 - Séquences diffusion in axial plan.
 - Fatsat images in coronal and sagittal planes.
 - Séquences T1 with contrast (gadolinium).

RESULTS

Localisation:

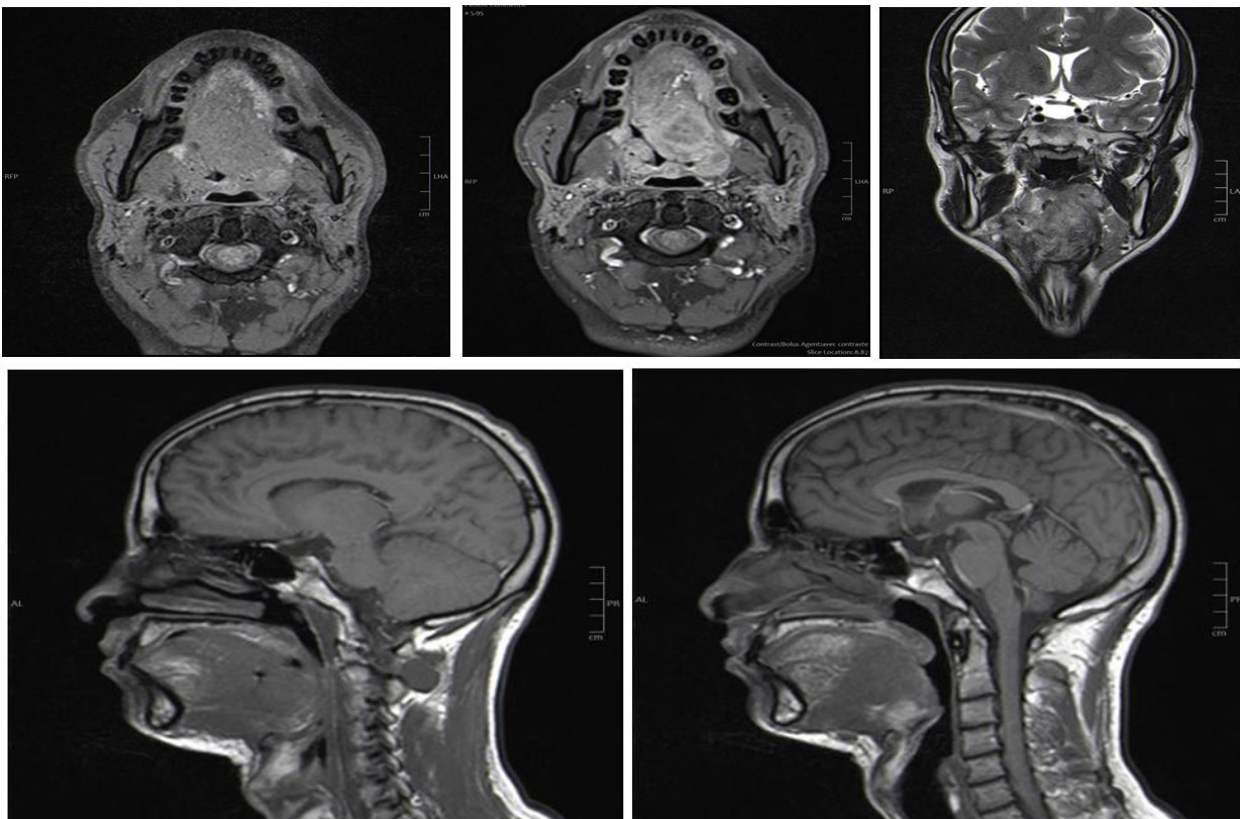
Oral tongue + base	14 patients
Oral tongue	4 patients
Base	2 patients

Extension:

Hard palate	6 patients
Oral floor	10 patients
Tensils	8 patients
Maxillary region	3 patients

Cervical lymphadenopathies	18 patients
Sub-mental	15 patients
Sub-mandibular	9 patients
Jugulo-carotid	12 patients

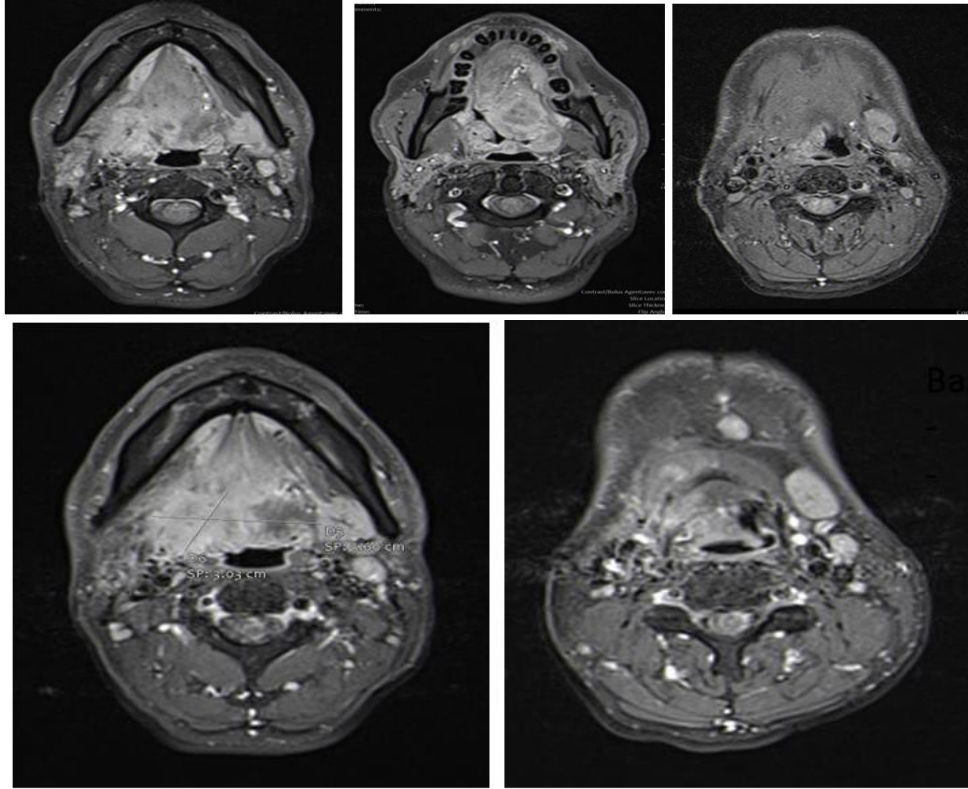
Histology: Squamous cell carcinoma in all patients.



Base tongue carcinoma invasion of:

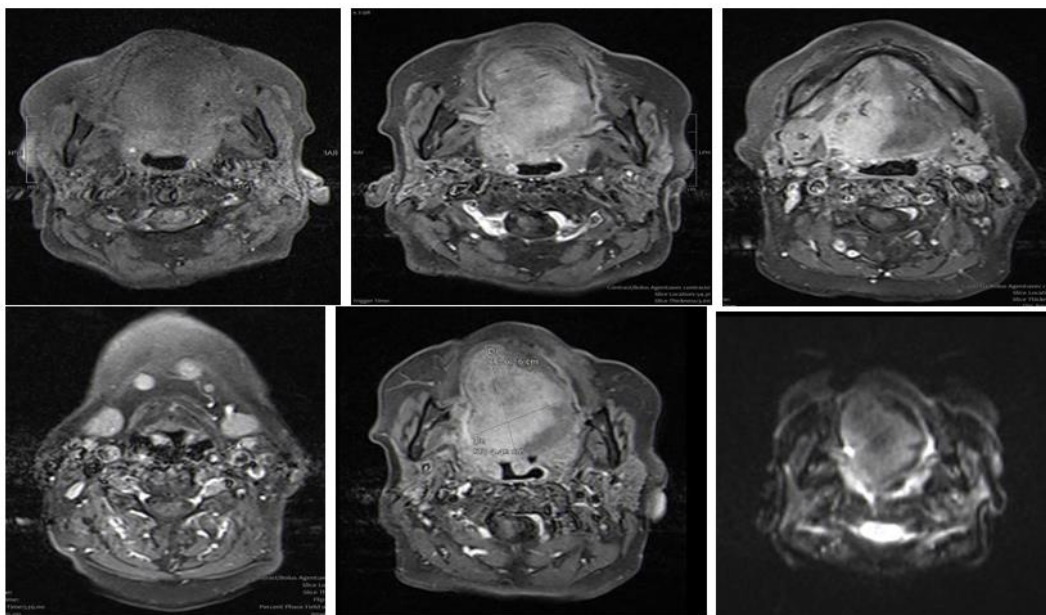
- Medial line
- Left amygdalian area.
- Left parapharyngeal space

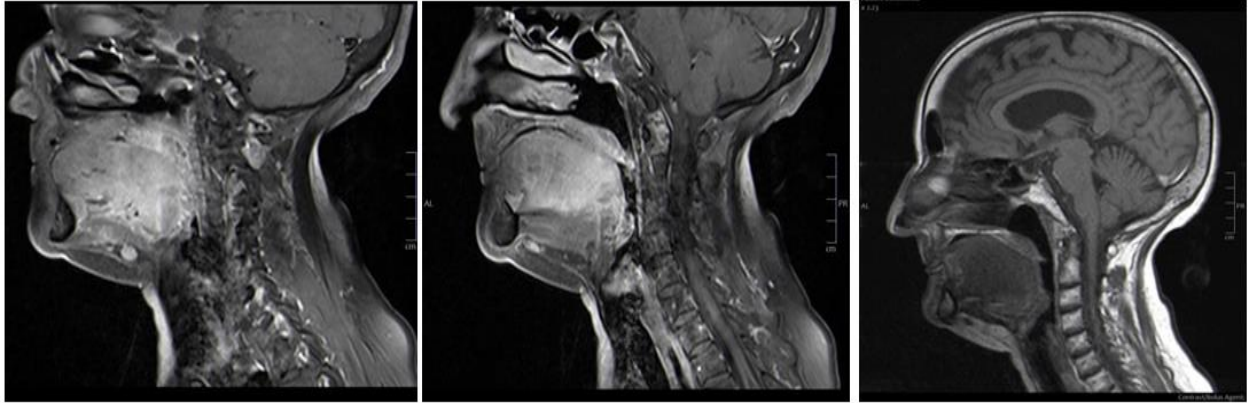
It is responsible for a filling fills the orophar reducing its cavity.



Base tongue carcinoma:

- Invasion of left para-pharyngeal space
- Left mandibular lymphadenopathy

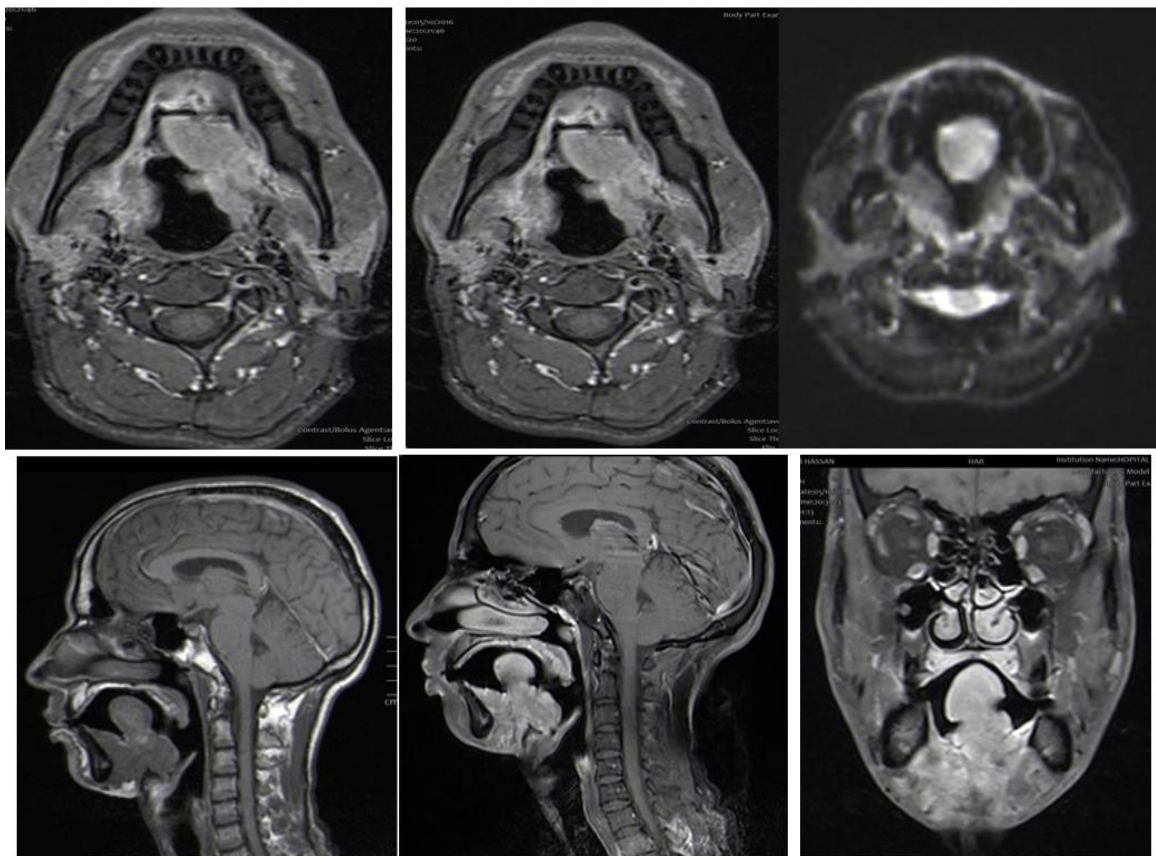




Right oral tongue carcinoma Invasion of:

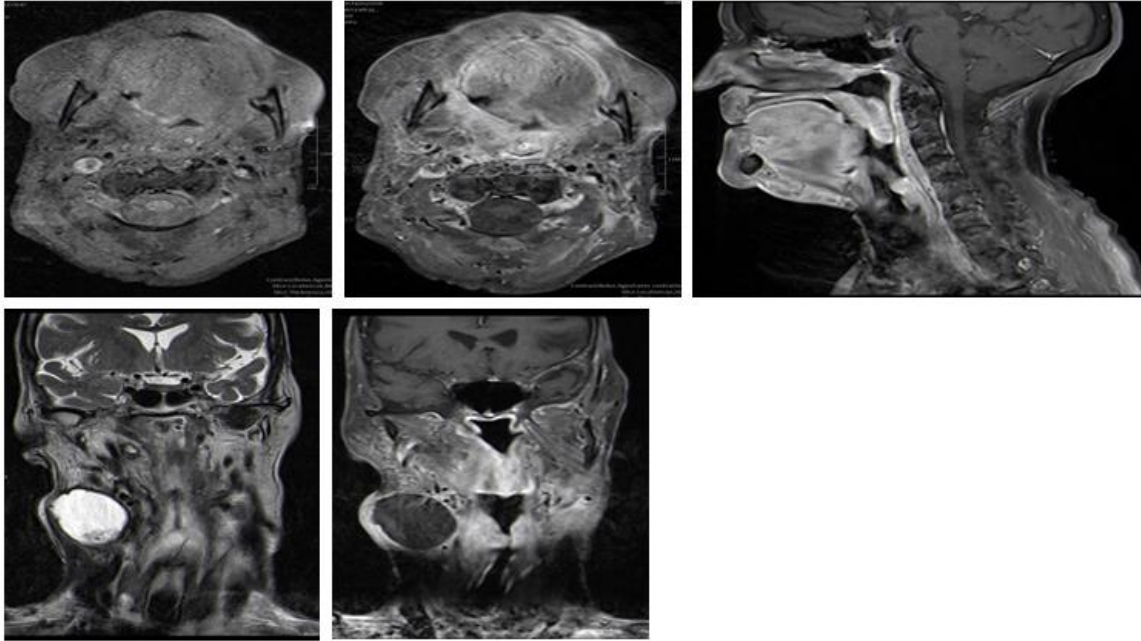
- Base and buccal floor (m genio+hypoglossus)
- pterygo mandibular raphe.
- Pre and retrostyliens spaces.
- Right tensile (tumef)

In contact with JC vessels Mandibular body Submental lymphadenopathy



Budding tongue carcinoma in lingual lodge with base infiltration: recidive Invasion of:

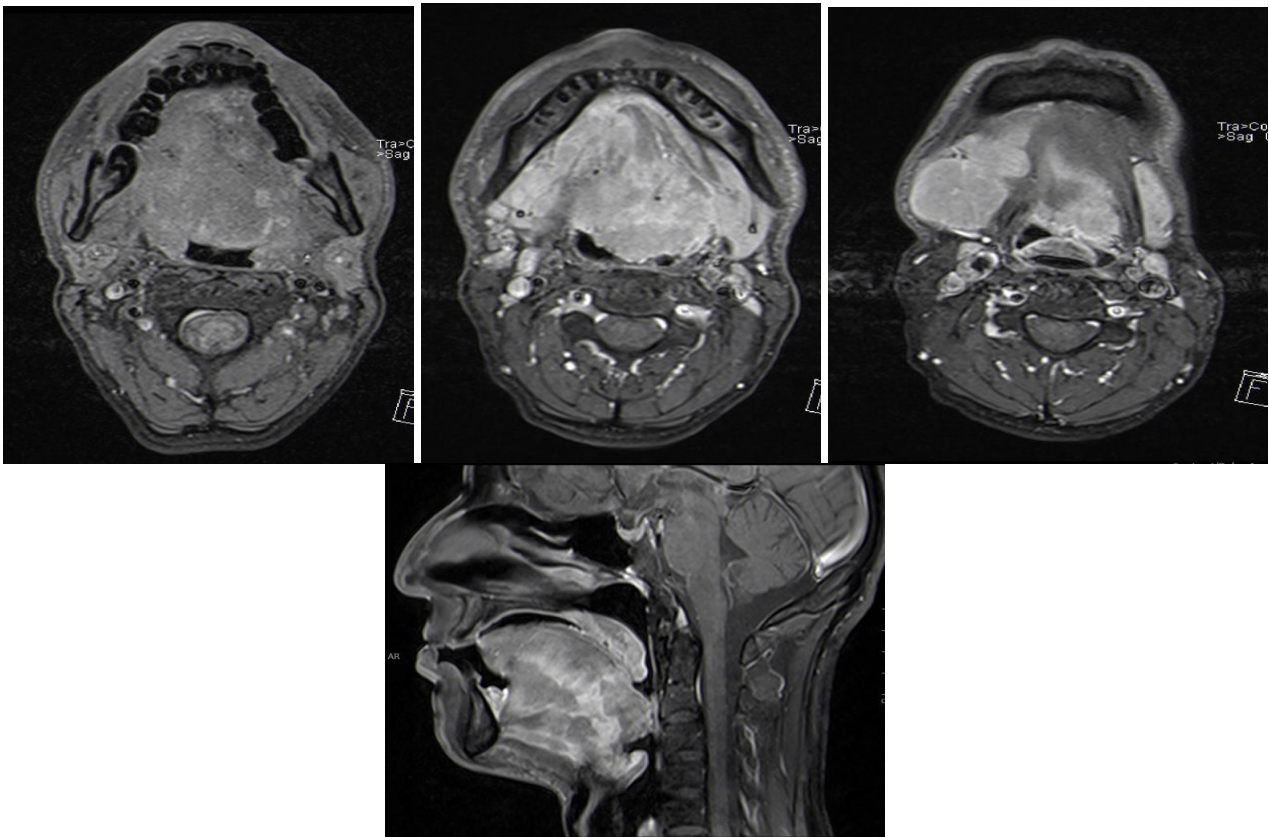
- Left tensile.
- Left parapharyngeal space
- Left mandibular body

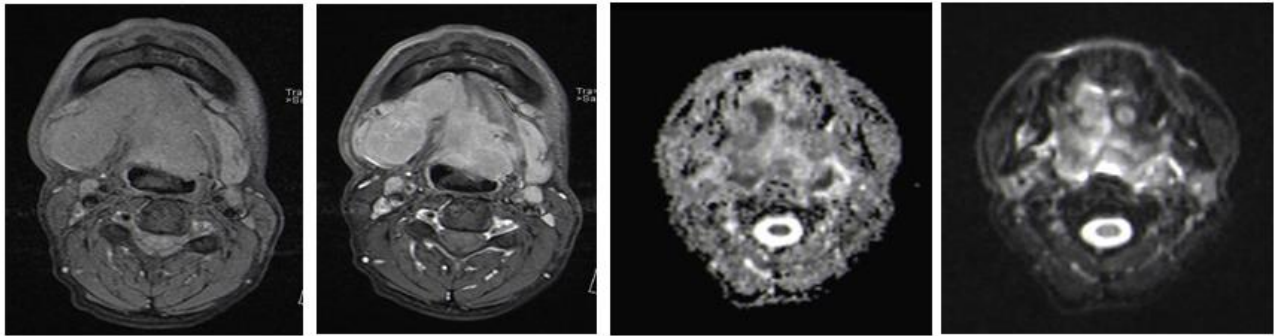


Right oral tongue carcinoma: Invasion of:

- Medial line
- Base and oral floor
- Right tensile area
- Para pharyngeal space.

Necrotic right jugulocarotidien adenopathy





Base and oral tongue carcinoma Invasion of:

- Medial line
- Uvula and left amygdalien lodge.
- Soft palate
- Epiglottis
- Right maxillar gland (tumf) Fille
- the left vallecule
- Oropharyngeal cavity

- Later: ulcerous and budding tumor

Imaging:

- MRI:
 - The most performant imaging technique.
 - Must be done before any biopsy and any extraction tooth
 - Antenna: Head and neck
 - From the base of skull at the base of the neck
 - Loco regional extension assesement
 - Lymph invasion

DISCUSSION

- Tongue carcinoma:
 - 95%: squamous cell carcinoma.
 - 5%: Lymphoma, cylindroma et mélanoma.
- Earlier sign: lingual paresis

- CT scan: reserved to
 - Patients with MRI contraindication.
 - Mandibular extension.

Imaging:

Signal	Normal musclar	Mucose and submucosa	Lymphatic formations	Salivary glands	Tumor
T1	hyposignal	hypersignal+++	Hypersignal++	Hypersignal+	Hyposignal+
T2	hyposignal	Iso/moderate hypersignal	isosignal	iso/ moderate hypersignal	hypersignal
T1+C	Hypo/low enhancement	Hypersignal+++	Hypersignal++	Hypersignal++	Hypersignal++

Modifié d'après C. Aleaddinne *et al.*, JFR 2004, FMC N29

TNM

Primary tumor (T)

- Tx Primary tumor cannot be assessed
- T0 No evidence of primary tumor
- Tis Carcinoma in situ
- T1 Tumor ≤ 2 cm in greatest dimension
- T2 Tumor > 2 cm but ≤ 4 cm in greatest dimension
- T3 Tumor > 4 cm in greatest dimension
- T4 (lip) Tumor invades through cortical bone, inferior alveolar nerve, floor of mouth, or skin of face, ie, chin or nose^a
 - T4a (oral cavity) Tumor invades adjacent structures (eg, through cortical bone, into deep [extrinsic] muscle of the tongue, maxillary sinus, or skin of face); resectable lesions
 - T4b Tumor involves masticator space, pterygoid plates, or skull base and/or encases internal carotid artery; unresectable lesions

Regional lymph nodes (N)

Nx	Regional nodes cannot be assessed
N0	No regional lymph node metastasis
N1	Metastasis in a single ipsilateral lymph node, ≤ 3 cm in greatest dimension
N2	Metastasis in a single ipsilateral lymph node, > 3 cm ≤ 6 cm in greatest dimension; or in multiple ipsilateral lymph nodes, none > 6 cm in greatest dimension; or in bilateral or contralateral lymph nodes, none > 6 cm in greatest dimension
N2a	Metastasis in a single ipsilateral lymph node, > 3 cm but ≤ 6 cm in greatest dimension
N2b	Metastasis in multiple ipsilateral lymph nodes, none > 6 cm in greatest dimension
N2c	Metastasis in bilateral or contralateral lymph nodes, none > 6 cm in greatest dimension
N3	Metastasis in a lymph node, > 6 cm in greatest dimension

Distant metastases (M)

Mx	Distant metastasis cannot be assessed
M0	No distant metastasis
M1	Distant metastasis

From Greene FL, Page DL, Fleming ID, et al (eds): AJCC Cancer Staging Manual, 6th ed. New York, Springer-Verlag, 2002.

^a Superficial erosion alone of bone/tooth socket by gingival primary is not sufficient to classify a tumor as T4.

Elements to specify on the imaging report:**Oral tongue carcinoma:**

Localisation of the lésion + mensuration

- Distance with lingual homolatéral pédicule
- Distance to the medial line.
- If it is crossing: distance with controlateral vascular pedicul.
- Achievement of extrinsic tongue muscles
- Invasion of the junctional zone and the langual base.
- Invasion of the pelvilangula groove and oral floor (geniohyoid and mylohyoid muscular)
- Bone involvement:
 - Isolated to cortical bone
 - Lyse and mandibular infiltration.
- Vascular invasion
- Perinervous extension.
- Lymph and ganglionar extension

T and N by imaging**Base tongue carcinoma:**

- Relation with the medial line.
- Extension to the amygdalo-glosse groove.
- Extension to the HTE lodge, epiglottis and vallecules.
- Oral cavity: lingual vascular pédicul.
- Vascular status.

CONCLUSION

- Malignant tumors of the tongue are common.
- Their prognosis is related to initial tumor

staging.

- MRI is the performed modality in the evaluation of the loco-regional extension.

BIBLIOGRAPHY

- Amandeep, S. Role of MRI in Evaluation of Malignant lesions of tongue and oral cavity. Departement of radiodiagnosis and imaging, Sri Guru Ramdas Institute of medical sciences and research; Punjab, India.
- Berrada, S., Moussali, N., Bekkali, L., Elbenna, N., & Gharbi, A. (1953). Apport de l'imagerie dans les cancers de la langue: à propos de 30 cas. Radiologie de l'hôpital 20 Aout 1953, CHU Ibn Rochd, Casablanca.
- Arya, S., Chaukar, D., & Pai, P. (2012). Imaging in oral cancers. *Indian J Radiol Imaging*, 22, 195-200.
- Sobin, L. H., & Wittekind, C. H. (2002). UICC TNM classification of malignant tumors. 6th, Ed. New York: Wiley-Liss, 52-56.
- Hurtenvent-Labrot, G., & Bruge-Grivet, H. Imageie des tumeurs de l'oropharynx et de la cavité orale.
- Marsot-Dupuch, K. (2005). Savoir faire en imagerie ORL et cervico faciale. Tome 1, Sauramps médiacel 2nd, 2005.
- Mukharji, S. K., Pilsbury, H. R., & Castillo, M. (1997). Imaging squamous cell carcinomas of the upper aerodigestive tract: what clinicians need to know. *Radiology*, 205, 629-646.