

Chondroblastoma of Bone in Children: A Study of 3 Cases

Meryem Fettah^{1*}, Mohammed Mimouni¹, Mohamed Tazi Charki¹, Hicham Abdellaoui¹, Karima Atarraf¹, Moulay Abderahmane Afifi¹

¹Department of Pediatric Traumatology-Orthopaedics, CHU Hassan II Fez, Morocco. Faculty of Medicine and Pharmacy, University Sidi Mohamed Ben Abdellah Fez, Morocco

DOI: <https://doi.org/10.36347/sajs.2024.v10i11.002>

| Received: 27.09.2024 | Accepted: 30.10.2024 | Published: 04.11.2024

*Corresponding author: Meryem Fettah

Department of Pediatric Traumatology-Orthopaedics, CHU Hassan II Fez, Morocco. Faculty of Medicine and Pharmacy, University Sidi Mohamed Ben Abdellah Fez, Morocco

Abstract

Case Series

Chondroblastoma is a benign bone tumor arising most often in the epiphyses of long bones. Nearly 90% occurred in patients between the ages of 5 and 25 years, but tumors were found in later adulthood and even in old age. A few chondroblastomas were predominantly cystic, and some contained zones that were indistinguishable microscopically from aneurysmal bone cysts. Conservative surgical removal, nearly always effective, should be thorough so as to minimize the risk of the occasional troublesome recurrence. Late sarcomatous change has been reported in a few cases whether radiation therapy was employed or not. We report a series of 3 boys with chondroblastoma, with an average age of 12 years. All our patients underwent biopsy for confirmation and then surgical treatment consisting of curettage of the lesion followed by bone autograft filling. The aim is to discuss the anatomoclinical and evolutionary aspects of this rare tumour, to evaluate the results of surgical treatment and to identify the factors influencing the rate of recurrence after treatment.

Keywords: Benign Bone Tumour, Chondroblastoma, Cartilage Tumour.

Copyright © 2024 The Author(s): This is an open-access article distributed under the terms of the Creative Commons Attribution 4.0 International License (CC BY-NC 4.0) which permits unrestricted use, distribution, and reproduction in any medium for non-commercial use provided the original author and source are credited.

INTRODUCTION

Chondroblastoma is a rare lesion, representing less than 1% of all primary bone tumours and less than 2.5% of benign bone tumours [1, 2].

This lesion affects boys electively: the sex ratio is two males to one female [1–3], and is typically seen in the second decade of life. The localisation of the lesion is highly suggestive of the diagnosis, as it mainly affects the epiphyses of the long bones. The lesion may be asymptomatic [4, 5], however, when there are clinical manifestations, the symptomatology is dominated by pain (86%) [1]. Rarely, chondroblastoma is discovered on a pathological fracture [6]. The X-ray is evocative and the diagnosis is confirmed after histological proof following biopsy. The aim of our study is to present a series of cases of chondroblastoma and to describe the various anatomoclinical and evolutionary aspects of this tumour.

RESULTS OF THE STUDY

A retrospective study, lasting 7 years, from January 2016 to June 2022, in the paediatric traumatology

orthopaedic department of the CHU Hassan II Fès, based on 3 cases.

The incidence of chondroblastoma represents 6% of all bone tumours, and the mean age of patients was 12.5 years, with extremes of 8 to 15 years.

All patients in our series were male. There were two cases of epiphyseal metaphyseal chondroblastoma of the proximal femur and one case of epiphyseal chondroblastoma of the proximal tibia.

Clinically, painful limping was the main reason for consultation, associated with knee swelling in one case and limited mobility in two cases.

The average consultation time was 9 months, with extremes of 4 months and 15 months.

On radiography, the X-ray showed an epiphyseal metaphyseal osteolytic bone lesion, oval in shape, eccentric, well limited with a continuous sclerotic border. Additional CT scans revealed well-limited osteolysis, roughly oval in shape, with regular contours, measuring between 2 and 5 cm in diameter, with no

periosteal reaction, and cortical rupture in 2 cases. Intra-articular effusion was present in all cases (figure 1 and 2).

Calcifications and invasion of the PM were observed in only one case, with complete lysis of the tibial spines in the proximal tibial localisation.

A bone biopsy was performed in all patients, and the diagnosis of chondroblastoma was retained in all cases. Macroscopically, the tumours showed pearly whitish bone reminiscent of cartilage.

Histologically, the tumours were composed of areas of typical rounded or polygonal chondroblasts, multinucleated osteoclast-like giant cells and immature eosinophilic cartilaginous intercellular matrix with the presence of grid-like pericellular calcifications.

All our patients benefited from surgical curettage combined with autologous bone graft filling.

In one case, progress was good, with no pain or sequelae of stiffness. However, limited articular mobility was noted in the 2 other cases. With an average follow-up of 5 years.

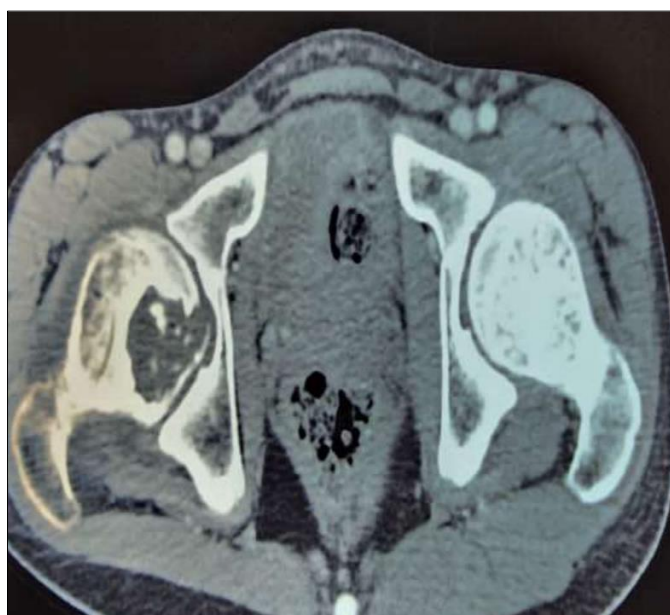

Fig. 1: CT scan of the hip showing an osteolytic lesion of the right femoral head, epiphyseal-metaphyseal, well limited, roughly oval in shape

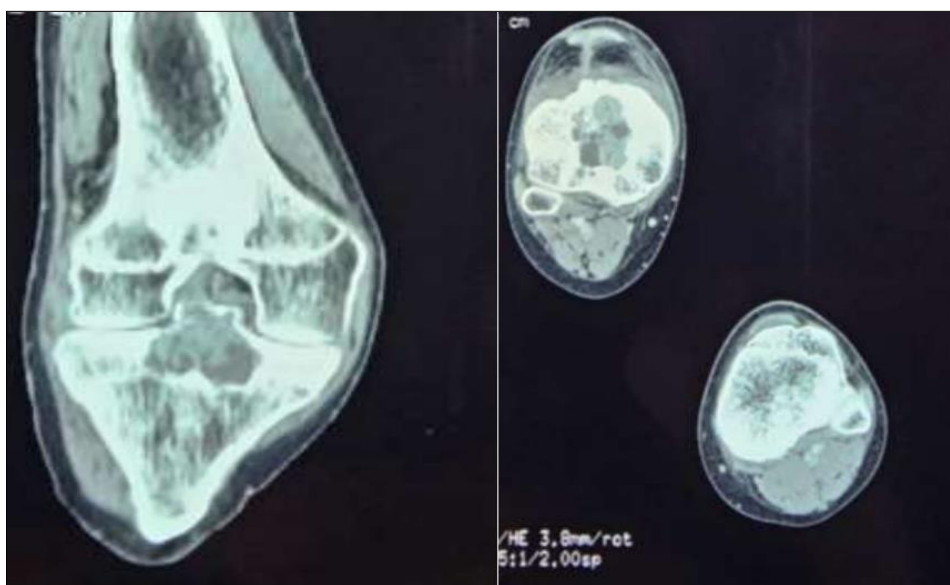


Fig. 2: CT scan of the right knee, coronal and axial sections, showing a well-limited osteolytic epiphyseal lesion of the tibial plate

DISCUSSION

Chondroblastoma is rare, representing only 0.5 to 1% of primary bone tumours and 9% of benign bone tumours [7]. It is more common in males (2 to 3/1) [8].

In our series, the incidence of chondroblastoma was 6%, and all patients were male.

Chondroblastoma typically occurs in the epiphysis, always close to a fertile physal bone. It may then extend to the metaphysis, crossing the growth plate to become epiphyseal-metaphyseal [9]. The most common sites are the proximal humerus (21%), proximal femur (15%), distal femur (16%) and proximal tibia (20%) [10, 11].

In our study, two cases of chondroblastoma were epiphyseal-metaphyseal of the proximal femur, and one was epiphyseal of the proximal tibia.

The revealing signs of chondroblastoma are often discreet and unspecific. Pain is common, sometimes reported during sports trauma. Swelling may be seen in superficial sites such as the shoulder or knee. Lameness may be the only sign of a lower limb injury. The occurrence of a pathological fracture is quite exceptional. More common are symptoms of articular irritation, such as reduced mobility or the appearance of hyarthrosis. The tumour may also be discovered by chance during an X-ray. The clinical examination is normal and no biological abnormalities are found [9].

A radiological study is often sufficient to suggest chondroblastoma [12]. The area of osteolysis is rounded or oval in shape and is well defined by a border of sclerosis, which indicates that it is slow-growing. It is eccentric to the epiphysis, close to a cortical bone or the articulation, and contains small calcified spots in half the cases. The growth plate is often visible and may be penetrated by the lesion.

Chondroblastoma is usually small, between 1 and 6 cm in diameter, but sometimes, especially in cases of recurrence, the tumour may extend further, blowing into the bone and even invading the neighbouring joint. The radiological image may be less typical when the contours are poorly defined, with refractory partitions and a periosteal reaction [13].

Scintigraphy, if requested, would show a very slightly hyperfixating area. Magnetic resonance imaging (MRI) [14], may be useful in assessing the tumour's connection with the growth plate, joint and soft tissues.

The tumour is firm, granular and pinkish or greyish in colour. The microscopic appearance is characterised by the presence of chondroblasts and giant cells, and by the production of chondroid substance. Chondroblastic cells are polygonal, with a clear border and a single round or oval nucleus which occupies half

the cell. The cytoplasm is granular, rich in glycogen and contains normal mitoses.

Treatment is always surgical, combining curettage and filling. According to some authors, it is advisable to carry out additional lavage with phenol or alcohol, thermal cauterisation or cryotherapy, or even filling with acrylic cement [15], which should be avoided in children. It is preferable to use a corticospongiosa autograft.

All our patients underwent surgical curettage combined with filling of the lesion with an autologous bone graft.

Arthroscopic curettage-filling has been suggested for certain sites, such as the femoral condyle. For lesions located on the femoral head, the approach can be performed either by conventional arthrotomy, or through the neck using a trephine and long curettes underoscopic control. Segmental resection is possible in certain locations (rib, posterior vertebral arch, fibula). It is mainly considered in the case of very extensive lesions or in the case of recurrence, but it is then necessary to provide for bone or osteoarticular reconstruction.

Radiotherapy has been proposed for lesions that are difficult to access, but should be avoided. It is formally not recommended in children because of the risk of altering growth zones and the development of radiation-induced sarcoma, especially as the radiosensitivity of chondroblastoma seems uncertain. Good experience in the treatment of bone tumours now enables satisfactory surgical excision of these benign tumours in all locations [9].

The rate of recurrence varies according to the authors: 5.7% for Schajowicz [16], 15% for Meary [17], and up to 38% for Huvos [18]. Recurrence occurs in the bone adjacent to the initial tumour, in the soft tissue and, more rarely, in the articulation. This risk is more likely to be encountered in forms with a significant aneurysmal content. However, it does not appear to be related to the patient's age or the location of the tumour.



The risk of malignant transformation is highly controversial, and concerns certain cases with local degeneration on the one hand [19, 20], and the occurrence of distant pulmonary metastases on the other. It now seems established that these so-called 'malignant' chondroblastomas in fact correspond to an undifferentiated chondrosarcoma or a clear cell chondrosarcoma initially confused with a chondroblastoma. In other cases, it appears to be a sarcomatous transformation following radiotherapy on a benign lesion [21]. The development of pulmonary metastases in chondroblastoma has been reported in several cases. Removal of the pulmonary lesion, which was always histologically benign, led to cure.

In our study, no metastatic lesions were noted.

CONCLUSION

Chondroblastoma is a benign epiphyseal cartilage tumour that occurs mainly in the second decade of life. It is located preferentially on the upper extremity of the humerus, femur and tibia. Radiology is often sufficient to make the diagnosis, which must always be confirmed by biopsy ; wich is essential, as the image may be confused with a giant cell tumour or chondrosarcoma in adults. Treatment is surgical, involving complete curettage followed by filling with bone grafts. There is a possibility of benign local recurrence. Malignant transformation probably corresponds to an initially malignant tumour or to an unrecognised radiation-induced sarcoma in certain difficult forms.

BIBLIOGRAPHIE

- Lucas, D. R. (1996). Dahlin's bone tumors: general aspects and data on 11,087 cases.
- Giudici, M. A., Moser Jr, R. P., & Kransdorf, M. J. (1993). Cartilaginous bone tumors. *Radiologic Clinics of North America*, 31(2), 237-259.
- Resnick, D. L., & Kransdorf, M. J. (2004). Bone and Joint Imaging. *Saunders*, 2790.
- Imagerie des tumeurs osseuses - Jean-Jacques Railhac, Paul Bonneville   achat livre [Internet]. [cité 17 oct 2024]. Disponible sur: <https://www.lireka.com/fr/pp/9782840232155-imagerie-des-tumeurs-osseuses>
- Mirra, J., Picci, P., & Gold, R. (1989). Bone Tumors: Clinical, Radiologic, and Pathologic Correlations. In 1989.
- Maroteaux P, Le Merrer M. Les maladies osseuses de l'enfant [Internet]. 4e éd. Paris: Médecine-Sciences Flammarion; 2002 [cité 17 oct 2024]. 682 p. (Collection Pédiatrie). Disponible sur: <http://catalogue.bnf.fr/ark:/12148/cb38917206j>
- Lucas, D. R. (1996). Dahlin's bone tumors: general aspects and data on 11,087 cases.
- Mirra, J. M., Marcove, R. C., & Gold, R. H. (1980). Bone tumors, diagnosis and treatment [Internet]. Philadelphia: Lippincott; [cité 22 oct 2024]. 629 p. Disponible sur: <https://catalog.hathitrust.org/Record/000019667>
- Filipe, G., Mary, P., & Masson, E. EM-Consulte. Chondroblastome. Disponible sur: <https://www.em-consulte.com/article/8315/references/chondroblastome>
- Corsat, J. P., Tomeno, B., Forest, M., & Vinh, T. S. (1989). Benign chondroblastoma. A review of 30 cases. *Revue de Chirurgie Orthopedique et Reparatrice de L'appareil Moteur*, 75(3), 179-187.
- Springfield, D. S., Capanna, R., Gherlinzoni, F., Picci, P., & Campanacci, M. (1985). Chondroblastoma. A review of seventy cases. *JBJS*, 67(5), 748-755.
- MCLEOD, R. A., & BEABOUT, J. W. (1973). The roentgenographic features of chondroblastoma. *American Journal of Roentgenology*, 118(2), 464-471.
- CORSAT, J. P., Tomeno, B., Forest, M., & Vinh, T. S. (1989). Chondroblastomes bénins: une revue de 30 cas. *Revue de chirurgie orthopédique et réparatrice de l'appareil moteur*, 75(3), 179-187.
- Fobben, E. S., Dalinka, M. K., Schiebler, M. L., Burk, D. L., Fallon, M. D., Schmidt, R. G., & Kressel, H. Y. (1987). The magnetic resonance imaging appearance at 1.5 tesla of cartilaginous tumors involving the epiphysis. *Skeletal radiology*, 16, 647-651.
- Malawer, M. M., & Dunham, W. (1991). Cryosurgery and Acrylic Cementation as Surgical Adjuncts in the Treatment of Aggressive (Benign) Bone Tumors: Analysis of 25 Patients Below the Age of 21. *Clinical Orthopaedics and Related Research (1976-2007)*, 262, 42-57.
- Schajowicz, F., & Gallardo, H. (1970). Epiphysial chondroblastoma of bone: a clinico-pathological study of sixty-nine cases. *The Journal of Bone & Joint Surgery British Volume*, 52(2), 205-226.
- Meary, R., Abelanet, R., Forest, M., Le Charpentier, Y., Tomeno, B., Languépin, A., ... & Lesec, G. (1975). Benign chondroblastomas of bone. Anatomico-clinical and ultrastructural study apropos of 11 cases. *Revue de Chirurgie Orthopedique et Reparatrice de L'appareil Moteur*, 61(8), 717-734.
- Huvos, A. G., & MARCOVE, R. C. (1973). Chondroblastoma of Bone A Critical Review. *Clinical Orthopaedics and Related Research (1976-2007)*, 95, 300.
- Kyriakos, M., Land, V. J., Penning, H. L., & Parker, S. G. (1985). Metastatic chondroblastoma. Report of a fatal case with a review of the literature on atypical, aggressive, and malignant chondroblastoma. *Cancer*, 55(8), 1770-1789.
- Sirsat, M. V., & Doctor, V. M. (1970). Benign chondroblastoma of bone: report of a case of malignant transformation. *The Journal of Bone & Joint Surgery British Volume*, 52(4), 741-745.
- Wirman, J. A., Crissman, J. D., & Aron, B. F. (1979). Metastatic chondroblastoma. Report of an unusual case treated with radiotherapy. *Cancer*, 44(1), 87-93.