

## Adrenocortical Carcinoma about One Case and Literature Review

Ahmed Boukhalifa<sup>1\*</sup>, Sara Ijdda<sup>1</sup>, Sana Rafi<sup>1</sup>, Ghizlane El Mghari<sup>1</sup>, Nawal El Ansari<sup>1</sup>

<sup>1</sup>Department of Endocrinology, Diabetology, Metabolic Diseases and Nutrition, Cadi Ayad University, Mohamed VI University Hospital Center, Marrakech, Morocco

DOI: <https://doi.org/10.36347/sjmcr.2024.v12i11.013>

Received: 30.09.2024 | Accepted: 06.11.2024 | Published: 11.11.2024

\*Corresponding author: Ahmed Boukhalifa

Department of Endocrinology, Diabetology, Metabolic Diseases and Nutrition, Cadi Ayad University, Mohamed VI University Hospital Center, Marrakech, Morocco

### Abstract

### Case Report

**Introduction:** Adrenocortical carcinoma (ACC) is a rare malignant tumor that develops in the layers of the adrenal cortex with an incidence of 0.5–2 per million per year. **Case report:** A 40-year-old female patient, admitted for left flank heaviness, evaluation was in favour of a suspicious left adrenal tumour, the non-functional character was retained after a negative secretory workup. The patient was operated on with a histological appearance of metastatic ACC. **Discussion and conclusion:** The prognosis for these tumors is poor, since at the time of diagnosis the majority of cases are already metastatic, especially when the tumour is non-functional. The management of ACC is complex, representing a real diagnostic and therapeutic challenge.

**Keywords:** Adrenocortical carcinoma, non functioning, metastases, prognosis, surgery, mitotane.

Copyright © 2024 The Author(s): This is an open-access article distributed under the terms of the Creative Commons Attribution 4.0 International License (CC BY-NC 4.0) which permits unrestricted use, distribution, and reproduction in any medium for non-commercial use provided the original author and source are credited.

## INTRODUCTION

ACC continues to represent the major fear of adrenal neoplasia, given its aggressive behaviour, frequent metastases and very high mortality rate. The majority of ACCs are sporadic, but the association with hereditary genetic syndromes is described in the literature, such as multiple endocrine neoplasia type 1 (MEN 1), Lynch syndrome, familial adenomatous polyposis (FAP) [1]. ACC is the 2nd most aggressive tumor after anaplastic thyroid carcinoma [2].

When functional, ACC presents with a picture of violent hypercorticism associated with signs of hyperandrogenism, with rapid onset, whereas in the absence of secretion, the tumor is often diagnosed at a late stage, often with a tumor syndrome and altered general condition. We present a case of non functioning ACC to illustrate clinical and therapeutic features.

## CASE REPORT

A 40-year-old female patient, operated on 5 years ago for a multinodular goiter, with familial history of breast cancer in cousin, admitted for left flank heaviness, aggravated a week ago by sudden left low back pain, unimproved by symptomatic treatment, with no history of renal colic, no bone pain, no transit disorders or vomiting, no flush syndrome. She reported

a weight loss of 3 kg during the last week, compared with anorexia.

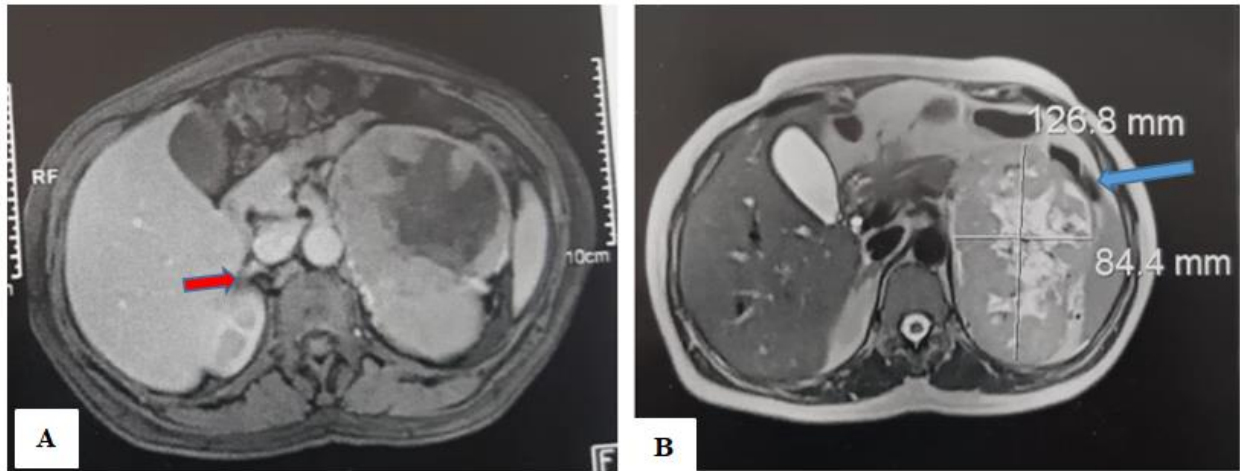
On examination a Blood Pressure (BP) of 100/60 mmHg, Heart Rate (HR) 75 bpm, Respiratory Rate (RR) 18 cpm, No facio-truncular obesity, no stretch marks, no hirsutism were noted.

The abdomen was soft with moderate sensibility over the left flank and a palpable mass occupying the left quadrants was felt.

**Biology:** Blood count: White blood cells at 8180/mm<sup>3</sup>, normocytic normochromic anemia with 10.8 g/dl of hemoglobin, creatinine levels at 5,88 mg/l, normal liver function, C-Reactive Protein initially at 198 mg/l controlled at 44 without infectious focus.

Abdominal ultrasound requested, noted a large mass in the left renal lodge. The workup was completed by an abdominal CT scan which revealed a well-limited left retroperitoneal supra-renal mass with polylobed hypodense contours, heterogeneously enhanced and delineating central areas of necrosis measuring approximately 13.8\*8.2\*14 cm. Inferiorly, it is in intimate contact with and displaces the homolateral kidney, which appears normal; anteriorly, it is in intimate contact with the tail of the pancreas, with loss of the separating fatty border. Externally and superiorly, it is in

contact with the spleen. Right adrenal gland was normal. This mass was confirmed by adrenal MRI (Figure 1).



**Figure 1: A): Right adrenal gland (red arrow). B): Left adrenal mass (blue arrow)**

The etiological investigation was completed by measuring 24-hour urinary methoxylates derivatives (UMD) and urinary free cortisol (UFC), both of which returned normal.

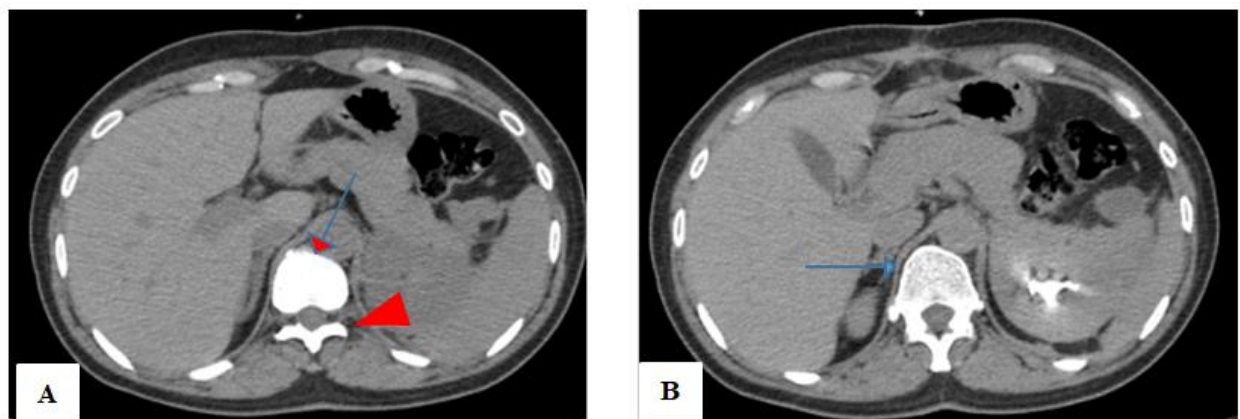
Given this clinico-biological and radiological finding, the patient underwent surgery. Intraoperative macroscopic examination revealed an infiltrating left adrenal mass with metastatic appearance. In addition to the left adrenalectomy, several biopsy samples were taken from the left suprarenal polar fat, the peritoneal layer, a thrombus of the left renal vein and an adenopathy of the left renal hilum. Macroscopic study revealed a left adrenal mass weighing approximately 780 g, measuring 16\*10.5\*8 cm, with a bumpy surface, surrounded by a capsule, this mass was heterogeneous in appearance, with significant haemorrhagic and necrotic changes.

Histological examination revealed for the mass, a tumor proliferation formed by a mixture of cells arranged in cords, nests or diffuse sheets. The cells were large, pleiomorphic, with abundant and predominantly eosinophilic cytoplasm, hyperchromic nuclei and

prominent eosinophilic nucleoli, the site of numerous abnormal mitoses with peri-tumoral fibro-vascular stroma and foci of capsular effraction and vascular emboli. The peritoneal layer was focally invaded by the tumor, with venous thrombus was tumoral.

Immunohistochemical study objectified, focal and partial nuclear expression of anti-claretinin antibody, focal and partial cytoplasmic expression of anti-Melan A, anti-Cytokeratin, anti-chromogranin A and anti-synaptophysin antibodies, intense nuclear expression of anti-Ki 67 antibody estimated at 15-20%, and absence of anti-PS100 antibody expression. The diagnosis of ACC was retained.

After discussion of the medical file in a multidisciplinary staff meeting, the patient was referred to oncology for radiotherapy. Mitotane was also indicated. Currently, the patient has received 4 sessions of radiotherapy. Controlled thoraco-abdomino-pelvic CT scan, noted the absence of a left adrenal lodge mass (Figure 2).



**Figure 2: A): Free left adrenal lodge (Red arrow). B) Normal right adrenal gland (Blue arrow)**

## DISCUSSION

ACC is a rare malignant tumor of the adrenal cortex, with an incidence of around 0.5 to 2 per million of the general population per year, and around 0.21 among children and adolescents. It is characterized by a poor prognosis, with a 5-year survival rate of less than 15% in the case of metastatic disease [3]. It is slightly female-dominated, with a female-to-male sex ratio of 1.5.

In order of frequency, ACC ranks 2nd with a percentage of 8 to 11%, after adenoma, which accounts for 54 to 80%, while pheochromocytoma accounts for 6-10% and metastases for 5-7%.

Secretory ACC usually presents with a hypersecretion syndrome (cortisol, androgenic, oestrogenic etc.) in almost 50-60% of cases, whereas non functioning ACC is often discovered on the occasion of a tumor or paraneoplastic syndrome (altered general condition, fever, etc.).

The first step in the diagnosis of an adrenal-like mass is to determine whether or not it is secretory, first clinically, by looking for hypercorticism, hypertension, hypokalemia [4] and Menard's triad, which leads to the initial elimination of a pheochromocytoma by measuring plasma or 24 hour urine metanephrines [4].

Our patient had no hypersecretion's signs, the diagnosis of the tumour was secondary to a tumour syndrome consisting of low back pain and left flank heaviness, and a paraneoplastic syndrome with weight loss and feverishness. Normal 24-hour urinary metanephrines and urinary free cortisol supported the non-functional nature of the mass in our patient.

Abdominal CT with adrenal slices and, if necessary, MRI, often enable to characterize the origin of the tumour mass, its relationship, its infiltrative nature, the presence of necrosis or intra-tumoral haemorrhage and/or lymph node or distant metastases. ACC is usually larger than 4 cm and has a spontaneous density of over 10 HU, calculation of absolute and relative Wash out gives a better idea of the suspicious nature of the lesion, especially if they are less than 60% and 40% respectively [5].

In our patient, the radiological characteristics of the mass were more in favour of a malignant tumour, given its size in excess of 10 cm, its heterogeneity, the presence of necrosis, and the loss of the separation line with the pancreas.

According to recommendations, in the event of suspicion of ACC, a PET scan 18F-FDG should be performed before surgery, to assess evidence of malignancy and tumour spread [4].

Due to lack of resources, our patient did not undergo a PET scan and was scheduled for surgery.

Histological study is the key step in the diagnostic process, and is carried out on the resection specimen for operable ACC, and on the biopsy sample in the case of inoperability [4].

Therapeutic indications vary according to the stage of the disease, and the main staging systems are UICC 8th edition and its equivalent ENSAT, enabling clinical TNM classification and prognostic evaluation (Table 1).

**Table 1: UICC 8th Edition stages**

<b>Stage 1</b>	Tumor located in the adrenal gland $\leq$ 5 cm: <b>(T1)</b>
<b>Stage 2</b>	Tumor located in the adrenal gland $>$ 5 cm: <b>(T2)</b>
<b>Stage 3</b>	Tumor infiltrating adipose tissue: <b>(T3)</b>
	Tumor infiltrating adjacent organs: <b>(T4)</b>
	Tumor infiltrating renal vein and/or vena cava <b>(T4)</b> regardless of lymph node status <b>(N0-N1)</b>
<b>Stage 4</b>	Tumor <b>(T1-T2)</b> with invasion of loco-regional lymph nodes <b>(N1)</b> .
	Tumor, whatever the size <b>(T1-T4)</b> , whatever the lymph node status <b>(N0-N1)</b> in the event of distant metastases <b>(M1)</b>

For stages 1,2 and some sub-groups of stage 3, complete surgery (R0) may be possible in around 95% of cases. The recommended approach is laparotomy [6] although some studies have reported the non-inferiority of laparoscopy in certain situations, especially when the tumor is less than 4 cm in size, and in the absence of local infiltration, but some series reported a negative impact on prognosis after laparoscopic surgery, given the aggressive behavior of ACCs and frequent locoregional invasion [7, 8].

Lymph node curage should be performed systematically, even in the absence of any signs of invasion, and should involve the peri-adrenal, peri-renal and renal hilum nodes [9].

Anatomopathological and immunohistochemical studies are the cornerstone of etiological diagnosis. It provides an initial tumor characterization: appearance, staining, weight, size, presence of capsule, necrosis or intratumoral hemorrhage, a macroscopic and microscopic description of the tumor and any biopsy samples taken intraoperatively. At the end of this

histological study, a diagnostic and prognostic score known as the WEISS score is established. It is based on 9 histological criteria, with a score of 1 point given to the

presence of each criterion. A Weiss score of 3 is sufficient to retain the diagnosis of ACC and predict a high metastatic potential (Table 2).

**Table 2: Weiss score**

	Yes	No
<b>Diffuse cellular architecture &gt; 1/3 of the tumor surface</b>	1	0
<b>Tumor necrosis</b>	1	0
<b>≤ 25% of clear cells</b>	1	0
<b>Führman nuclear grade III or IV</b>	1	0
<b>More than 5 mitoses / 50 fields</b>	1	0
<b>Atypical mitosis</b>	1	0
<b>Capsular invasion</b>	1	0
<b>Venous invasion</b>	1	0
<b>sinusoidal invasion</b>	1	0

The second stage of the histological study is immunohistochemistry, with the main antibodies used in ACC being: anti-claretinin, anti-Melan A, anti-inhibin. Other antibodies used in the discussion of other diagnoses are: anti-Chromogranin A, anti-PS100 for medullo-adrenal tumors such as pheochromocytoma or extrasensory tumors such as paraganglioma, and anti-cytokeratin for adrenocortical neoplasia. Evaluation of anti-Ki 67 would give an idea of the power of tumour proliferation [10].

A Weiss score > 6 and/or Ki 67 > or equal 20 % predict a high risk of relapse and poor overall survival.

In our patient, immunohistochemical study revealed positivity of anti-claretinin, anti-Melan A, anti-cytokeratin, Weiss score at 6 which led to the diagnosis of ACC with very high relapse and metastasis rates.

Several studies have reported that 5-year survival varies between 40% and 80% depending on the stage of ACC, neoadjuvant treatment is often indicated [3]. The 2 main adjuvant treatments are Mitotane (1,1-(o,p'-Dichlorodiphenyl)-2,2-dichloroethane (o,p'-DDD), and radiotherapy.

Mitotane acts through mitochondrial inhibition of steroidogenesis enzymes and stimulation of oxidative stress in the endoplasmic reticulum, with a proapoptotic effect that inhibits tumor growth. When indicated, Mitotane should be started as soon as possible after surgery [11], with mitotane monitoring (target: 14 to 20 mg/l), for greater efficacy and fewer side effects which are mainly represented by digestive disorders, asthenia, neuropsychic manifestations such as ataxia and depression, hepatotoxicity with risk of cytolysis or even hepatocellular failure. In addition, contralateral adrenal insufficiency may develop, sometimes necessitating high doses of hormone replacement therapy [3].

Radiotherapy after surgery, whether or not combined with Mitotane, is still under discussion, depending on the stage of the disease and the status of

the initial resection, with particular indication for stages 3 or more, R1 resection or more, or in the case of ACC with a high risk of recurrence [12].

In case of advanced or metastatic disease, inoperable tumor, Mitotane is indicated as 1st-line treatment with an overall response rate of 20.5% and a median OS of 18.5 months [13]. On the other hand, chemotherapy is indicated in combination with Mitotane as 1st-line treatment. The protocols recognized for their efficacy, despite their sometimes severe side effects, are as follows: Mitotane + etoposide, doxorubicin and cisplatin (EDP) or Mitotane + streptozocin, with reported response rates of 23.2% and 9.2% respectively [14].

Other therapies are currently being evaluated and tested in clinical trials, such as IGF1 receptor inhibitors (as linsitinib) and tyrosine kinase inhibitors (as cabozantinib) [15, 16].

In our patient, after surgical resection, Mitotane with radiotherapy was indicated in view of the stage of the disease, the high risk of locoregional recurrence and the presence of peritoneal metastases.

## CONCLUSION

ACC is a malignant adrenal tumor known for its aggressiveness and dismal prognosis, with a very high mortality rate. Early diagnosis and initiation of well-coded treatment with multidisciplinary consultation (endocrinologist, urologist, oncologist and radiotherapist) slightly improves survival, especially in localized forms where surgical resection combined with neoadjuvant treatment is of prime importance.

**Declaration of Interest:** The authors declare that they have no direct or indirect interest (financial or in kind) in any private, industrial or commercial organization related to the presented subject.

## REFERENCES

1. de Ponthaud, C., Roy, M., & Gaujoux, S. (2024). Adrenocortical carcinoma: what you at least should know. *British Journal of Surgery*, *111*(8). <https://doi.org/10.1093/bjs/znae177>.
2. Subashini, R., Anandi, M. S., & Vinoth Kumar, M. S. (2023). Challenges in diagnosis and management of a giant non-functioning adrenocortical carcinoma: A case report. *International Journal of Case Reports in Surgery*, *5*(1), 31-34. DOI:<https://doi.org/10.22271/27081494.2023.v5.i1.a.77>
3. Libé, R., & Huillard, O. (2023). Adrenocortical carcinoma: Diagnosis, prognostic classification and treatment of localized and advanced disease. *Cancer Treatment and Research Communications*, *37*, 100759. [doi.org/10.1016/j.ctarc.2023.100759](https://doi.org/10.1016/j.ctarc.2023.100759)
4. Fassnacht, M., Dekkers, O. M., Else, T., Baudin, E., Berruti, A., De Krijger, R. R., ... & Terzolo, M. (2018). European Society of Endocrinology Clinical Practice Guidelines on the management of adrenocortical carcinoma in adults, in collaboration with the European Network for the Study of Adrenal Tumors. *European journal of endocrinology*, *179*(4), G1-G46. <https://doi.org/10.1530/EJE-18-0608>.
5. Thomas, A. J., Habra, M. A., Bhosale, P. R., Qayyum, A. A., Ahmed, K., Vicens, R., & Elsayes, K. M. (2018). Interobserver agreement in distinguishing large adrenal adenomas and adrenocortical carcinomas on computed tomography. *Abdominal Radiology*, *43*, 3101-3108. <https://doi.org/10.1007/s00261-018-1603-3>.
6. Yip, L., Duh, Q. Y., Wachtel, H., Jimenez, C., Sturgeon, C., Lee, C., ... & Perrier, N. D. (2022). American Association of Endocrine Surgeons guidelines for adrenalectomy: executive summary. *JAMA surgery*, *157*(10), 870-877. <https://doi.org/10.1001/jamasurg.2022.3544>.
7. Delozier, O. M., Stiles, Z. E., Deschner, B. W., Drake, J. A., Deneve, J. L., Glazer, E. S., ... & Dickson, P. V. (2021). Implications of conversion during attempted minimally invasive adrenalectomy for adrenocortical carcinoma. *Annals of surgical oncology*, *28*, 492-501. <https://doi.org/10.1245/s10434-020-08824-9>.
8. Hue, J. J., Bingmer, K., Zhao, H., Ammori, J. B., Wilhelm, S. M., Towe, C. W., & Rothermel, L. D. (2021). Reassessing the impact of tumor size on operative approach in adrenocortical carcinoma. *Journal of Surgical Oncology*, *123*(5), 1238-1245. <https://doi.org/10.1002/jso.26418>.
9. Panjwani, S., Moore, M. D., Gray, K. D., Finnerty, B. M., Beninato, T., Brunaud, L., ... & Zarnegar, R. (2017). The impact of nodal dissection on staging in adrenocortical carcinoma. *Annals of surgical oncology*, *24*, 3617-3623. <https://doi.org/10.1245/s10434-017-6064-3>.
10. Fassnacht, M., Assie, G., Baudin, E., Eisenhofer, G., De La Fouchardiere, C., Haak, H. R., ... & Berruti, A. (2020). Adrenocortical carcinomas and malignant pheochromocytomas: ESMO–EURACAN Clinical Practice Guidelines for diagnosis, treatment and follow-up. *Annals of oncology*, *31*(11), 1476-1490.
11. Kiseljak-Vassiliades, K., Bancos, I., Hamrahian, A., Habra, M. A., Vaidya, A., Levine, A. C., & Else, T. (2020). American Association of Clinical Endocrinology Disease state clinical review on the evaluation and management of adrenocortical carcinoma in an adult: a practical approach. *Endocrine Practice*, *26*(11), 1366-1383. <https://doi.org/10.4158/DSCR-2020-0567>.
12. Fassnacht, M., Hahner, S., Polat, B., Koschker, A. C., Kenn, W., Flentje, M., & Allolio, B. (2006). Efficacy of adjuvant radiotherapy of the tumor bed on local recurrence of adrenocortical carcinoma. *The Journal of Clinical Endocrinology & Metabolism*, *91*(11), 4501-4504. <https://doi.org/10.1210/jc.2006-1007>.
13. Megerle, F., Herrmann, W., Schloetelburg, W., Ronchi, C. L., Pulzer, A., Quinkler, M., ... & German ACC Study Group. (2018). Mitotane monotherapy in patients with advanced adrenocortical carcinoma. *The Journal of Clinical Endocrinology & Metabolism*, *103*(4), 1686-1695. <https://doi.org/10.1210/jc.2017-02591>.
14. Fassnacht, M., Terzolo, M., Allolio, B., Baudin, E., Haak, H., Berruti, A., ... & Skogseid, B. (2012). Combination chemotherapy in advanced adrenocortical carcinoma. *New England Journal of Medicine*, *366*(23), 2189-2197. <https://doi.org/10.1056/NEJMoa1200966>.
15. Lerario, A. M., Worden, F. P., Ramm, C. A., Hasseltine, E. A., Stadler, W. M., Else, T., ... & Hammer, G. D. (2014). The combination of insulin-like growth factor receptor 1 (IGF1R) antibody cixutumumab and mitotane as a first-line therapy for patients with recurrent/metastatic adrenocortical carcinoma: a multi-institutional NCI-sponsored trial. *Hormones and Cancer*, *5*, 232-239. <https://doi.org/10.1007/s12672-014-0182-1>.
16. Kroiss, M., Megerle, F., Kurlbaum, M., Zimmermann, S., Wendler, J., Jimenez, C., ... & Fassnacht, M. (2020). Objective response and prolonged disease control of advanced adrenocortical carcinoma with cabozantinib. *The Journal of Clinical Endocrinology & Metabolism*, *105*(5), 1461-1468. <https://doi.org/10.1210/clinem/dgz318>.