

An Unusual Etiology of a Garré's Periostitis: A Case Report and Review of the Literature

Aya Mtiri^{1,2*}, Ghada bouslama^{1,2}, Nour-sayda Ben Messouad^{1,2}, Souha Ben Youssef^{1,2}

¹Department of Oral Surgery, University Hospital Farhat Hached Sousse, University of Sousse, Tunisia

²Research Laboratory: LR 12SP10: Functional and Aesthetic Rehabilitation of Maxillary, University of Sousse, Tunisia

DOI: <https://doi.org/10.36347/sjmcr.2024.v12i11.016>

| Received: 26.09.2024 | Accepted: 30.10.2024 | Published: 14.11.2024

*Corresponding author: Aya Mtiri

Department of Oral Surgery, University Hospital Farhat Hached Sousse, University of Sousse, Tunisia

Abstract

Case Report

Garré's osteomyelitis represents a periosteal reaction to the presence of low grade infection or other irritants which can be odontogenic or nonodontogenic. This is a case report of an odontogenic periostitis in a 7-year-old boy due to pericoronitis in relation to permanent mandibular left first molar. It was successfully treated by gingival curettage and antibiotic therapy.

Keywords: Periosteal reaction, chronic osteomyelitis, case report, periostitis of Garré.

Copyright © 2024 The Author(s): This is an open-access article distributed under the terms of the Creative Commons Attribution 4.0 International License (CC BY-NC 4.0) which permits unrestricted use, distribution, and reproduction in any medium for non-commercial use provided the original author and source are credited.

INTRODUCTION

Garré's osteomyelitis is a type of chronic non-suppurative osteomyelitis that primarily affects children and adolescents because they have greater osteogenic potential and the periosteum is loosely attached to the bone surface [1]. This Chronic osteomyelitis with proliferative periostitis is characterised by the formation of new bone with periosteal reaction [2] and caused by inert stimulation from low-virulence infection. Mandible is more affected than the maxilla [3], especially in the premolar-molar area [4].

The aims of this article were to present the radiographic features and the clinical cause of mandibular Garré's osteomyelitis and to discuss the possible pathogenesis of this condition.

CASE REPORT

A 7-year-old boy was referred to the dental department of the university hospital FARHAT HACHED Tunisia, by a private dental practitioner. The chief complaint was a left mandible swelling, trismus and intermittent pain during mastication. The swelling had been present for at least 2 months. At that time, the patient was given a 7 day course of antibiotics by the referring dentist, he had no further discomfort however, the swelling did not disappear.

Extra-oral examination showed facial asymmetry (Figure 1A). The swelling was non-tender,

bony hard and painless to pressure with no cervical lymphadenopathy.

Intra-oral examination revealed buccal swelling extending from the left second primary molar to the angle of the left mandibular. The mucosa overlying the swelling was normal in color and texture (Figure 1B). All teeth reacted positively to vitality test, there were no dental decay, and no intra-oral draining sinus was found.

The patient had a normal mixed dentition for a boy of this age group.

The panoramic radiograph showed non-specific findings with no evidence of periapical infection. However, computed tomography (CT) scan examination revealed well defined hypodense bone lesion in the left mandibular body, local cortical bone was discontinuous over there, and a 8,7 mm periosteal reaction involving in regart to the buccal area of the tooth 36, appearing as a cortical layering or redundancy, often termed 'onion skinning' or 'onion peel' like aspect (Figure 2).

A clinical diagnosis of Garré's osteomyelitis was made with two possible etiologic factors: buccal bifurcation cyst or chronic pericoronitis of the first permanent left molar.

A full thickness buccal flap was elevated and bone curettage performed with respect to 36. All the

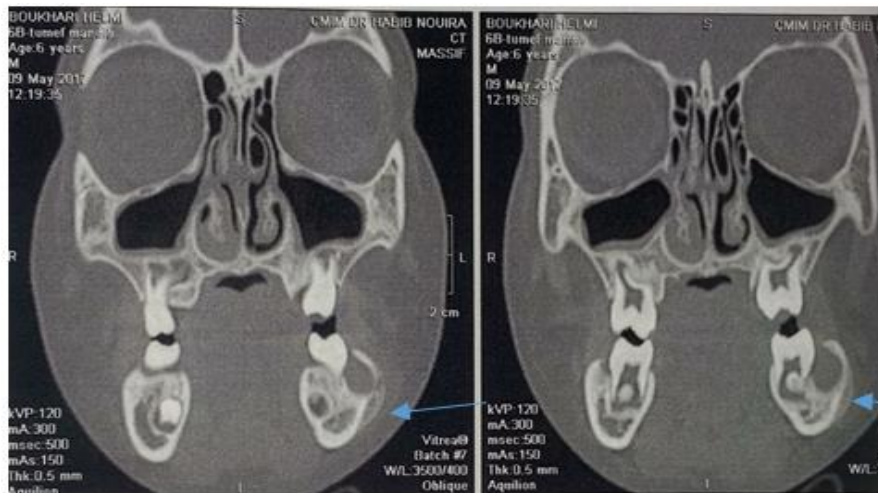
granulation tissue found was removed and the flap was repositioned and sutured (Figure 3).

Histopathological examination of the removed bony tissue revealed new bone formation with

periosteal reactivity as well as findings of chronic inflammation, which confirmed the diagnosis of Garre's osteomyelitis as a result of chronic pericoronitis of the tooth 36 (Figure 4).

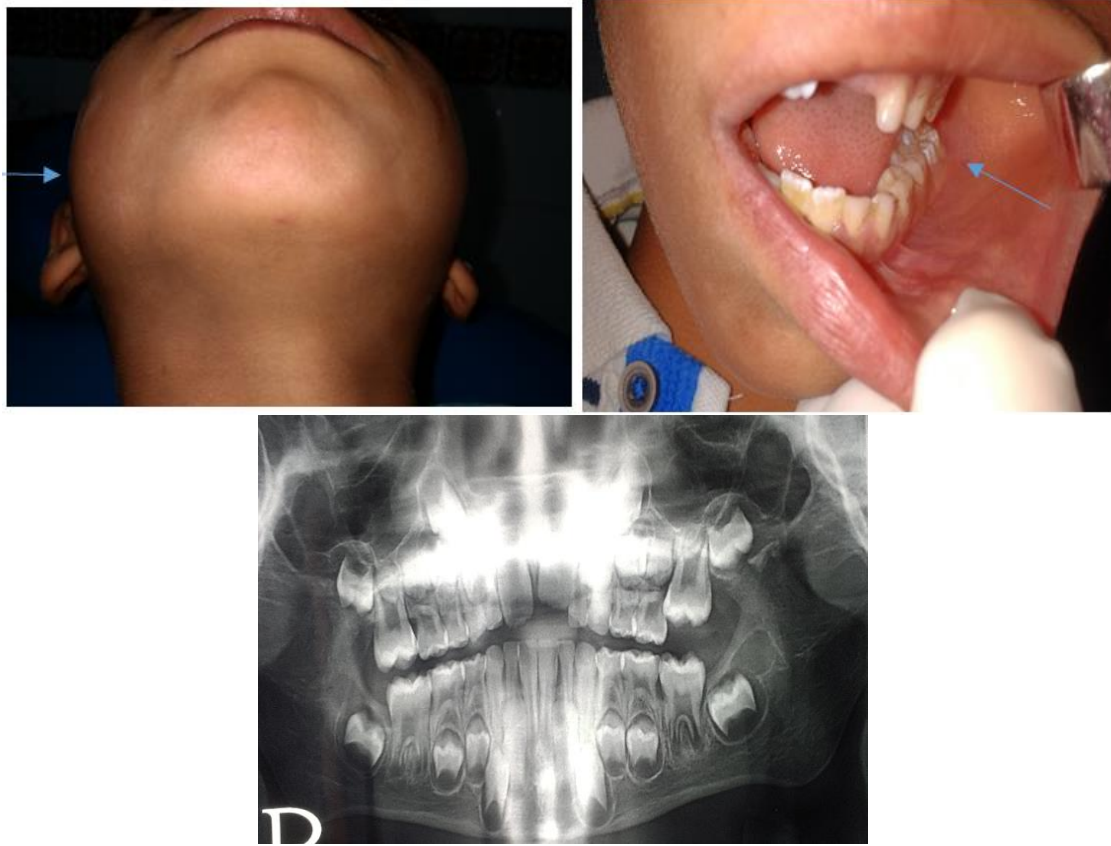

Figure 1: Preoperative examination of patient: A: Extraoral examination showing facial asymmetry; B: Intraoral view showing a normal mucosa in color and texture; C: Panoramic radiographic view



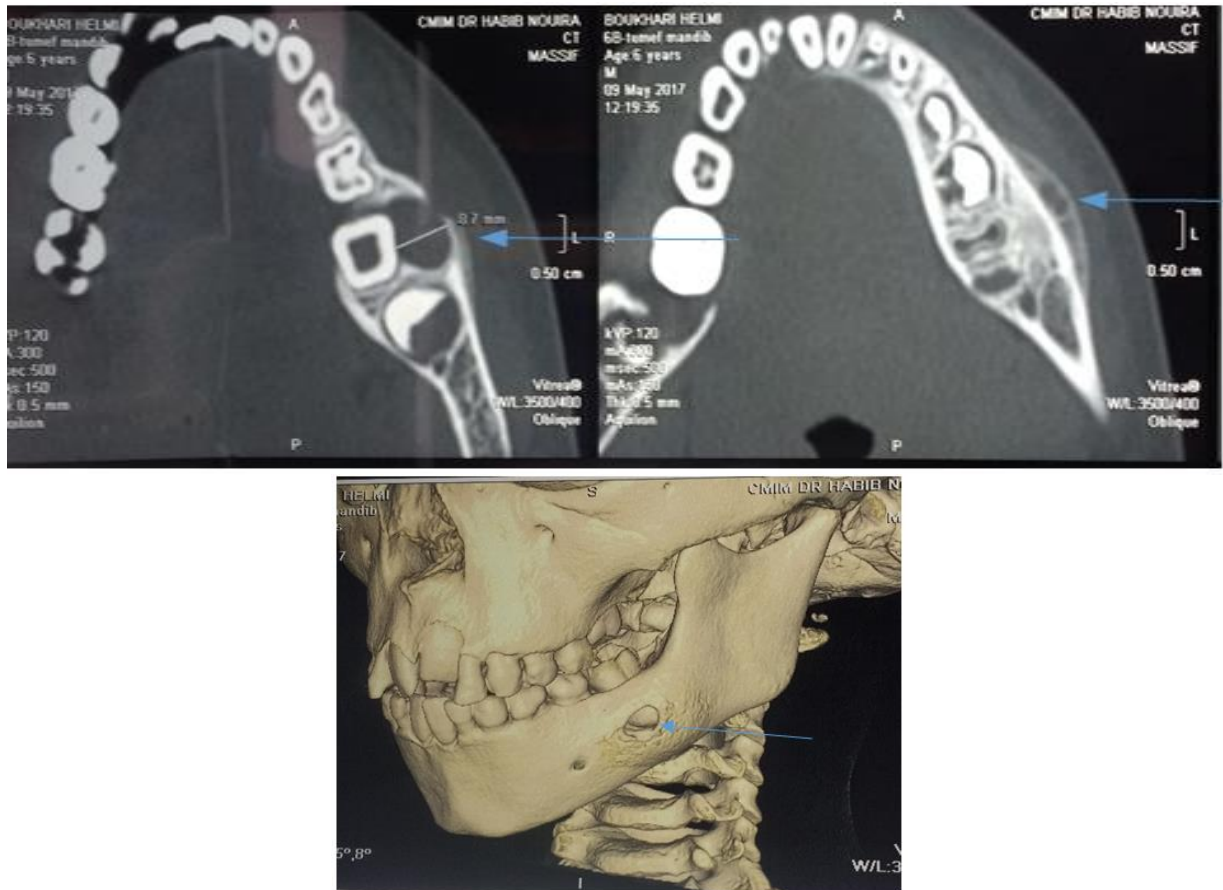


Figure 2: CTscan sections showing osteolytic bone lesion in the left mandibular body associated to the periosteal reaction. A: Coronal section image; B: Cross section image; C: three-dimensional reconstruction image

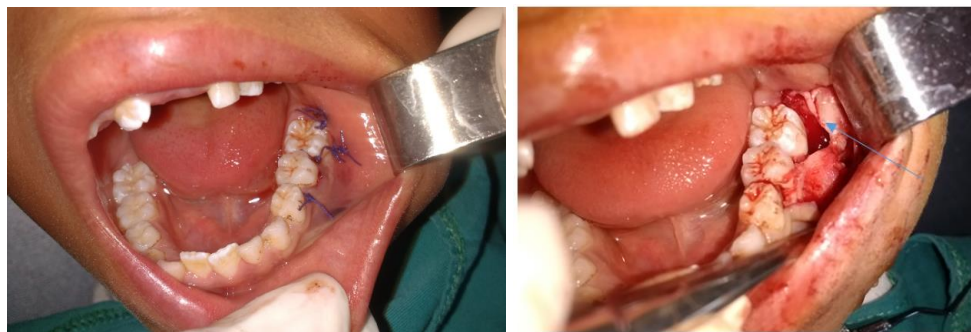

Figure 3: A) Bone curettage; B) Flap Reposition and Suturing

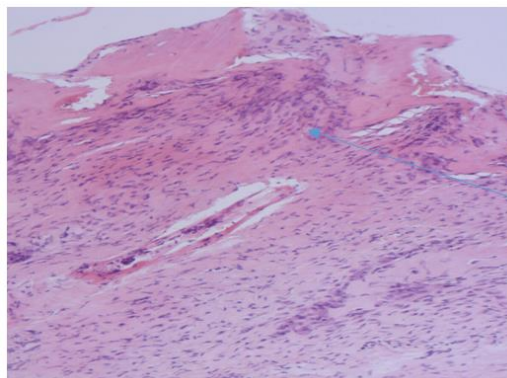


Figure 4: Histopathological tissue showing trabeculae of bone and osteoid tissue with abundant osteoblasts bordering many trabeculae, fibroblasts, fibrocytes as well as chronic inflammatory infiltrate predominantly lymphocytes and plasma cells

DISCUSSION

Garré's osteomyelitis is a distinctive type of chronic osteomyelitis with proliferative periostitis [1] characterized by depositing successive layers of new bone, leading to the "onion-peel" appearance seen on radiographic examination [5].

Radiographs are usually used for diagnosis and have a high diagnostic value. Computed tomography scan may also be used to detect typical alterations of the bone and periosteal reactions as well as soft tissue involvement [6, 7].

In many reported cases, etiologic factors were odontogenic including dental decay, which is the most common etiology of jaw infection, unerupted teeth, untreated fractures and rarely localized periodontal infection due to pericoronitis in a newly erupted first permanent molar just like our case [4-6], although nonodontogenic factors may contribute to develop this pathology.

In this case CT scan was mandatory to diagnosis because no periapical pathology was neither found clinically nor seen in the panoramic radiograph, which may disguise the diagnosis. In some cases occlusal radiograph may be enough without exposing patient to high-dose radiation [1].

However, these neoperiostoses are not limited to proliferative periostitis of Garre and may occur in a variety of other pathosis, such as: congenital syphilis, infantile cortical hyperostosis, avitaminosis C, fluorosis, hypertrophic osteoarthropathy, Ewing sarcoma, and osteogenic sarcoma. In addition, bone swelling, seen at younger ages, could be associated to other pathologic conditions such as fibrous dysplasia [2]. Yet, fibrous dysplasia is distinguished from Garre's osteomyelitis due to the "ground glass appearance" as well as the thinning seen in the cortex.

Histopathological examination shows new reactive bone or osteoid tissue subperiosteally, with osteoblasts surrounding many of the trabeculae, oriented perpendicular to the cortex. Presence of fibrous tissue between the trabeculae, as well as lymphocytes and plasma cells just like our case [6, 7].

In the present case, clinical, radiographic evidences and pathological findings were in accordance with diagnostic features of osteomyelitis of Garre.

The therapeutic approach involves antibiotic administration if needed: in case of fever, infection, trismus, lymphadenopathy, cellulitis... and especially removal of the infectious etiology such as: extraction of the infected tooth, endodontic treatment, and granulation tissue curettage [1]....

After a six to eight month period as seen in the literature, the bone contour is expected to return progressively to normal once the causal factor has been identified and removed with no risk of re-occurrence [5]. Without treatment, the lesion may progress to cellulitis, alveolitis [9, 10] or extensive osteitis.

The evolution into le Garre's osteomyelitis could be prevented in many cases if the dentist had thought about eliminating the causal factor instead of just instituting some antibiotic therapy [6, 11].

CONCLUSION

Osteoperiostitis are a serious yet rare diseases. resulting of stimulating bone formation. However, it's development depends on the balance between the resistance of the host and the virulence of the infectious agent and, while the periosteal osteoblastic activity must also be high.

Early diagnosis of disease remains essential to promptly initiate appropriate treatment, that prevents complications which can be sometimes, very difficult to manage.

REFERENCES

1. Zand, V., Lotfi, M., & Vosoughhosseini, S. (2008). Proliferative periostitis: a case report. *Journal of endodontics*, 34(4), 481-483.
2. Akgül, H. M., Çağlayan, F., Günen Yılmaz, S., & Derindağ, G. (2018). Garre's osteomyelitis of the mandible caused by infected tooth. *Case Reports in Dentistry*, 2018(1), 1409539.
3. Shah, K. M., Karagir, A., & Adaki, S. (2013). Chronic non-suppurative osteomyelitis with proliferative periostitis or Garre's osteomyelitis. *Case Reports*, 2013, bcr2013009859.
4. Gao, P., Wang, X., Xuan, M., Ma, X., Chang, Z., & Xiong, S. (2015). Garré's osteomyelitis with bilateral mandible: a case report. *Hua xi kou Qiang yi xue za zhi= Huaxi Kouqiang Yixue Zazhi= West China Journal of Stomatology*, 33(4), 436-438.
5. Smith, S. N., & Farman, A. G. (1977). Osteomyelitis with proliferative periostitis (Garre's osteomyelitis): report of a case affecting the mandible. *Oral Surgery, Oral Medicine, Oral Pathology*, 43(2), 315-318.
6. Gumber, P., Sharma, A., Sharma, K., Gupta, S., Bhardwaj, B., & Jakhar, K. K. (2016). Garre's sclerosing osteomyelitis-A case report. *Journal of Advanced Medical and Dental Sciences Research*, 4(2), 78-83.
7. Schwartz, S., & Pham, H. (1981). Garre's osteomyelitis: a case report. *Pediatr Dent*, 3(3), 283-286.
8. Oulis, C., Berdousis, E., Vadiakas, G., & Goumenos, G. (2000). Garre's osteomyelitis of an unusual origin in a 8-year-old child. A case

- report. *International Journal of Paediatric Dentistry*, 10(3), 240-244.
9. Bah, A., Camara, S., Vaysse, F., & Bailleul-Forestier, I. (2016). Prise en charge de l'Ostéopériostite chronique dentaire chez l'enfant: A propos d'un cas. *African Journal of Dentistry & Implantology*, (7), 53-60.
 10. Liu, D., Zhang, J., Li, T., Li, C., Liu, X., Zheng, J., ... & Wang, X. (2019). Chronic osteomyelitis with proliferative periostitis of the mandibular body: report of a case and review of the literature. *The Annals of The Royal College of Surgeons of England*, 101(5), 328-332.
 11. Suma, R., Vinay, C., Shashikanth, M. C., & Reddy, V. S. (2007). Garre's sclerosing osteomyelitis. *Journal of Indian Society of Pedodontics and Preventive Dentistry*, 25(Supplement), S30-S33.