

## Post-Traumatic Terson's Syndrome, A Case Report

Ouahib Hacht<sup>1\*</sup>, Fatima-Zahra Mabrouki<sup>1</sup>, Asmae Maadane<sup>1</sup>, Rachid Sekhsoukh<sup>1</sup>

<sup>1</sup>Department of Ophthalmology, Mohammed VI University Hospital of Oujda, Oujda, Morocco

DOI: <https://doi.org/10.36347/sjmcr.2024.v12i11.033>

| Received: 19.10.2024 | Accepted: 25.11.2024 | Published: 26.11.2024

\*Corresponding author: Ouahib Hacht

Department of Ophthalmology, Mohammed VI University Hospital of Oujda, Oujda, Morocco

### Abstract

### Case Report

In 1881, Litten first described an intraretinal hemorrhage associated with subarachnoid hemorrhage in the German literature. However, Terson's description of vitreous hemorrhage following subarachnoid hemorrhage in 1900 is now associated with this syndrome. Terson's syndrome has been more broadly applied to intraocular hemorrhages associated with other causes of rapidly increased intracranial pressure beyond subarachnoid hemorrhages. We report the case of a 54 years old mal patient admitted for head trauma. The patient experienced a sudden loss of visual acuity without pain in the both eyes, 4 hours later. CT-Scan performed in the emergency showed a bifrontal extradural hematoma and a tentorial subarachnoid hemorrhage. Ocular ultrasound confirmed vitreous hemorrhage.

**Keywords:** Terson's Syndrome (TS), intracranial hemorrhage, intraocular hemorrhage.

**Copyright © 2024 The Author(s):** This is an open-access article distributed under the terms of the Creative Commons Attribution 4.0 International License (CC BY-NC 4.0) which permits unrestricted use, distribution, and reproduction in any medium for non-commercial use provided the original author and source are credited.

## INTRODUCTION

Terson's syndrome is the association of a subarachnoid hemorrhage and a vitreous hemorrhage. Was described by French ophthalmologist Albert Terson in 1900.

Currently, this syndrome now corresponds to the association of any type of intracranial hemorrhage accompanied by intraocular hemorrhage, whether post-aneurysm rupture or post-head trauma.

## MATERIAL AND METHODS

We report the case of a 54-year-old patient, with no pathological history, admitted for head trauma. He reported a rapidly progressive loss of visual acuity in both eyes without associated pain or redness 4 hours later.

## RESULTS

The patient was admitted for head trauma at the right parieto-occipital impact point. Brain scan performed in the emergency room showed a bifrontal extradural hematoma and a tentorial subarachnoid hemorrhage.

The patient experienced a sudden loss a visual acuity, without pain in both eyes, 4 hours later. Ophthalmological examination:

VA at 1/10, Normal anterior segment, without hyphema. Fundus: Stage 2 vitreous hemorrhage.

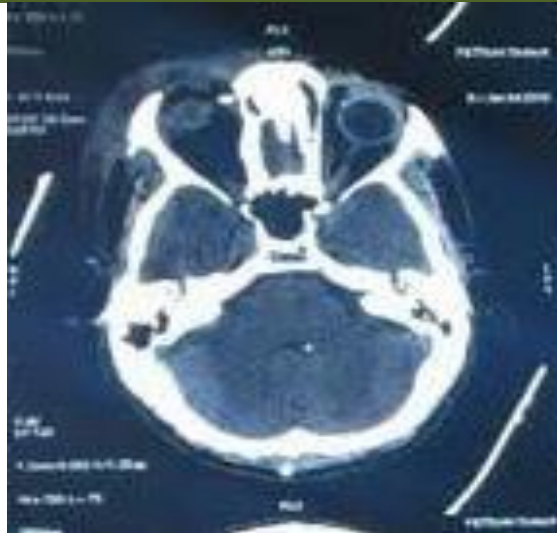
Ocular ultrasound confirmed vitreous hemorrhage without retinal or choroidal detachment. The patient had initially neurosurgical surgery with good post-operative outcomes.

On the ophthalmological level, the treatment consisted of strict rest, good rehydration, with weekly monitoring.

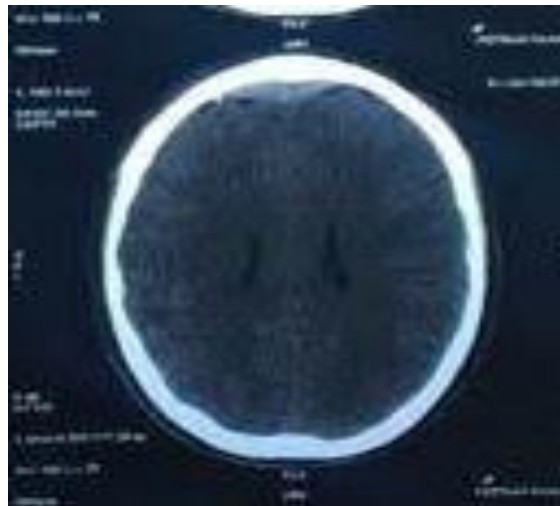
The evolution was marked by the spontaneous resorption of the hemorrhage after one month with recovery of visual acuity to 9/10, without correction.

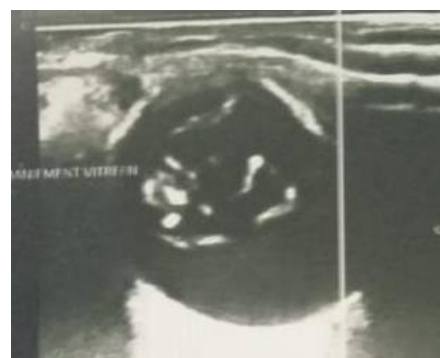

Figure 1: Ultrasound image of vitreous hemorrhage



**Figure 2: Bifrontal extradural hematoma**



**Figure 3: Tentorial subarachnoid hemorrhage**

## DISCUSSION

The symptoms reported by TS patients can vary widely, depending on the degree and location of the hemorrhage as well as the individual's neurological status. Many patients, especially those who are most neurologically compromised, may not be able to perceive or communicate ocular complaints. In such cases, prompt diagnosis depends on the primary physician's first being aware of the possibility of Terson syndrome. Patients who are able to describe their symptoms typically report an acute decrease in vision in 1 or both eyes in the setting of a recent severe headache or head trauma.

Given the notable incidence of TS in patients with intracranial hemorrhage, or traumatic brain injury especially in patients with a loss of consciousness or low initial Glasgow Coma Scale, screening for TS is important once the patient is medically stable.

Funduscopy is the gold standard for detecting and diagnosing TS. Hemorrhages involving multiple

intraocular layers may be seen; they can manifest as a "double ring" sign, in which blood is present below the internal limiting membrane and posterior hyaloid. Patients may also have a loss of the red reflex. TS has been linked with development of macular holes,

It can be challenging to identify this pathology by funduscopy if the examination is obscured by vitreous hemorrhage; in such cases, other modalities, such as B-scan ultrasonography, should be considered to help in the diagnosis.

When medically stable, patients with intracerebral and subarachnoid hemorrhages should receive a prompt funduscopic exam to evaluate for TS.

B-scan ultrasonography or CT head scan can be used as to screen for TS. Early vitrectomy should be considered in patients with severe vision loss or bilateral hemorrhages and in young children at risk for amblyopia.

The presence of TS is associated with a worse neurological prognosis and higher risk of mortality.

## CONCLUSION

Terson's syndrome is a rare complication of cerebro-meningeal hemorrhages, whether post-aneurysm rupture or post-head trauma.

A rapid ophthalmological evaluation is necessary in the context of cerebral hemorrhage. Their prognosis remains better in the absence of other complications and early management.

**Conflict of Interest:** No conflict of interest was declared by the authors.

## REFERENCE

- McCarron, M. O., Alberts, M. J., & McCarron, P. (2004). A systematic review of Terson's syndrome: frequency and prognosis after subarachnoid haemorrhage. *Journal of Neurology, Neurosurgery & Psychiatry*, 75(3), 491-493.
- Czorlich, P., Skevas, C., Knospe, V., Vettorazzi, E., Richard, G., Wagenfeld, L., ... & Regelsberger, J. (2015). Terson syndrome in subarachnoid hemorrhage, intracerebral hemorrhage, and traumatic brain injury. *Neurosurgical review*, 38(1), 129-136.
- Czorlich, P., Skevas, C., Knospe, V., Vettorazzi, E., Westphal, M., & Regelsberger, J. (2016). Terson's syndrome—Pathophysiologic considerations of an underestimated concomitant disease in aneurysmal subarachnoid hemorrhage. *Journal of Clinical Neuroscience*, 33, 182-186.
- Bäuerle, J., Gross, N. J., Egger, K., Neubauer, J., Niesen, W. D., Buttler, K. J., ... & Reinhard, M. (2016). Terson's Syndrome: diagnostic comparison of ocular sonography and CT. *Journal of Neuroimaging*, 26(2), 247-252.
- Gnanaraj, L., Tyagi, A. K., Cottrell, D. G., Fetherston, T. J., Richardson, J., Stannard, K. P., & Inglesby, D. V. (2000). Referral delay and ocular surgical outcome in Terson syndrome. *Retina*, 20(4), 374-377.
- Manschot, W. A. (1954). Subarachnoid hemorrhage: intraocular symptoms and their pathogenesis. *American Journal of Ophthalmology*, 38(4), 501-505.
- Weingeist, T. A., Goldman, E. J., Folk, J. C., Packer, A. J., & Ossoinig, K. C. (1986). Terson's syndrome: clinicopathologic correlations. *Ophthalmology*, 93(11), 1435-1442.
- Gress, D. R., Wintermark, M., & Gean, A. D. (2013). A case of Terson syndrome and its mechanism of bleeding. *Journal of Neuroradiology*, 40(4), 312-314.
- Ko, F., & Knox, D. L. (2010). The ocular pathology of Terson's syndrome. *Ophthalmology*, 117(7), 1423-1429.
- Schultz, P. N., Sobol, W. M., & Weingeist, T. A. (1991). Long-term visual outcome in Terson syndrome. *Ophthalmology*, 98(12), 1814-1819.
- Garweg, J. G., & Koerner, F. (2009). Outcome indicators for vitrectomy in Terson syndrome. *Acta ophthalmologica*, 87(2), 222-226.